

ACKNOWLEDGEMENT

Words cannot fathom the depth of gratitude that my heart is filled with to be associated with this prestigious institution.

“A teacher affects eternity; his influence never stops”. Had it not been pain taking attention to details, vigilance, guidance and constant support of my Guide Dr N. G. Toshniwal, M.D.S. Prof and Head of the Dept. of Orthodontics & Dentofacial Orthopaedics, Rural Dental College, Loni, my thesis would not have seen today’s glory.

I am deeply indebted to him for his encouragement and support that showed me the path towards perfection.

I would like to express my deep gratitude to Dr. Abhijit Misal, M.D.S. (Orthodontics), Professor, Dept of Orthodontics, for his constant guidance and invaluable suggestions in making of this thesis

I am also thankful to Dr. Gajanan Shanbhag (M.D.S), and Dr. Abhay Chaudhari (M.D.S), and Dr. Shubhangi Amit (M.D.S), Lecturers, Dept. of Orthodontics for their constant support, encouragement given to me.

I express my thanks to Dr. J. J. Doshi, Principal, Rural Dental College, Loni, for permitting me to carry out this work in the institution.

I express my thanks to Dr. Raju Anarthe, Dr Daimi Lecturers Dept of Orthodontics for their valuable support.

I am also grateful to Mr Tony Zakhem (Rocky Mountain Orthodontics Denmark) without whom it would not have been possible for me to give this treatise the shape it has today.

I am wholeheartedly thankful to my loving husband Dr. Vyankatesh Pharande, for his unfailing support, encouragement and inspiration. I am also grateful to Dr. Mr.Sanjay Anarse and Mrs. Yogita Anarse for giving me a homely environment during my stay in Loni and supporting me morally.

I am also thankful to my parents who supported me in this venture morally, physically, financially and always showered their blessings without which I could not have dreamt of completing this project.

Lastly and above all, like my own life, the genesis if this manuscript has been possible only because of the blessings and inspirations of my family, my friends and my collages.

"This impossible task is made possible by God, 'a great power of faith' who showered his all blessings throughout my carrier and academic life."

Shilpa...

INDEX

Sr. No.	Topic	Page No.
1.	Introduction	1
2.	Memorium	3
3.	Accomplishment of Dr. Ricketts	5
	1950 – 1970	
4.	Variation of TMJ by cephalometric laminography	7
5.	Inter dependence of nasal & oral capsule	26
6.	Esthetics, Environment & law of lip relation	56
	1970 – 1980	
7.	Arcial growth of mandible	65
8.	Growth prediction	81
9.	Four-step method to distinguish Orthodontic changes from natural growth	97
10.	Computerized Cephalometrics	109
11.	Perspectives in clinical application of Cephalometrics	121
12.	Bioprogressive Therapy	145
13.	Utility Arch	189
14.	Quad Helix Appliance	203
15.	Dr. Ricketts on early treatment	209
16.	Headgear	216
17.	Management Umbrella & VTO	226
18.	Ricketts Cephalometric Analysis	233
	1980 – 1990	
19.	The Golden divider	242
20.	Biologic Significant of Divine Proportion and Fibonacci series and Golden divider	248
21.	Radiographic evaluation of transverse discrepancies	265

	1990 – 2003	
22.	Truth in Orthodontic Beliefs	268
23.	Bioprogressive concept by Dr. Ricketts (JIOS)	281
24.	Annexure I – Awards received by Dr. Ricketts	284
25.	Annexure II – Honours received by Dr. Ricketts	285
26.	Annexure III – Lectures, Course conducted by Dr. Ricketts	287
27.	Bibliography	288

INTRODUCTION

Blessed are those who bring a wonderful smile, for they shall be called orthodontist. To perceive an attractive smile is no longer a luxury but rather a necessity in lifestyle and the changing orthodontic scenario says it all.

With the advent of 21st century, more and more people are becoming aware and conscious of their never so perfect face. Orthodontia is that branch which is concerned with facial perfection.

The term 'Orthodontia' was apparently used first by French man 'Le Foulon' in 1839. Many golden hands contributed in building the field of orthodontics, those are Dr Edward H Angle, Dr Calvin Case, Dr Martin Dewey, Dr Tweed, Dr Andrew, and Dr Begg and so on.

In this Galaxy of names, the name of Dr. R. M. Ricketts makes a special place for its contribution in the field of orthodontia.

He had started his contributions to the orthodontic specialty since 1950 when his attention was drawn to the clinical application of cephalometrics. During the 1950's Broadbent and Brodie advocated the use of Cephalometrics for longitudinal studies rather than clinical diagnosis but Ricketts was not satisfied with this. On going to California in the early 1950's Ricketts was challenged by his colleagues for a direct answer to the clinical application of Cephalometrics which can be obtained from dental casts and oriented photographs. With the realization Ricketts then published two papers in 1960 which gave information about the use of cephalometrics in the clinical practice using records of 1000 cases treated by him and for the

first time, he studied the possibility of growth forecasting. Then he was engaged in a new series of computer investigations in orthodontics in 1965.

He was simultaneously involved with the evolution of new concept of esthetics, the law of lip relations and the importance of chin point, B point and lower incisors in planning orthodontic treatment and stability after treatment. He introduced the new concept of occlusion, Fibonacci numbers from Hindu-Arabic numerical system and has applied it to the knowledge of growth biology and facial balance.

His contributions to Orthodontics are significant, and this is just an attempt to enumerate his major contributions to the field of Orthodontics.

MEMORIUM

Dr. Robert Murray Rickett's (1920 – 2003)

Born in rural Indiana, Robert Murray Rickett's rose to a world renowned position as one of the world's most prominent researchers, educators, authors and lecturers on life sciences, surgery and orthodontics.

Ricketts wanted to become a dentist when he was a sophomore in highschool, but at first lacked the confidence in himself to become a dentist. As he was from a poor family, he did not receive the encouragement to seek higher education. After a highschool education, for a year he worked as a labour in steel mill and on an assembly line in a radio factory for a year, and this job gave him a very great and strong motivation for higher education.

Ricketts completed his graduation course in dentistry in year 1945 from University of Indiana. Then he became a Diplomate of the American Board of Orthodontics. He taught at Loma Linda University, University of Illinois, UCLA, USC and dozens of University around the world. He was the first to prescribe nutritional supplementations in the 1950s in his orthodontic & orthopedic practice. Later, he developed a nutritional community. This knowledge ultimately led him into the field of microbiology and chemistry for environmental awareness and to the development of Organics.

Dr. Ricketts was a member of 17 professional societies and received numerous international honors and awards.

When Dr. Ricketts passed away on June 17, 2003 we all lost a great teacher, friend and an inspiration. He was with his children when he died

and he was happy and active as he had always been. Dr. Ricketts had significant abdominal pain and was diagnosed as ischemic bowel necrosis of small intestine.

It was Dr. Ricketts request that his death should be celebrated by joy. He expressed to family that he desired a black tie affair, with joyful times in his honor.

Dr. Ricketts contributions to orthodontics are well known and have impacted thousands of colleagues, students and patients around the world. Ricketts Bioprogressive Philosophy and Diagnostic concepts has helped to set the standards and the new goals of orthodontics treatment. Apart from Orthodontics Dr. Ricketts was also a role model for a happy, productive and fulfilling life style

As a teacher, Dr. Ricketts emphasized experience, awariness and discipline. He was quick to replace old knowledge with new, yet stood strong on unchanging principles. He had made learning interesting and inspiring, conveying knowledge with meeting and vitality. He believed that the orthodontist of the future will be the one who gains perfection and stability of results with the fewest appliances.

Dr. Ricketts significantly influenced many lives. He once said in a lecture, “You wont forget me; I will live forever in your minds.” That he will.



HONG KONG



INDONESIA



INDONESIA



INDONESIA



INDONESIA



KOREA



JAPAN



MEXICO



JAPAN



JAPAN



KOREA



MIDDLE EAST



MIDDLE EAST 2




MISSOURI



PHILADELPHIA




SINGAPORE



SPAIN



SPAIN



ILLINOIS



SYRIA



SYRIA



YONEYAMA



CALIFORNIA



CHINA



HAWAII

ACCOMPLISHMENTS OF DR. RICKETTS

- Developed the first straight wire bracket 018 slot in 1970.
- Developed the first cephalometric analysis that allowed clinicians to compare their patients with norms based on age, sex and race (Rickett's analysis)
- Developed the first cephalometric diagnostic system to project treatment plus growth in treatment planning (VTO).
- Using growth studies of Bjork, Mass, Scott, Petrovic and others developed a computer generated method for projecting growth to maturity with mandibular archival growth method.
- Pioneered the use of composite tracings to better understand normal growth patterns in various facial types.
- Developed computer driven cephalometric diagnosis.
- Developed 5 arch forms used to individualize treatment outcomes (Pentamorphine arches).
- Developed "Root ratings" based upon the works of Miura and Lee to quantify the forces necessary to move teeth in any plane of space.
- Challenged the profession to learn and understand anatomy growth and development and their application in treatment decisions and mechanics.
- Emphasized the facial orthopedic potential and challenged our profession to "treat faces not teeth", promoted the use of cervical headgear only for orthopedic correction.
- Developed with Ruel Bench and Carl Gugino new appliances systems used by orthodontists world wide, including quad helix, utility arches, sectionalization and orthopedic correction with cervical headgears.

- Developed with Carl Gugino and Ruel Bench the Bioprogressive Philosophy, a biological approach to diagnosis and treatment.
- Stimulated orthodontic thinking about the possibilities of treatment with his publications of the “doctrine of limitations” in 1973.
- Recognized and used facial proportions to treat dental and skeletal problems (the Devine Proportion).

VARIATIONS OF THE TEMPOROMANDIBULAR JOINT AS REVEALED BY CEPHALOMETRIC LAMINAGRAPHY

Introduction

This study of Dr Ricketts is concerned with the dynamic aspects of the human temporomandibular articulation and particularly with morphologic and functional variations. Investigations in this field have been hampered by the shortcomings of available research methods and only the recent advances in the techniques of cephalometry and laminagraphy made this study possible to Dr Ricketts.

The purpose of the study was threefold.

- 1) It was desired to test cephalometric laminagraphy as a method of investigation.
- 2) Second, it was desired to study the range of normal variation in morphology and function and to attempt to correlate certain functions of the denture with the behavior of the temporomandibular joint.
- 3) Third, it was desired to investigate possible differences between patients with Class II malocclusions and a control group of adequate size.

Method Used In This Study By Dr Ricketts

The Head Holder and Its Application. Fig 1. — The head holder used in the present study was designed:

1. To make true lateral exposures of either the right or the left temporomandibular joint.
2. To make possible the taking of successive x-ray photographs susceptible to accurate measurements so that quantitative as well as

qualitative data could be gathered.

3. To expose a field large enough to include joint, teeth, and certain orienting planes of reference.

Because the laminagraph operates in a vertical position, the patient is required to lie prone with the head turned to the side.

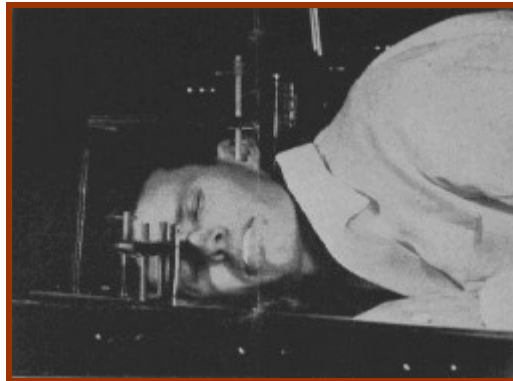

Fig. 1

Fig. 1. — *Patient in head holding apparatus. Note ear posts and assemblage supporting the nosepiece. Also note incisal plaster core registering rest position which had previously been taken with patient seated upright.*

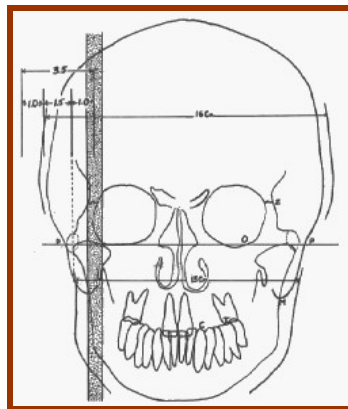


Fig. 2

Fig. 2. — *Frontal view of skull with stippled area showing the depth of cut and area projected on laminagraphic film. Note measurements of skull used in determining proper cut for individual patient.*

The soft tissue was of almost the same thickness for the cranium as for the lateral side of the condyles. It was further determined that the condyles measured from 1.5 cm. to 2 cm. in width. An accepted distance of 1 cm. from the lateral side of the condyle was taken to bisect each condyle.

If the difference in the biparietal and the bicondylar width was 3 cm. the distance for one side would be 1.5 cm. The added 1 cm. which was taken to bisect the condyle thus gave a measurement of 2.5 cm. from the widest part of the head to the center of the condyle. Since the holder platform was approximately 1 cm. in thickness, the distance from the table top to the center of the condyle would be 3.5 cm. (Fig. 2). As a rule, a cut at 3.5 cm. proved adequate. However, when extremes in obesity or head form were encountered, the cut was varied according to the measurements.

Interpretation and Tracing of Films.— In laminagraphy it must constantly be borne in mind that all clearly visible structures lie in the same plane and only such clearly defined structures should be traced. As per Ricketts in the sagittal plane through the center of the condyle the entire ramus including the coronoid process, the outer rim of the orbit, the zygomatic ridge, the ear canal, glenoid fossa, petrotympanic fissure, postglenoid process, articular eminence and mastoid air cells, and the zygomaticofrontal suture provide excellent checks on the accuracy of successive films and can be used as points for superpositioning. The sectional plane runs slightly to the lateral of the buccal teeth, but these structures are rendered with sufficient clarity to make them easily discernible.

Points, Planes, and Angles Selected for Study. — All x-ray films were traced on fine tracing paper (Traceofilm) and certain anatomical points inscribed. In addition, certain lines and planes were constructed for the purpose of making possible the analysis of movements and relationships. Linear measurements with correctional scales as described by Adams (1940) were made to the nearest 0.5 mm. Angular measurements were read to the nearest 1.0° with a standard protractor.

Fig. 3 represents a basic tracing of structures and points. These were located as follows:

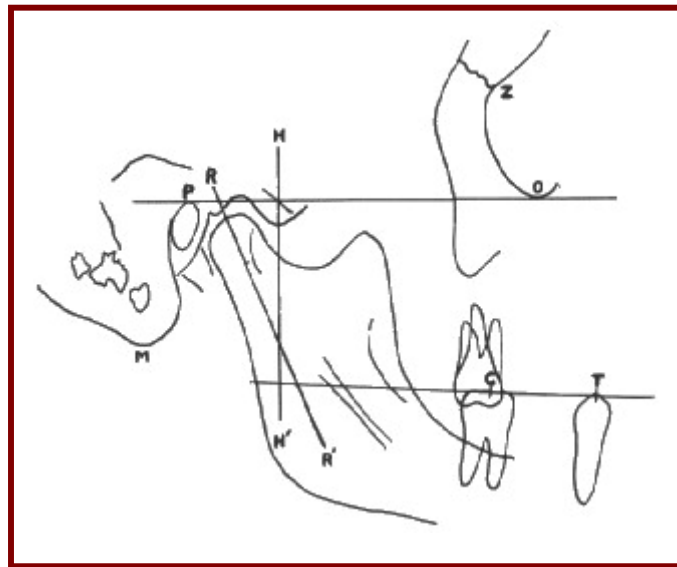


Fig. 3

Fig. 3. — *Tracing of laminagram showing points and planes of reference. P, porion; O, orbital, Z, zygomatic frontal suture; M, mastoid process; C, centrobuccal cusp of lower first molar; T, tip of lower canine; PO, Frankfort plane; HH', perpendicular through PO at height of eminence; CT, occlusal plane; RR', plane parallel to long axis of neck of condyle.*

Fig. 4 indicates how the details noted were employed in the first step of the study, viz., the analysis of the closing movement of the mandible from its resting position to full occlusion.

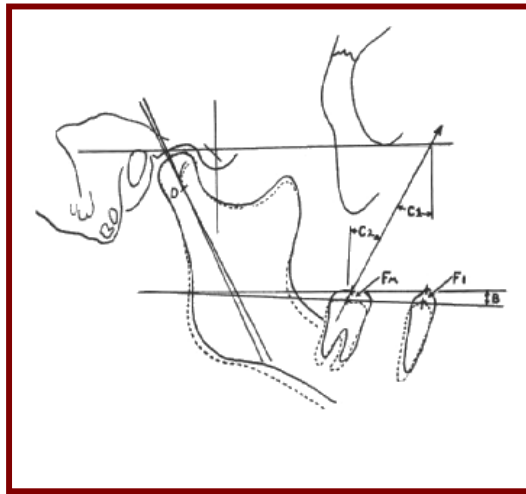


Fig. 4

Fig. 4. — *Illustration of method of analysis of movement of the mandible from rest position to closure. Dotted line indicates tracing at rest and solid line denotes occlusion. Point at D is center of rotation of condyle: C1, path of closure related to Frankfort; C2, path of closure related to occlusal plane at rest, Fm, Fi, interocclusal (freeway) space at molar and canine respectively; B, angle of divergence of occlusal plane at rest.*

The lines representing the Frankfort horizontal planes were superimposed and registered at the intersection of HH'. Additional identifying letters are to be seen on this figure, to wit:

D, The center of rotation or least movement of the lines RR'.

Fm, Interocclusal or posterior freeway space at the first permanent molar.

Fi, Interocclusal or anterior freeway space at the canine area.

B, Change of the occlusal plane from rest to closure (read in degrees).

C1, Angle formed by a line connecting the two C points with a perpendicular to PO.

C2, Angle formed by the same line with a perpendicular to the occlusal plane with the mandible at rest.

Material Used In This Study by Dr. Ricketts

The original sample taken for this study consisted of fifty individuals, and both the right and left temporomandibular joints were studied. The sample represented a reasonable cross section of the population and consisted of 31 individuals possessing normal occlusion or mild malocclusions, 13 Class I (Angle) malocclusions, 4 mild Class II (Angle) subdivision malocclusions, and 2 mild Class III (Angle) subdivision malocclusions. Laminagraphs were made of both the right and left joints with the jaws at rest and in full occlusion. Of these, 55 joints were taken with the mouth wide open in order to study the range and variation of this movement.

Second group consisting of individuals exhibiting unquestionable Class II relation of the molar teeth was studied. Of this sample, 24 were of the Division 1 type (protruding incisors) and 19 were of the Division 2 type (retruding incisors). The remaining 7 cases could not be classified as to division. Both joints of each patient were laminagraphed at physiologic rest position and with the teeth in occlusion, and 48 joints were taken to study the range and variation of the wide open position.

FINDINGS

A. Size of the Condyle. — A comparison of the relative size of the condyle to the glenoid fossa was made (Fig. 5, D) by dividing the entire sample into five categories, viz.: very small, small, average, large, and very large.

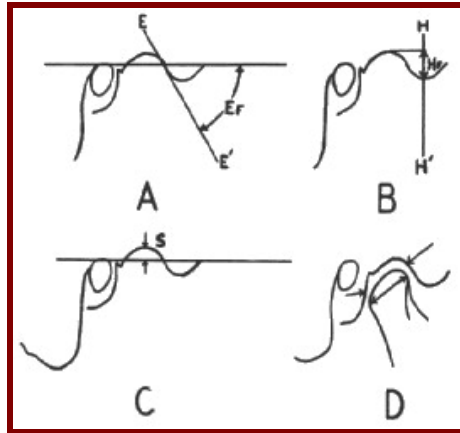


Fig. 5.— A, Method of measuring angle of the eminence Ef; B, method of measuring height of eminence Hf; C, method of measuring fossa relation to Frankfort plane at S; D represents criteria for appraisal of size of condyle in comparison to fossa.

Of the 200 joints, 3 condyles appeared to be very small in relation to the size of the fossa (Fig. 6, A) and 45 fell in the small group. Exactly one-half of the condyles were estimated to be of average size (Fig. 6, B); of the remaining cases, 45 were determined to be large and 7 were considered very large (Fig. 6, C).

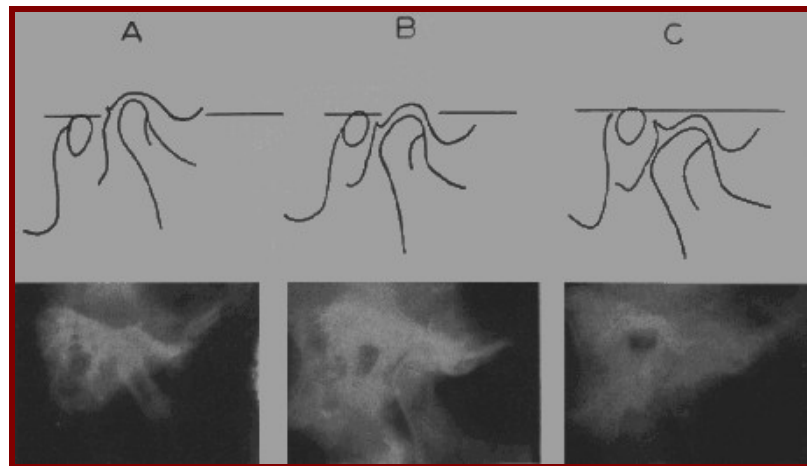

Fig. 6

Fig. 6. — A illustrates tracing, and laminagraph of very small condyle compared to the fossa. B represents an average-sized condyle related to the fossa. C, Case of very large condyle in comparison to the fossa. Note the postglenoid tubercle almost superior to the condyle. Note also difference in position of fossa relative to Frankfort.

B. Movement of The Mandibular Condyle.

The point D was found to be very stable in the control group. Fifty of the one hundred joints failed to move enough to permit measurement (Figs. 4 and 7, A).

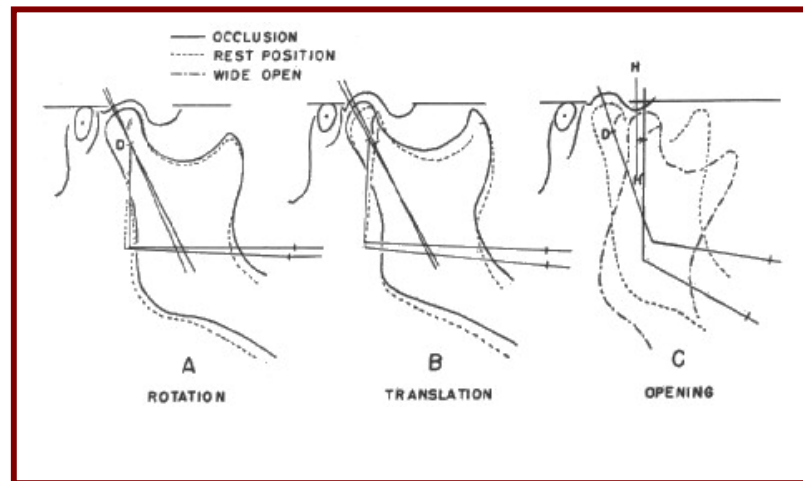


Fig. 7

Fig. 7. — *Method employed in analysis of movement of condyle. A, No movement of point D, with rotation of mandible from rest to closure. Note molar path upward and forward. B, Movement of point D with translation of condyle and mandible. Note molar path upward and backward. C, Movement of point D anterior to plane HH' in opening.*

Thirty-six showed a movement of less than 1 mm. and fourteen, less than 2 mm. (Fig. 8).

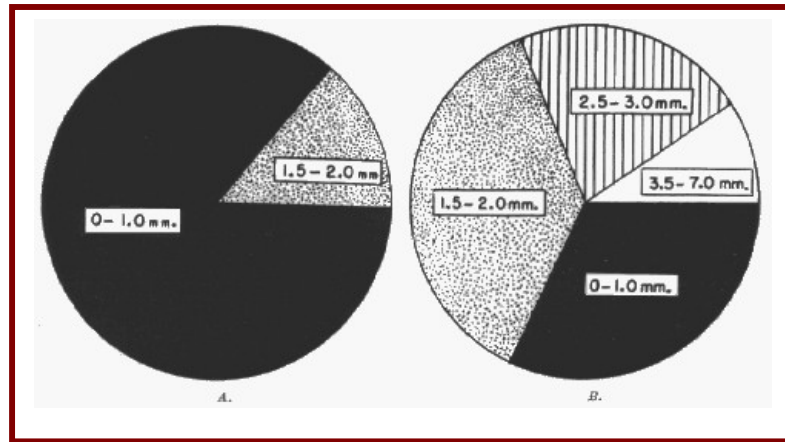


Fig. 8

Fig. 8. — *Pie diagrams of movement of the condyle in the control and Class II groups. The black area corresponds to Fig. 7A. The stippled area represents behavior as seen in Fig. 7B. The lined and plain sections indicate cases in which the condyle was forward at rest position as illustrated in Fig. 15. A, Normal range of movement of condyle from rest to closure in 100 cases; B, range of movement of condyle from rest to closure in 100 cases with Class II malocclusion.*

These slight movements were in different directions, the greatest number being in upward and posterior directions (Fig. 7, B).

In the Class II group, the findings were quite different. Here the point was found to move over a significantly greater range

Relations of the Condyle

Anteroposterior Relation of Mandibular Condyle to Eminentia Articularis.

The method employed to measure this relationship is indicated in Fig. 10 where Gr indicates the point on the eminence that is closest to the condyle when the mandible is at rest.

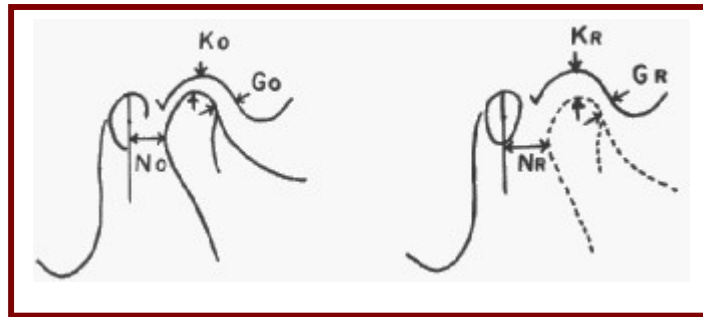


Fig. 10

Fig. 10. Method employed in measuring position of the condyle in relation to the eminence, the fossa, and the external auditory meatus. Gr, Distance from condyle to eminence at rest; Go, same measurement in occlusion; Kr, distance from condyle to top of fossa at rest; Ko, same measurement in occlusion, Nr, measurement from line through center of EAM to posterior surface of condyle at rest; No, same measurement in occlusion.)

The same points were transferred to the subsequent picture and the distance between them measured to determine the change, if any, that occurs when the teeth are occluded (Go).

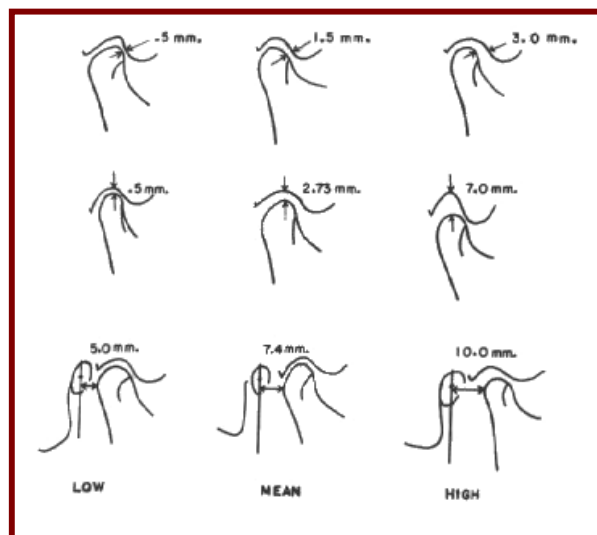


Fig. 11

Fig 11. Positions of condyle at rest in the normal group. Top figures represent range of variation in Gr measurements. Middle figures represent range of Kr measurement. Lower figures represent range of Nr measurement.)

In the Class II group the means were 1.51 mm. for the rest position and 1.61 mm. with the teeth in occlusion. The difference between the two groups in the matter of this relationship was not thought to be significant.

When the Class II group was subjected to the same measurements, certain significant differences were noted. At rest, the mean of this group was 3.78 mm. \pm 1.07 mm. When the teeth were in occlusion, the difference between the two samples tended to disappear. Indeed, the values were almost identical. The mean distance of the Class II sample was found to be 2.48 mm. \pm 0.77.

Relation of Mandibular condyle to External Auditory Meatus.

In the control group, this measurement gave a mean of 7.4 ± 1.16 mm. at rest with a range from 5 mm. to 10 mm. (Fig. 11). The distribution was that of a normal curve. In occlusion, the mean was 7.2 mm. and the distribution similar to that found at rest. This was to be expected on the basis of the behavior of the D point.

When the same measurements were made on the Class II group, the differences were highly significant. At rest, the mean measurement was found to be 8.54 mm. \pm 1.86, with a range of 4.5 mm. to 14 mm.

Morphologic Variation of Fossa

Angle of the Articular Eminence. This is a measure of what is commonly called in dental terminology the "Condyle Path." The method employed to measure it for the purposes of the present study is illustrated in Fig. 5, A

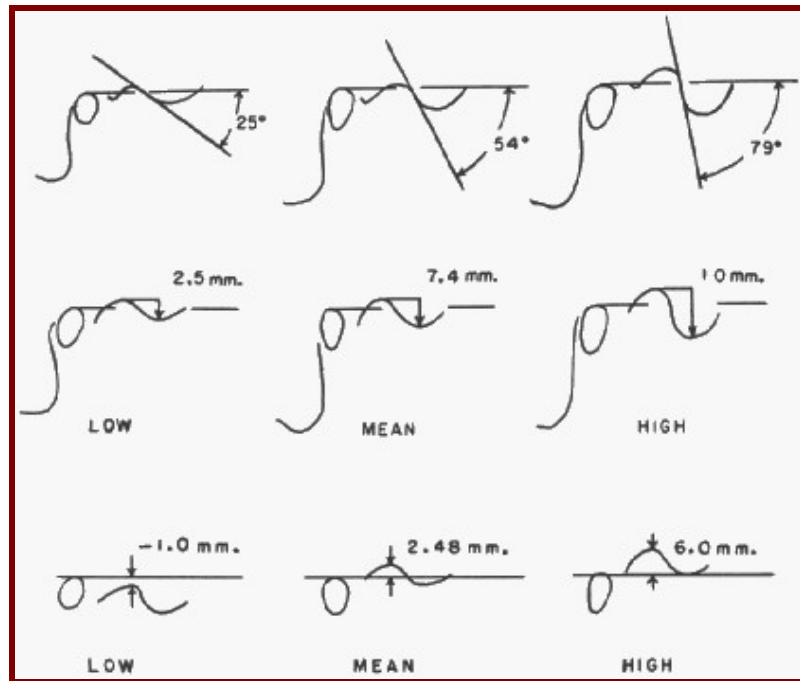


Fig. 12

Fig. 12. — *Range of variation in (1) angle of the eminence (top figures), (2) height of eminence (middle figures), and (3) relation of top of fossa to Frankfort plane (bottom figures).*

Height of Eminentia Articularis. — This measure was made in the manner indicated in Fig. 5, B. A tangent to the floor of the glenoid fossa and parallel to the PO line was drawn to intersect a perpendicular to PO and passing through the height of the eminence.

This measurement showed no significant difference to exist between the two groups studied. In the control group the mean was 6.3 ± 1.3 mm. and in the Class II group the mean was 6.2 mm. The ranges were likewise similar, that of the control being from 4.0 mm. to 11.5 mm. and the Class II being 4.5 mm. to 9 mm. (Fig. 12).

Relation of Roof of Glenoid Fossa to PO Line. — This measurement was taken to test the validity of the claim that the relation

between the fossa and the external auditory meatus is a very constant one. It was studied by measuring the distance between the PO plane and the most superior point in the fossa. A value of 0 was given where the two coincided, minus values indicated that the roof of the fossa was below the PO line, plus values indicated that it was above (Fig. 5, C).

In the control group there was an almost even distribution from – 1.0 mm. to 6.0 mm. with a mean at 2.5 (Fig. 12). In the Class II group the distribution ranged quite evenly from – 3 mm. With a mean of 1.4 mm. Seventy-six per cent of the cases fell in the 0 to 3 mm. range.

Relations of the Teeth

Variation of Cant of Occlusal Plane. — The method used in determining this relation is seen in Fig. 3. Parallel PO and CT planes indicate 0° value as plus values are demonstrated when point T drops below C. Minus values are seen in cases in which the canine is superior to the molar. The mean value of the control was 7.5° with a range of – 6° to 16°.

The range of 2° to 13° embraced two-thirds of the sample. The curve skewed slightly toward the higher values.

The Class II group showed a slightly longer range at – 9° to +19° but the mean was 2° lower.

Size of Space between Upper and lower Teeth with Mandible at Rest (Freeway Space).

The values at the canine (T) were higher but the range was similarly small. The mean was 2.75 ± 1.15 mm. Eighty per cent measured 3 mm. or less, and 93 per cent, less than 4 mm.

When the same measurements were made on the Class II sample, significant differences were found. The mean value of the measurement taken at the molar was 3.56 ± 1.54 mm.

Movement of the Teeth

Direction of Path of Closure. — To study the direction in which the mandible moved from rest to closure, i.e., upward and forward, straight upward, or up ward and backward, the C points on the molar at its two positions were connected and the line projected upward (Fig. 4)

The mean value of the control group was $+15^\circ$ (forward and upward) and there was an even distribution on both sides of this value. The total range was from 40° to $+55^\circ$ with two-thirds of the cases falling between -6° and $+34^\circ$ (Fig. 13). Ninety-one of the cases fell between -10° and $+50^\circ$ but there were 7 that yielded values below -25° .

When the same measurements were taken from the Class II sample, very significant differences were noted. The mean was -3.15° (backward and upward) with two-thirds of the cases falling between -27° and $+20^\circ$.

The total range of this sample was from -57° to $+42^\circ$.

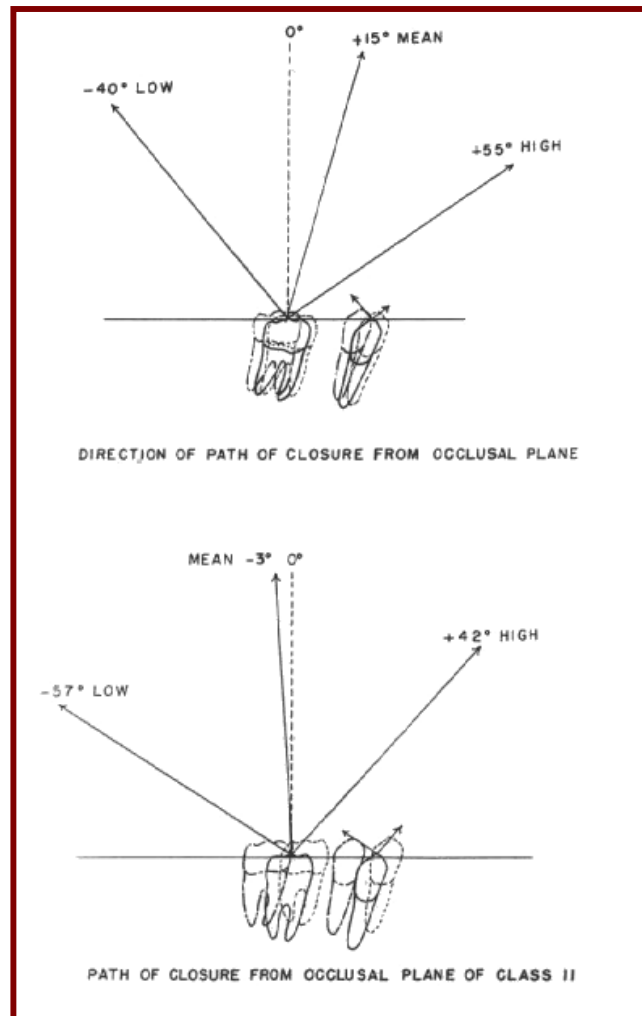


Fig. 13

Fig. 13. — *Range of variation in direction of movement of the lower first molar from rest position to occlusion, analyzed from the occlusal plane. Top, control: bottom, Class II.*

Nature of Movement of Occlusal Plane from Resting Position to Occlusion. — It is quite generally accepted that the movement of the mandible from rest position to occlusion is purely rotary in an upward and forward direction. To check this, the angle B (Fig. 4) was constructed to projecting the CT lines backward in the two positions until they intersected each other. A closure of the angle indicated rotation. The control sample

yielded a mean of 1.6° with ninety rotating from 1° to 3° . Five cases rotated from 3° to 4.5° and five showed no rotation, i.e., the movement was of a translatory nature.

In the Class II sample the mean was $2.75^{\circ} \pm 1.6^{\circ}$, and nine cases showed translatory movement. Thirty-two cases rotated more than 3° . These differences were thought to be significant.

Comparison of Certain Aspects of Division Of Class II

Movement of Condyle.—

Division 1 showed more movement of point D with a mean of 2.1 and a range of 0 to 7 mm. than the Division 2 cases with a mean of 1.8 and a range of 0 to 4 mm.

Interocclusal Space. —

The interocclusal (freeway) space was slightly different in the three groups. The first group again showed tendencies toward the control. The Division 1 was narrower at a mean of 3.3 mm. and a range of 0.5 mm. to 7 mm. than the Division 2, with a mean of 4 mm. and a range of 2 mm. to 7.5 mm. The vertical space taken at canine (anterior freeway) showed the same tendencies although naturally larger.

Rotation of the Occlusal Plane. —

The rotation of the occlusal plane became progressively wider as the space became larger. The mean of the unclassified Class II was 2° with a range from 0° to 5° ; the Division 1 was 2.5° with a range from 0° to 6° ; the Division 2 was 3° with a range from 0° to 7° .

Path of Closure. —

Contrary to common belief, the path of closure of Division 1 cases was found to be more distal than the Division 2 cases. The mean direction of the Division 1 from the occlusal plane was -8° with a range of $+37^{\circ}$ to -57° . The Division 2 cases showed a mean of $+1.4^{\circ}$ and a range of $+37^{\circ}$ to -40° .

Conclusion

There was found to be considerable variation in the relation between size of fossa and size of condyle. Some condyles appeared quite small for the fossae with which they were associated and others appeared too large for the cavity.

In Class I (Angle) occlusions the point of least movement from rest position to occlusion was found to be situated in the neck of the condyloid process. This was called the D point in this study and it revealed very slight movement in any direction. In Class II malocclusions, however, the point did move, predominantly in an upward and backward direction.

The condyle in both Class I and Class II cases tended to move forward of the tip of the eminentia articularis during wide opening movements. The main difference between the two classes lay in the range, that of the Class II being slightly larger.

The relation of the condyle to the slope of the articular eminence was quite constant. It showed less variation than any of the other measurements and this was true in both Class I and Class II.

The relation of the top of the condyle to the roof of the fossa exhibited considerable range, particularly at the rest position. In the Class II group

there was a strong tendency for the condyle to lie low in the fossa at this position. The values, when taken with the teeth in occlusion, were almost identical for the two samples.

The relation of the condyle was found to vary more than has been thought in its relation to the external auditory meatus (5 to 10 mm.) with the condyle at physiologic rest, but some of this variation is explainable on the basis of the absolute size of the condyle. In Class II the distance between these two structures at rest was significantly greater because the condyle tended to be forward at this position.

The slope of the posterior surface of the articular tubercle was found to exhibit a wide range of variation (50°) in both Class I and Class II, and no definite difference could be established between the groups.

There did not seem to be any relation between steepness of the condylar path and the type of occlusion when related to the occlusal plane.

Aside from a high degree of variation nothing significant was noted about the height of the eminentia articularis and no differences were noted between the two samples studied.

The roof of the glenoid fossa was found to vary from a position slightly below the level of the PO line to one 6 mm. above it. That of the Class II group was at a slightly lower level, but it should be pointed out that this could be explainable on the basis of age, the Class II sample being younger.

Division 1 showed a more posterior path of closure than the Division 2, but Division 2 showed wider interocclusal (freeway) space.

The mean values of the angle to the eminence increased with age as the height of the eminence increased.

It seems apparent that a complete and correct analysis of the temporomandibular joint, for either investigation or diagnostic purposes, cannot be made unless a method is employed that reveals the true position of mandible in both its resting and closed positions.

DR. RICKETTS WORK ON ESTHETICS, ENVIRONMENT AND RICKETTS LAW OF LIP RELATIONSHIP

Ricketts in 1965 published two papers which dealt with some of the functional or muscular factors involved in esthetic considerations. His work dealt specifically with the chin, the lower alveolus and the environmental condition. He called these three structures as the “Key stone Triad”, and listed many other anatomic, physiologic and growth factors which should be considered in this complex longitudinally.

He enumerated nine factors which should be considered in the analysis of oral soft tissues and said that specific attention should be given to the area of tongue and Lip balance.

1. The correlation of morphology and function is implicit in most conditions of lip relations. He feels what good works looks well.
2. The tongue interacts with the lips in all functions such as mastication, speech, and deglutition and even in tonicity at physiologic rest.
3. Lip and tongue function is read from the cephalometric X ray film.
4. It is recognized that the lips are influenced by the teeth or that conversely the teeth are influenced by the lip.
5. The lips are viewed in perspective or considered in multiple dimensions.
6. A distinction should be made between mouth disharmonies and lip imbalances.
7. Combination of conditions are recognized in the context of

patterns as the conditions are isolated, classified and then correlated into patterns for intelligent understanding.

8. Lip and mouth conditions are considered longitudinally because more Lip prominence or more recessive mouth characteristic may develop as the patient grows.
9. A flamboyant outgoing personality will frequently accept a more prominent and forward denture and it is possible that recessive dentures are more suitable for withdrawn persons although these ideas are not totally applicable.

Ricketts felt that it is the job of the scientist or the purpose of the diagnostic clinician to study the integrated pattern that combinations forms and to fit them into the total picture of analysis in the understanding of the individual situation.

With this in mind, Ricketts in 1953 made some preliminary attempts of description and classification of Lip relation. A range of normal relations instead of a single ideal was recognized. To start with, a line was drawn from the nose to the chin simply to assist in the description of mouth relations to adjacent structures. He called this line as the “Esthetic plane or E line”. He recognized that the mouth should be related to the cheek bones for a total perspective but he did not mention it quantitatively. From publications of others and from common experience with the lay public and with some artists he noted that most people object to lips that protrude beyond the E plane. Lip prominence seems to be an undesirable trait and an unacceptable situation in adults.

At the start of these scientific investigations both the upper and lower lips were considered. Because the curl of the lower lip and its position were determined by the upper incisors, it was considered unnecessary to measure the upper lip. The upper lip was finally related to the lower lip as the lower lip became the basic reference.

Ricketts found that the lower lip position was located at a mean distance of 4 mm posterior to the E line, with a standard deviation of 3 mm. It was also located on a plane ahead of the root of the nose or alar cartilage. Ricketts found that the mean range was greater in males than in females and the line from tip of the lower lip could extend backwards almost to as far as the alar cartilage. As a working hypothesis for an objective of the lower Lip in treatment of patients of pubertal age or for the typically finished case at the age of 12 to 14 years. Ricketts suggested a mean of -2.0 mm with a standard deviation of ± 3 for the lower lip behind the E plane. This hypothesis gives an orthodontic range of -5 to + 1 mm.

After many years of clinical use Ricketts brought work on E plane to its culmination with the formulation of a law which he called the “Law of Lip relationship”. It states as follows “In the normal white person at maturity the lips are contained within a line from the nose to the chin, the outlines of lips are smooth in contour, the upper lip is slightly posterior to the lower lip when related to that line, and the mouth can be closed with no strain.

Although the law of lip relationship was adequate for consideration in sagittal plane this law was not quite complete because of the need for three dimensional planes of concern. Subsequent to the use of esthetic plane, Ricketts in 1958 recognized that mouth width or the frontal dimension was

also an important variable. In order to devise a means of establishing proportionality, a line was drawn through the inner and outer canthus of each eye and by dropping perpendiculars through the pupils of the eyes, reference lines were erected. These were called the pupil planes and was recognized that usually the angles of the mouth fell almost halfway between this line and the outer limits of the alar portions of the nose in faces with the most harmonious proportions. The width of the mouth was measured from the angles. Therefore, an interangular dimension was obtained in photographs corrected to true life size. In patients with the narrowest mouths, the interangular dimension approached the width of the nostrils. Wide corners of the mouth were observed to extend to a width directly below the centers of the pupils of the eyes. A rating scale was thus established from 1 to 5. The most narrow mouth was rated from 1 to 3 while the widest mouth was n the rate of 4 to 5. (Fig.2)

In order to evaluate the mouth balance completely, Ricketts introduced a third plane which was drawn on the lateral film from cheek prominence to the chin. This was called the “Cheek plane or C plane”. Ricketts observed that prominent cheeks deserved more prominent lips while recessive cheeks might be better served by flatter mouths.

Since the lip problem strike at the very heart of orthodontic analysis the introduction of the three reference lines-

1. The esthetic plane
2. The pupil plane
3. The cheek plane

These planes serve as the basic line for observation and communication.

Ricketts feels that the lip length or the inherent size characteristic of the lips is a basic consideration in the evaluation of an orthodontic case. It is easy to recognize the short and atrophic upper lip but the shortened lower lip is frequently overlooked in this condition. In problems of this nature, facial height must be taken in to consideration. Proportional lip length therefore is a primary critical consideration in lip imbalances and the upper incisors may have to be intruded to harmonize with the lip embrasure.

Another classification of lip relation suggested by Ricketts assumes that natural adequate lip length is available. However, as a result of protrusion of the upper incisors during function, the lips are pursed and the angles of the mouth are drawn forward in strain. This condition may or may not be accompanied by furrowing in the area of the lateral contour of the nose down to the angle of mouth which Ricketts has termed as the “Caninus Furrowing”.

The next classification suggested by Dr Ricketts was that of sucking of the lower lip or sometimes the lower lip biting. The lower lip is pulled under the upper incisors to create a seal during the swallow. There might also a slight pursing of the lips but in severe types, particularly if the habit persists, there is a contraction of the risorius muscles on each side. The corners of the mouth also may be pulled downward and backward. These patients frequently display deep overbites and severe overjets of the teeth, but their molar or jaw relations may or may not be class II.

A classification that is often misdiagnosed is the “Sublabial Contraction”. These patients usually display a prominent chin or a button. Although one might conclude, on first inspection, that these patients possess

strong mentalis habits or that the problem is chiefly with the mentalis muscle, the condition actually is recognized by hypertrophy of tissue in the area immediately above the chin and below the lip. Ricketts postulates that this condition of furrowing below the lower lip might be due to an anatomic joining of the two quadratus labii inferioris muscle uniting across the midline. This would form a band of tight tissue and could account for the condition, although the exact reasons are obscure. The last classification is that of “Perioral Contraction”. This condition of the caninus together with sublabial furrowing is characteristic of this tongue thrust syndrome and almost diagnostic of it. The attempt to oppose the tongue causes extensive circumorbicularis action, and the whole complex becomes strained. The buccinator caninus triangularis muscle complex hypertrophies. This is also diagnostic of some cases of temporomandibular joint at normality with atrophy of the muscles of mastication. It has been observed in patients with poliomyelitis of the masticatory muscles for closing the mandible in the absence of other muscles, the patient may use lip and face muscle. Complete perioral contraction constitutes a gripping of the muscles around the entire denture.

The lip function can not be divorced from tongue function because they work reciprocally. The tongue and faulty deglutition were taken up by clinicians on both sides of extraction issue. Open bite and relapse were explained by the preservist as being due to faulty deglutition, while the extractionist looking for answers to lapse fell upon tongue training almost as a panacea for all orthodontic ills.

Realizing the need for a classification of the tongue thrust syndrome, Ricketts attempted to classify the tooth apart swallow and to organize his

observations. It was recognized that all patients swallowing with the tongue between the teeth did not do so in the same sequence, with the same degree, frequency, or duration of the activity or from the same base. Ricketts conducted a study in which three different types of swallowing problem were demonstrated and a relationship between morphology and function was suggested.

Thus Dr Ricketts concluded that;

1. Problems of the tongue and deglutition are truly primary problems in orthodontics and in some patients appear to be acquired during treatment. Patients refusing to settle almost always swallow with the tongue between the teeth and slight openbites prevail in retention in these cases.
2. Although open bite and lack of cuspid function are commonly associated with tongue problems, posterior open bite, cross bites and deep bite in the anterior area are also influenced by tongue conditions and by faulty deglutition.
3. Not all deglutition problems are alike. Some patients have habitual or chronic postural problems with tongue positions constantly occupying the space between the teeth while others thrust the tongue forward only intermittently but vigorously. Cases of true glossoptosis can be observed with severe crowding of the denture, yet the patients can be still tongue thrusters. Also the positioning of the tongue between teeth may be acquired secondarily as a result of other primary factors. Respiratory obstructions occur from a variety of causes and result in the mandibles being dropped. Even pain in the teeth is lessened by the cushioning effect of the soft tongue during deglutition. All of these

factors result in acquired tongue habits which are adaptive in nature.

4. Tongue thrusting includes a growth phenomenon. It is observed with far greater frequency in children than in adults, but it still is found in adults. It also extends into the retention period in orthodontic practice.
5. The inability to cope with the severe tongue thrust syndrome suggests that the condition is related to some deep underlying structural, neurologic or even genetic problem in some patients. For instance, the tongue thrust in the severely dolichofacial person with short lips must be strictly compensatory to the structural relations, which have been called skeletal openbites. In other patients no type of treatment seems to produce lasting results. The dominance of the kind of phenomenon warrants a fourth class of tongue parameter which is neurologic.

Although the tongue thrust syndrome is recognized, the description and classification of problems has been verified. The etiology of many of the tongue problems still is not proved. The hypothesis most acceptable to those working closest to the field has implicated respiration as a primary concern.

Under the above hypothesis, investigators have been led to another phenomenon that is not commonly known. Important observation directed attention to bottle feeding. Straub noted that the incidence of tongue thrust was significantly higher in children who had been bottle fed. However, another even greater etiologic factor is speculative, the infants sensitization to cows milk. Communication with pediatrician is well as some preliminary research has suggested that mild allergy or sensitization to unnatural milk is common place and could conceivably incite a lasting phenomenon. Almost the first systemic effects of allergy are observed in the nasal membranes and

affect breathing. Theoretically, the lower jaw tongue may acquire a forward functioning position as a compensatory mechanism. The question remains, could this habitually acquired condition constitute a lasting conditioned reflex pattern for the swallow. The oral environment therefore is altered by respiratory obstruction either directly or indirectly. The obstruction may be chronic or of interrupted nature.

Orthodontists however emphasize on the lips and the mouth relations in analysis and diagnosis. Ricketts attempted to organize, clarify and classify lip conditions for analytic value. He emphasizes that however the growth, behavioral characteristics, sex and ethnic type should be considered as the basic etiology in the total frame of heredity and environment in a biologic sense.

Ricketts, after a lot of research on normal values has described the law of lip relations which includes both functional and esthetic considerations and states that the lips of white adults are contained within a line from the nose to the chin, the lower lip is closer to the line than the upper, the lips are smooth in contour and the mouth is closed with no strain.

ARCIAL GROWTH OF MANDIBLE

Dr Robert Ricketts has explained a principle of arcial development as a basis for explanation of mandibular growth in the human beings.

Principles in biology are extremely difficult to come by. This is true because principles must be universally acceptable and must prove effectual in repeated application to the related science.

In 1771, Hunter compared a series of dried mandibles and concluded that in order to attain space for the development of permanent molar teeth, the mandible must grow by posterior apposition of the ramus accompanied by anterior ramal resorption. Later, Humphry in 1866 tied wires around the mandibles of pigs and showed that the wire became embedded in the posterior margin and were free in the anterior area of the ramus which seemed to verify the “Hunter Hypothesis”.

Brash in 1924 following the work of Humphry in his animal experiment, fed madder plant root to pigs which contains the red stain alizarine and confirmed the appositional bone growth. The conclusions were the same as reported by Hunter and Humphry.

The duplication of these studies by later scientists on the rat and the monkeys also tended to confirm this phenomenon in other mammals.

Growth in size and position of the mandible has been studied extensively with the method of roentgenographic cephalometrics by Ricketts. He used a technique of body section laminagraphy for determination of body growth.

Clinical investigations and prediction of Mandibular Growth-

The early laminographic studies of Ricketts suggested that tendencies toward squareness, heaviness and strength of the mandibular ramus tended to be associated with forward development of the chin and deep faces. Obtusity, fragility and weakness of the mandible seemed to contribute to more downward or backward development of the symphysis in the face. The interest in determining growth factors stemmed from the need for applying basic knowledge to the correction of malocclusion and facial deformities, particularly as growth and morphology relate in a clinical context to open and closed bite.

Therefore on the basis of these early studies, a primary method of prediction of development was devised by Dr Ricketts by plotting a line through the long axis of the condyle and neck and extending it to the lower border of the mandible, the bending of the mandibular form during growth had been studied. Consequently findings from this method by Ricketts suggested that the technique could serve as a working hypothesis for growth projection for the clinical problem of prognosis of growth.

Although the Ricketts method originally described was useful for short range predictions a method was sought whereby mandibular growth pattern could be identified with greater certainty. The findings of Bjorks implant studies had revealed that the lower border of the mandible was resorbing and that the mandibular plane was not acceptable, as a reference base for growth analysis.

The next move toward improving the method was to identify a “central core” cephatometrically. Enlow also concluded that the mandibular

ramal surface is subject to remarkable remodeling and therefore not reliable for reference. The attempt to overcome surface variation and to determine central or internal structural, phenomenon resulted in the promulgation of new reference points.

First, a point (xi) in the center of the ramus was located. The determination of a point of reference at the ramal centroid was difficult.

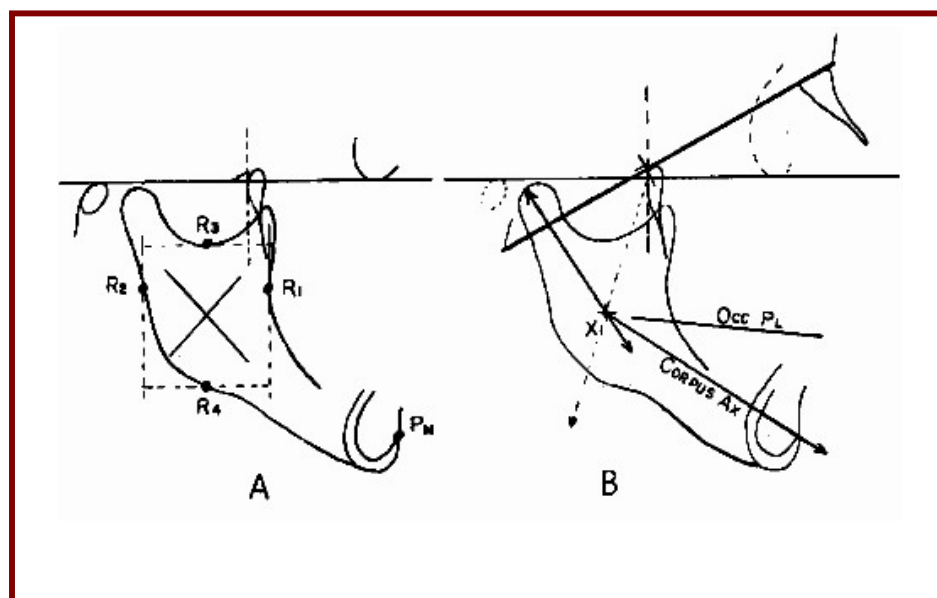


Fig1. One method of locating Xi Point— Center of R1, R2, R3, R4. XiPm = Corpus Axis. The corpus-condyle axis bend and its arc of behavior.
B. Note occlusal plane relation to corpus axis.)

It was recognized that Lateral roentgenographic cephalometry does not reveal the mandibular canal with certainty. Neither was the selection of the mental foramen certain, although frequently both the mandibular canal and the mental foramen may be risible.

Second, a point at the superior aspect of the symphysis was selected as suprapogonion. It was labeled Pm (for protuberance menti). This is substantiated as a reference because it is located at approximately stress center (Ricketts), it is the site of reversal line (Enlow); and also it is

consistent with the findings from implant studies (Bjork) which indicated stable unchanging bone in the area of chin. Therefore, a bone crest, located at the superior aspect of the compact bone on the anterior contour of the symphysis, was accepted as the most stable and useful reference for anterior-most basal bone in the mandible. Recognizing this problem the center of the mandible was located geographically by measurement. By bisecting the height and width of the ramus at its narrowest dimension, a geometric center was determined and labeled “Xi” point. Investigation of normal mandibles from twenty five dried skulls showed in every instance that this point fell in contact with the mandibular canal.

Third a point was used which had been labeled “Dc” was a point at the bisection of the condyle neck as high as visible in the cephalometric film below the fossa.

Accordingly, by connecting Dc point with Xi point, a repeatable “condyle axis” was established. Further, by connecting Xi to Pm, a “corpus axis” was erected. Consequently, by studying linear growth on these planes and the form change as a change in angulations between the two, an interpretation could be gained regarding the characteristics of mandibular growth in a given patient as well as for groups with sex and age differences. Once values were determined for these dimensions and corrected for biologic considerations, the changes in magnitude and angular relations served as a second method for predicting mandibular growth with a projection technique. A great deal of biological emphasis still was placed on condylar growth with this forecasting technique by employing internal lines. This method of Dr Ricketts proved to be more accurate than the previous method of relying on surface lines. It not only was more successful as a

method of forecasting, but also served as a catalyst for more extensive research in mandibular growth.

The objective of research was still toward finding a method to critically predict future form and size of the mandible over the long range as to maturity as a basis for treating deformities in the child, and for the best esthetic and functional equilibrium by adulthood.

Computer study

Ricketts conducted a five year growth study of mandible and lower dental arch was conducted as a part of a large computer study of craniofacial morphogenesis. The principle of triangulation in cephalometric points was followed in order to eliminate or correct possible errors in measurement.

In the lateral and frontal head films, 362 measurements were employed for the complete study. Standard deviations were studied and every measurement was correlated with every other by the co-efficient correlation in both time 1 (beginning) and time 2 (end). Standard deviations of change and growth correlations also were rendered by the computer as a comparison analysis.

The material for this primary computer study consisted of lateral and frontal cephalometric films on forty patients. The beginning films were made at the average age of 8 years¹¹ the second group averaged 13 years of age. The range was ± 2 years of the 8 years level. However, this sample was selected to cover the transition from the mixed dentition to the development of the permanent dentition and not to an exact chronologic time. None had been treated orthodontically. Half of the samples were males and half were females. Twenty were Class I and normal occlusions while the other twenty

possessed class II malocclusions. One objective of the study was to test for any differences in growth of patients with malocclusions as compared with individuals with normal occlusion.

It was recognized that a bending was occurring in an orderly manner and therefore the greater the magnitude of growth, the greater the bending. It was apparent that a growth arc was operative. After using the Pm, Xi and Dc points as a method of depicting the cortical “core” of the mandible. Experiments were under taken to determine a method by which the form and size of the mandible, after a five year growth interval could be predicted with use of only the first x ray as a reference.

The first move was the construction of an arc in the time 1 composite through the three points Pm, Xi, DC. By extending this arc the size increase was produced but not enough bending in form resulted.

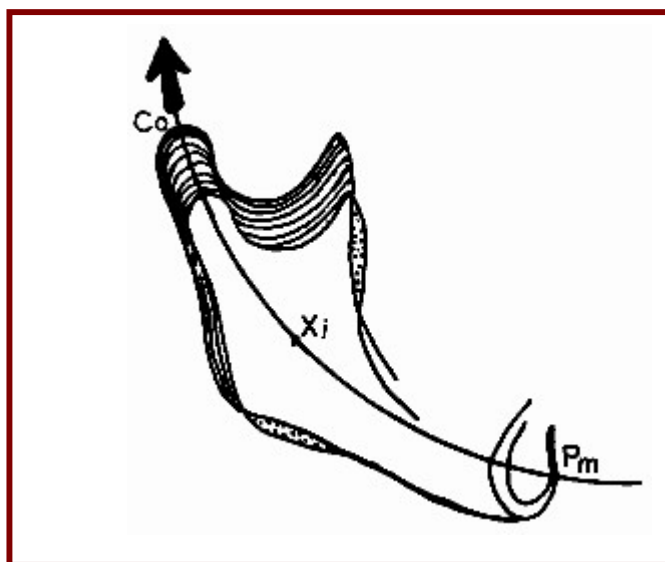


Fig. 2

Fig.2. *Experimental arc with computer composite of a 40-patient sample five years without orthodontic treatment. This arc through condyle was too open for average, but typical of Class III.*

A second arc through coronoid process produced the deepest curve, (fig2) Experimental arc with computer composite of a 40-patient sample five years without orthodontic treatment. This arc through coronoid was too closed.

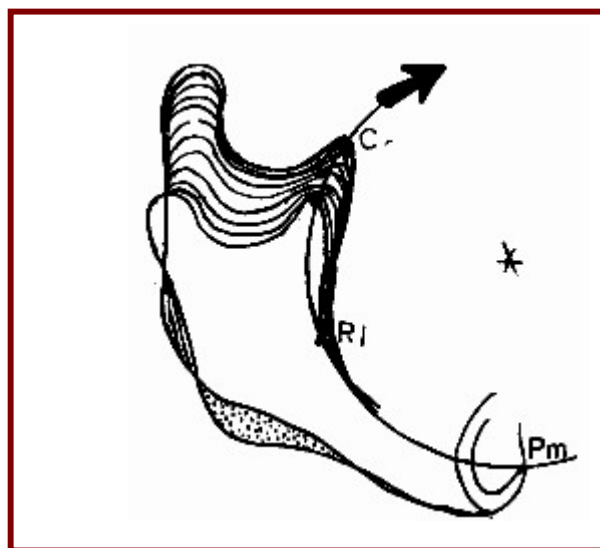


Fig 3

It was explored by using the tip of the anterior border of the ramus at it's the same Pm point. The extension of the segment of a circle too small in excessive bending of the mandible when growth was employed for a projection.

The two arcs produced by Dr Ricketts out of which one straightening the mandible too much and the other resulting in too much bending. A true arc of growth therefore must lie somewhere in the mandible between the condyloid and the coronoid process and between the ramal center and its anterior border. By establishing a halfway point between Xi and R1 points (the center and anterior border of the ramus) and using the distance from this point to Pm as a radius of a circle, an arc could be produced. The use of this

arc still bent the mandible a fraction too much. In addition a radius selected from this point would increase with size of the mandible and a progressive increase or a changing arc or ultimate spiral shape would result. Growth therefore could not be represented as a simple segment of a circle.

Ricketts thought that perhaps the stress lines of the mandible would reveal its hidden secrets. The study of mandibular slices through the center of the ramus failed to show definite architectural designs because the inner and outer plates are very heavy and carry the load.

Attention therefore was directed to a mandible, alleged to be 850 years old, which had been given to Ricketts by the late W.B.Downs. This mandible had been weathered to a state of disintegration of the interprismatic substance of the external cortical bone, and therefore clearly showed stress lines in the outer and inner plates. The lines thus exhibited the design of the mandible for bracing externally. It was hoped that these functional stress lines would also yield some clues, regarding the possible development of the mandible, for we know that stress tend to run parallel to bone trabeculae. The load being carried in the superstructure of a bone thus can be analyzed. By the analysis of compression, extension, shear and torsion, these lines begin to fit a pattern.

Close examination of mandible by Ricketts confirmed the convergence of stress line at the protruberance menti .The stress lines seemed to swing downward and then upward and backward through the external oblique ridge.

However great attention was directed toward the medial side. On the internal aspect even greater forking was noted than was seen on the lateral

side. The stresses here followed the mylohyoid ridge upward into a thick mass to terminate at a Y shaped bony prominence. This was almost the center of the upward and forward quadrant of the ramus on the lingual aspect and, in fact, might be the base of the tuberosity of mandibular growth. Accordingly, both the inner and outer tables showed confluence at this area of the mandible.

Experimentally, two new points (Eva and TR) were located geometrically

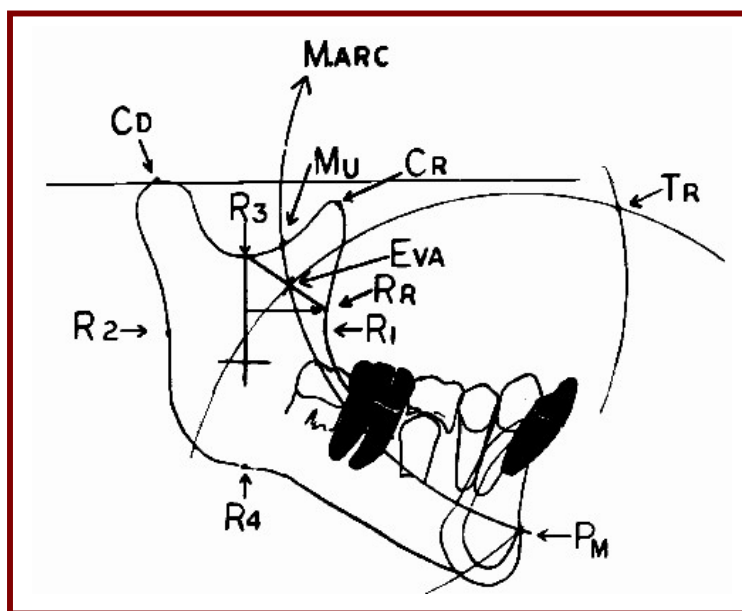


Fig. 4

Fig.4. Method for construction of the arc of growth. MU and Frankfort orientation)

When the size increase of the mandible as determined in the computer study was incrementally added to the arc at the sigmoid notch, it was found that the predicted mandible was almost absolutely correct in size and form when compared with the final composite .The true average arc which closely

fits nature's usual growth reaction (as viewed in the lateral film), and it may or may not confirm to implants exactly.)

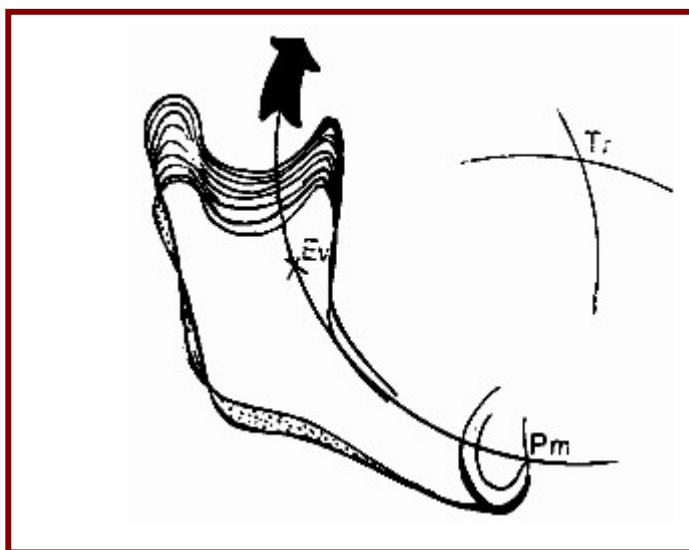


Fig. 5

The method as devised for K factors (constants) proved extremely accurate.

Having become satisfied with the arc as a tool for prediction, the next problem lied in the amount of growth to forecast on the arc. The yearly increase from the combined studies was discovered to be almost precisely 2.5 mm. Averaged over the years of the time, it was an excellent population constant. Cutoffs for growth were determined to be 14.5 years for females and age 19 for males.

Next twenty longitudinal cases with a range of duration from five to twelve years were measured. This study of Ricketts revealed that the increases were different when measured from a point at the crossing of the arc with the sigmoid notch. The point of crossing was labeled point MV.

The coronoid and condylar processes grow upward and outward in a direction essentially as a function of the curve of the original arc. This means that sigmoid notches with arcs of a small radius tended to stay small, while widely divergent condyles and coronoid processes or notches with wide radius tend to stay extended. As these values were determined and used experimentally on more than 100 patients, a K factor for the coronoid process growth came to be 0.8 mm per year.

Ricketts observed that damaged condyles did not behave normally, nor did true prognathic types. Neither fit the principle of normal growth. These conditions are rare and need to be identified because, as cases of this kind are observed, the forecast becomes diagnostic of abnormal growth.

Further studies were consistent with the behavior of gonion in the computer study.

The combined studies showed that the gonial angle drifted posteriorly on the arc almost exactly one half the total increase in mandibular growth on the arc.

To determine the space available for the developing mandibular third molar at the anterior border of the ramus or the external oblique ridge the RR point was reemployed. As the time 1 tracing is compared with the forecast being constructed, it is assumed that stable bone is located here. Thus with normal anatomical contouring the coronoid process is connected to RR point, which tends to determine ramal width. Slightly below this point, the external oblique ridge will show apposition of almost 0.4 mm per year.

Ricketts made extensive investigations in 1955 on the treatment behaviour of the occlusal plane. The occlusal plane was again studied relative to more than three dozen points and other planes as well in a nontreated sample.

Discussion of five relations seem 'pertinent to new clinical implications-

First:

The angle of the occlusal plane to the corpus axis tended to be regular and orderly.

Second:

There seemed to be some functional or biologic relation to the development of the posterior end of the occlusal plane to Xi point which represents the mandibular foramen, while the distal end of the plane from the true buccal occlusion dropped downward slightly with growth, a plane if drawn through the second molar, would move it back up to its original position. This is a biologic clue to the development of the curve of spee.

Third:

The occlusal plane tended to hold its relation to the embrasure of the lips at the forward end.

Therefore, it seemed that the vertical development of the lower dental arch and the occlusal plane took place naturally as a function of mandibular growth. As the arc was growing the symphysis or chin was pushed under the denture as the teeth erupted upward and forward. This explained chin button development.

Fourth:

The horizontal or anteroposterior movement of the lower incisor seems to be biologically related to the APO plane. The mean values for lower incisors to the APO plane tend to match for malocclusions and normal and successfully treated cases. This means that the lower incisor relates to the convexity or facial type in all age groups. The prediction of the anterior position of the lower incisor is, therefore, related to the prediction of change in convexity by whatever factor is causing the change.

Fifth:

The lower molar tends to erupt upward and forward with the occlusal plane from the mental protuberance. Given the adjustment which may occur with leeway space in the transition stage, the molar can be predicted as a function also of mandibular growth. This shows clearly that space for the erupting third molar is made by upward and forward eruption of the dental arch in front of it. If the lower arch is held backward space loss for third molar teeth can be expected if space is created by forward movement, a better prognosis should follow.

The arcial growth study pointed the way to the answer of the third molar problem. Ricketts studied twenty five adult skulls exhibiting normal occlusions with the aid of a lateral head film. From this group of skulls a hypothesis was determined that the lower third molar must lie fifty percent ahead of the external ridge for a fifty percent favourable prognosis for its eruption. Theoretically, the prognosis could be one hundred percent favorable if the molar (in cephalometric lateral view) is located completely mesial to the ridge. Conversely the further distal (or the more it is covered by the ridge) the poorer the prognosis for eruption.

To check this hypothesis, thirty one treated cases including a variety of malocclusions were studied by Dr Ricketts. The head films were taken at an average age of twenty one years.

The preliminary conclusion from the twenty five skulls and thirty one head films seems to verify the hypothesis of the 50 percent favorable prognosis mentioned earlier.

This would seem to verify, also another hypothesis that the third molar can be prognosed early and should be removed if nonextraction is to be a part of the planned treatment because 45 percent of the nonextracted cases required third molar extraction. However these are preliminary conclusions only and further verification is needed. It is a start to bring some order out of this bewildering third molar issue.

It was sure by this time that mandible grows in an arc of some form. Human mandibular growth can be reduced to a simple segment of a circle in a lateral cephalometric image. If this arc represents the true character of mandibular growth, the traditional viewpoint that “normal” lower molar teeth acquire space for eruption by ramal resorption must be modified. Rather, it is suggested from recent studies that eruption and alveolar growth in the upward and forward direction is the process by which the space is made available.

From the above study Ricketts has explained the findings of the growth of mandible and its effect on orthodontic treatment and role in retention and relapse. These can be enumerated as

1. It appears (through Superimpositioning of outlines) that the symphysis rotates essentially during growth from a horizontal to a more vertical inclination, and the suggestion is presented that the genial tubercles and

the lingual plate drop downward in the process. This explains the major part of the form characteristic of the symphysis in the cephalometric film (chin button development). Implant studies have shown that greatest apposition takes place at the inferior margin of the symphysis (and perhaps the posterior side) in the preschool years. The growth by apposition may appear lateral to the mid line on the symphysis as bulk is needed for bracing.

2. This phenomenon explains why reversal lines are observed at the area of pogonion and suprapogonion.
3. It explains why the mandibular plane changes extensively in some individuals and not in others.
4. It shows why ankylosed teeth are observed to affect occlusal plane development.
5. It explains how the early ankylosis of a lower molar tooth terminates with the tooth located at the lower border of the mandible, the mandibular arc simply continues and this tooth becomes trapped with in cortical bone and the lower border resorbs up to it.
6. It suggest a reason why mandibular anchorage is risky in retrognathic faces because less space is available for molar eruption due to a more vertical eruption in that type than prognathic types.
7. It explains why the lower arches of brachyfacial or square faces can be expanded and brought forward, and will remain stable.
8. It explains why good dentures may become progressively more crowded in long, tapered faces and sometimes even in normal faces.
9. It explains how third molar impaction can occur by bone growth around the molar rather than its submergence in to the ramus.

10. It offers a possibility that impaction of third molars can be prevented by simple enucleation (at age 6 to 8 years) of the bud which lies on the surface, not within the bone.
11. It suggests that abnormal growth or warping of the mandible can be understood as a function of relative contribution of the coronoid and condyoid processes.
12. It shows positioning of the roots of the lower first molar to the buccal, or locking them under cortical bone, will prevent upward and therefore, forward eruption of the whole lower dental arch thereby enhancing anchorage of the lower arch.

The regularity and accuracy with which this arcial method is now applied suggests that a principle may be operable for the phenomenon of mandibular development.

It must be understood that the growth expressed on the arc and the resulting mandibular effect on the face are different processes. Upward and forward ramal mandibular growth on the arc as described would lead to an upward and forward shift of the chin in the face. As the arc develops there must be a downward rotation of the mandible in the face in order to maintain the central axis of the face, or facial axis as a constant on the average. This phenomenon tends to be keyed to the neurological bed of the face, namely, the orientation around the branches of the trigeminal nerve. The postural kinetic chain or neurophysical input to the muscles which position the mandible in the face constitute other factors.

Preliminary studies as a part of this work have suggested that in the typical orthodontic practice, with proper attention there is a likely hood of as much as 50 % incidence of the eruption of functional 3rd molars.

DR. ROBERT M. RICKETTS
On Growth Prediction

- **Motivation to estimate or forecast growth**

RICKETTS received motivation from one of his mentors, Dr. William Downs, from 1947 to 1952. Downs (in 1948) was originally trying to select a group of measurements which would help him explain to his students what he was seeing on the headplates. In his paper of 1952 he talked about using cephalometrics as a prognostic tool regarding the “swing of the face”. Downs was “reading the pattern” and trying to anticipate in which direction the patient's face was going to grow on interpretation of the morphology, but he realized it was only a hunch.

Ricketts was there on the research scene at the University of Illinois to assist Downs in the clinic.

Ricketts studied the types he had observed and their characteristics, and figured how these observations plus the technique of projection of the architectural lines would influence the treatment plan. He was using the contribution of growth to the active treatment only, but of course was grossly estimating the future intuitively, like everyone else. “Long range forecasting” came twenty years later.

- **Determination of the exact increment of growth for each part measured.**

By establishing a mean and statistical curve of distribution for the change in each basic reference line used. In the beginning, he started with the cranial base triangle.

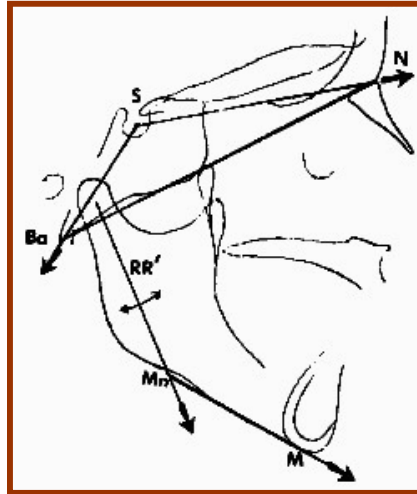


Fig.1

Fig. 1 *The original planes used for prediction. The original cranial base triangle and the condyle axis (RR plane) employed to connect the base of the skull to the mandibular plane. Note Sella and Nasion, the Mandibular Notch and Menton.*

Sella-Nasion and Sella-Basion were measured for cranial base growth on a sample of patients during treatment. He attempted to determine the differences between boys and girls at various age groups. Average values were used for each plane on the basis of sex characteristics at puberty

He started with average values; they were added to the individual shape and size already present. By projecting individual lines, plus introducing physiologic mandibular rotation as a calculated result from the anticipated correction, the total skeletal change could be plotted during treatment, including a change, if anticipated, in the maxilla. These were put together cybernetically (feedback) in order to derive the facial morphology most likely at the end of treatment.

After the skeleton was set up, the balance of the denture relative to the APO line was considered.

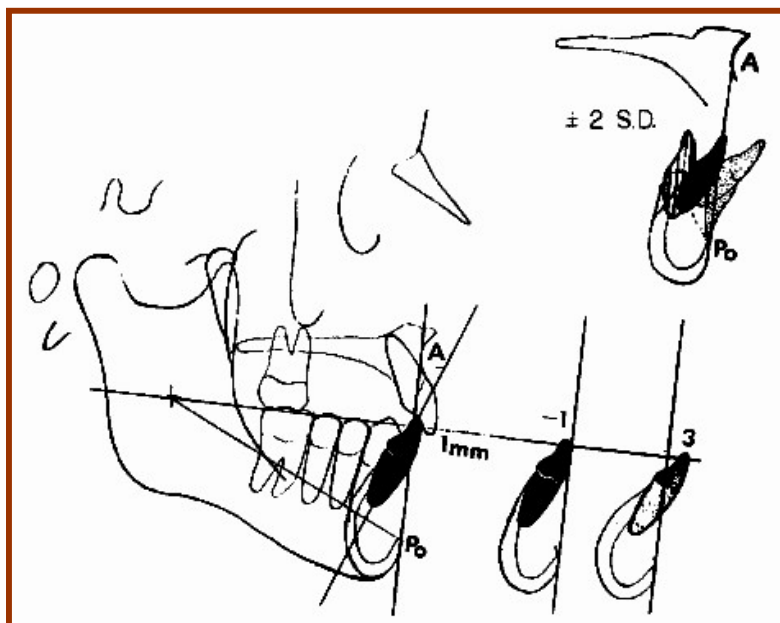


Fig.2

Fig.2 The use of the anterior limits of basal jaw bone (A-Po) for the setup of the position of the denture. The peak of the curve is + 1.0 mm and one clinical deviation is 2.0 mm.

A line of reference that would express the forward or backward position of the lower arch was needed. The stimulus that started the investigations which ended with the recommendation of the average lower incisor to the APO line to be 1.0 mm (and originally inclined at 22°). The clinical deviation is ± 2.0 mm representing two-thirds of cases to lie in the range of -1 to +3 mm.

- **Lateral x-ray and frontal views for case analysis.**

Dimensions from the frontal headfilm are also calculated using the computer for determining facial volume. This value is used to determine whether a linear dimension is large or small for that individual patient. This (plus comparisons to age, sex, and ethnic type) permits the computer to individualize a patient.

According to Dr Ricketts the lateral headfilm is still far more critical than the frontal because it deals with anterior-posterior change, change in convexity, overbite and overjet change all in the sagittal and vertical planes. The only thing left out is the horizontal plane or the transverse parameter in the frontal film. This is critical in terms of maxillomandibular relationships in the frontal dimension. All crossbites, all arch length problems have useful information coming from the frontal headfilm.

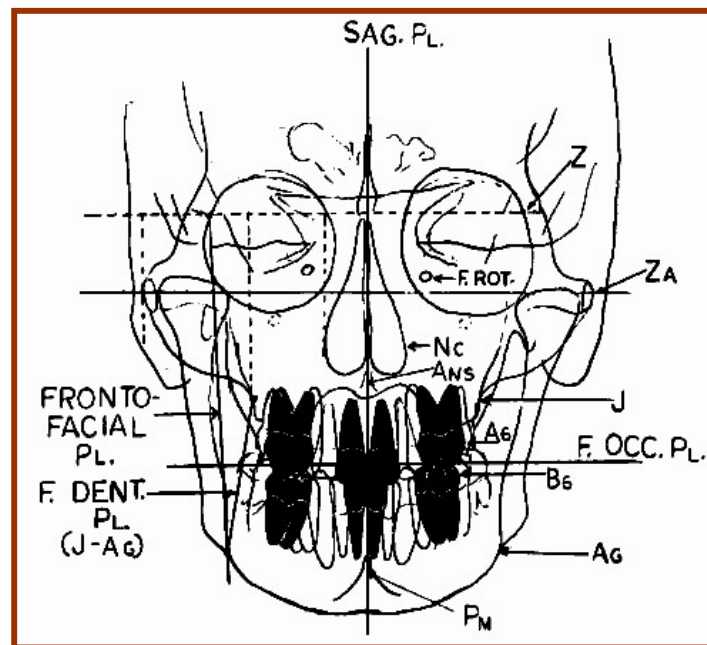


Fig. 3

Fig.3 A frontal headplate analysis. Shows features measured in present analysis. The malocclusion, jaw relation, tooth locations and facial type are extracted from the tracing with the computer program.

- **To obtain proper location of the essential reference points.**

Dr Ricketts mentioned that to obtain proper location of reference points first, obtain good films, well oriented. Second, increase confidence in ability to identify anatomical structures in a headfilm. If one has a casual attitude, he is going to make errors. Because the mandible is so critical, it is

most important to study the osteology of the mandible. Trace the same headplate three times, one week apart and compare them later

- **Popular reference points and planes which were used by Dr Ricketts**

Probably the three most common analyses include the most popular points, and all seem to have glaring weaknesses. He stated that sella is easy to see. Perhaps it has therefore been relied upon too heavily to be (1) Centre for descriptive reference and (2) An unchanging reference for facial growth. Perhaps next in popularity is Nasion, but it needs care in selection because the frontonasal suture may slant upward and all that can be seen in some patients is a slight depression. He found that SN is just as reliable for reference as any other anatomy in the anterior cranial base— if you rely on the anterior base for reference.

He found that Porion is directly above Basion and the dens and the articular eminence directly below Sella. Orbitale is no problem if sorting out the rim of the orbit from the lacrimal canal and infraorbital canal is done properly. ANS and PNS are also observed, and the nasal floor sometimes changes in form along with the fact that the nasal cavities may be asymmetrical.

Point B is an alveolar point— plain and simple. It is not basal bone as commonly thought, and it responds to movement of the lower incisor as does point A. In the mandible, a basal structure is available which the mental protuberance is. He termed this PM to differentiate from Pogonion, which is on the most interior curvature

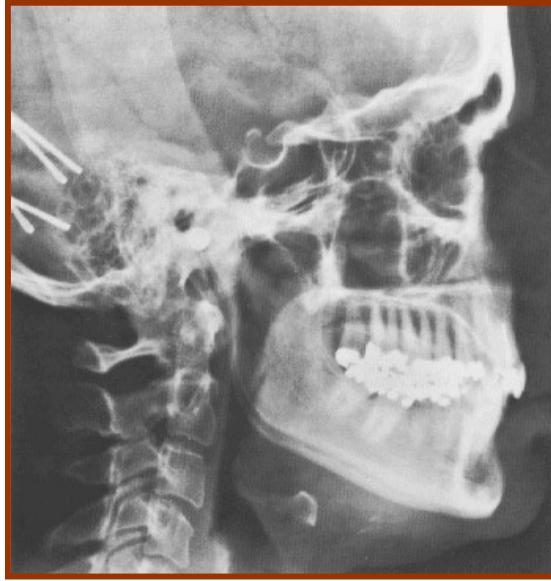

Fig. 4

Fig. 4 *Lateral headplate of an adult with good occlusion. Note the anatomy at the pterygopalatine area, the joint and orbit. Note the distance of the ear rod from the true ear hole. Correlate with Figure 8, which is a tracing made from this x-ray.*

For morphologic analysis as well as growth analysis he used the Basion-Nasion plane as the basicranial axis. With x-ray studies of leaded skulls, he observed that foramen Rotundum could be seen in the lateral film (Fig. 4). By connecting the lower border of the foramen to cephalometric Gnathion, a new more central axis was evident. Foramen Rotundum is in the middle of the base of the pterygoid buttresses at the base of the body of the sphenoid. He labelled the point Pt or Pterygoid Point to denote its biologic significance.

Another line is the true or occlusal plane of the buccal occlusion rather than the bisection of the overbite.

Dr Ricketts pointed that one must make sure that the films are of good quality, study them, and go after the points where one would expect them to be, allowing for the variability that may exists.

- **Reference points— Xi, Eva, and Murray.**

In 1963, Bjork reported in his implant studies that the gonial angle was drifting and the lower gonial border of the mandible was actually undergoing a remarkable resorption. When apposition did occur on the chin, it was not very much on the anterior border, but on the lower border of the symphysis. Bjork showed that we could no longer superimpose on the mandibular plane as a matter of serial reference for study of growth of the mandible or eruption of the lower teeth. So Dr Ricketts had to abandon the mandibular plane for reference.

The area particularly above Pogonion where the mandible starts to recede in the symphysis, or at the top border of the mental protuberance which he labeled as Pm point

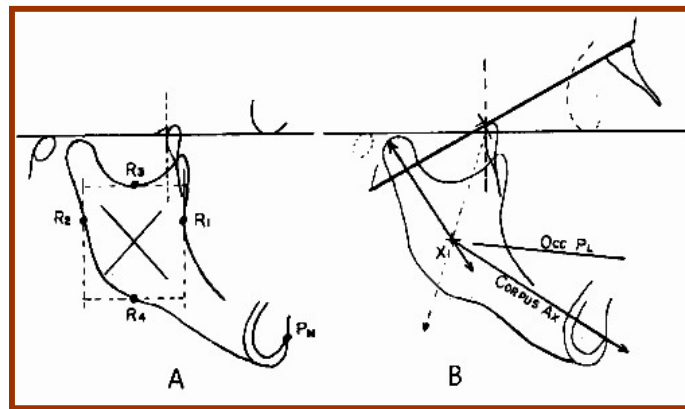


Fig. 5

Fig. 5 *One method of locating Xi Point— Center of R1, R2, R3, R4. XiPm = Corpus Axis. The corpus-condyle axis bend and its arc of behavior). B. Note occlusal plane relation to corpus axis.*

This was the area of least change from the implant evidence. Ricketts could rely on Pogonion area as a stable point anteriorly, but posterior stable point was yet to be decided.

He started to experiment at finding a useful posterior point by measurement. He bisected the height of the ramus from the sigmoid notch down to the lower border in a perpendicular line from FH, then bisected the width of the mandible to see if he could find a centroid of the ramus. He called the point Xi (Fig. 5A).

The true buccal occlusal plane went almost directly through this point time and time again. It was an accidental finding. Using Xi point, he could now begin to draw a line up through the condyle head to a location that was more definite rather than arbitrary, as was previously drawn (Fig. 5B). The position of Xi point from FH was later used as an accurate function of the vertical growth of the ramus also to measure mandibular form from the center of its mass rather than from the peripheral irregularities. Xi point with laminagraphs and showed that it was the center of rotation of the mandible in terms of both lateral excursion in chewing and in opening. Longitudinal studies suggested that it was the key to the behavior of the occlusal plane. A line from Pm, or mental protuberance, back to Xi point became a representation of the body of the mandible. He called it the corpus axis (Fig. 5B). This was the beginning of the development of long range forecasting. The mandible seemed not to be growing in straight line trajectories (Fig. 5B). It was bending on the corpus-condyle axis, and he could measure the bending. The next move was to find the nature of the bend, how much it was bending on the average, and where the bend was usually taking place.

- **Discovery of Eva and Murray point.**

First an arc was constructed through Xi point up through the centre of the condyle head to see if that was the pattern and it opened the goinal

angle too much. Another arc was drawn through the anterior border of the ramus and continued upward through the tip of the coronoid process. That bent (or closed) the growth of the mandible too much. So he knew that the true arc of growth on the average must lie some where between the center of the mass of the ramus and the anterior border of the ramus and somewhere between the condylar process and the coronoid process.

He experimented with an arc drawn from the center of the sigmoid notch through a point bisecting the distance from Xi to R₁ point. That was close, but was still not correct. Finally, without going into details, a center of the upward and forward quadrant of the ramus was determined by bisecting R₂ reference and R₃. He used that distance to create a third point in space as a true radius of the arc (TR).

He decided to name this one after his mother. Her name was Eva, the symbol would be EV. Another reference point at the location of the new arcs crossing the sigmoid notch and named that point after his father Murray.

- **Basion –Nasion reference line.**

Basion, located on the anterior rim of foramen magnum, has been a point used in anthropology for a long time. Having observed it there, Ricketts studied the lateral head x-rays and found it was visible. Therefore, he started using it to construct a cranial base triangle. Subsequently he related the Y axis to BaN and called it the X-Y axis. He felt that this was an improvement in thinking in terms of the face supported by the entire cranial base rather than Sella-Nasion alone.

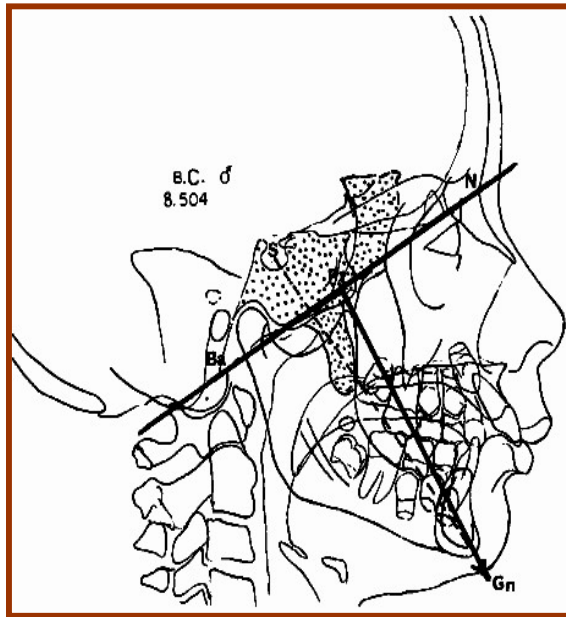


Fig. 6

For another basic reference if a vertical is dropped from Frankfort Horizontal through the base of the pterygoid plate, the coronal suture complex is reasonably represented. Such a line tends to divide the face from the posterior supporting skull base or buttresses. The Basion – Nasion plane will be seen to cross the Frankfort plane very near the top of pterygopalatine fossa.

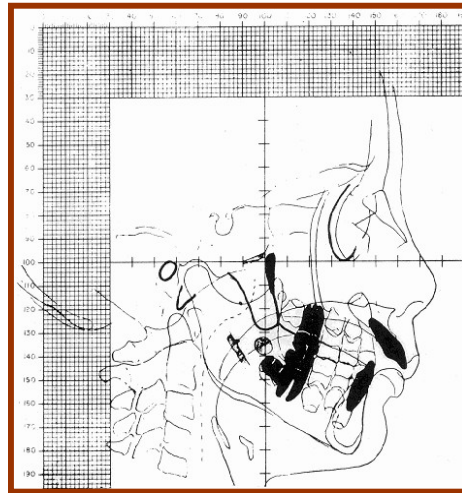


Fig.7

Fig 7 *Coordinate grid with zero benchmark at pterygoid buttress on Frankfort plane. A vertical from Frankfort through the root of the pterygoid plates tends to divide the maxillary complex from its cranial support. It also runs parallel to the general line of the coronal suture complex.*

This area seems to be important because it is the location of the entrance of the blood and nerve supply to the nasal capsule, palatal roof and upper arch. The foramen rotundum, as well as the rostrum of the sphenoid with its bracing support for the vomer, for the midsagittal support of the maxilla are located in this area. By superimposing the tracings on a polar grid, he came back again and again to a central phenomenon of growth form this general location, as Brodie had suggested many times.

The anterior cranial base length is measured on a perpendicular to the Basion –Nasion Plane from the PT point. This is all part of the sophistication of comprehensive cephalometric analysis and forecasts.

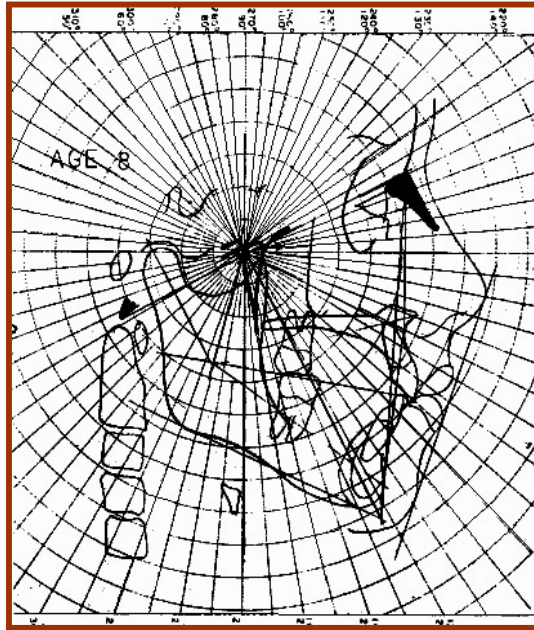


Fig. 8

Fig.8. *Polar grid showing central phenomenon at base of sphenoid*

- **Estimation of soft tissue growth.**

According to Ricketts soft tissues are the most reliable parts to predict once you understand them. For instance, the tissue immediately labial to Point B does not change essentially after the age of six, but it may move upward or downward with treatment.

Two different methods of forecasting are now used. One is during the treatment time or short term and is used for mechanical anchorage planning. It is the projection of established architectural lines in the skull and jaws over which are superimposed the effects of treatment.

Three conditions are taken into consideration in this procedure, which he at one time labeled “synthesis” in order to separate it from

analysis, and which Holdaway later called the VTO, or “visualized treatment objective”.

The primary condition to consider is natural growth of that individual for the usual course of treatment (Two to three years.)

Secondly, the probable physiologic rotation of the mandible resulting from the mechanics is taken into account. This is superimposed over the natural growth that would be expected and the type of treatment which makes a difference in the prediction. It is calculated in light of the needed change in molar correction of overbite and overjet, convexity of the profile after extraoral forces, by heavy intermaxillary traction or activator treatment.

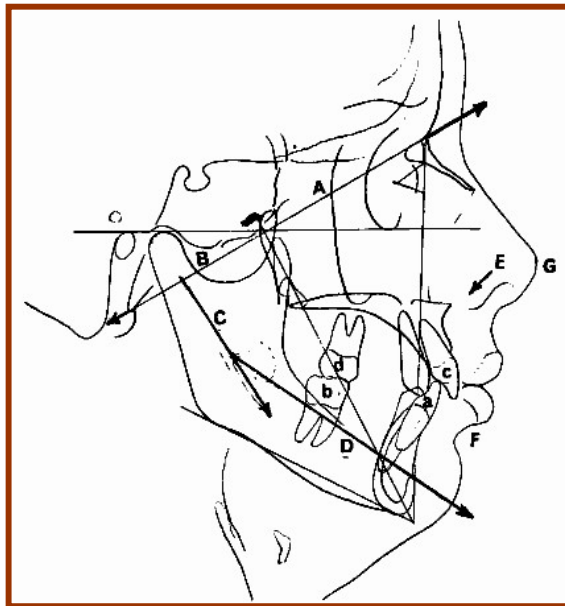


Fig. 9

Fig. 9 Steps and sequences in short route procedure of forecasting. Anterior and posterior increases are estimated.

A = 0.8 mm

B = 0.8 mm

C = 0.8mm

D = 1.6 mm (double the C)

E = is elective as decided by operator.

F = soft tissue is dependent on tooth movements

G = is dependent upon ANS and is 1.0 mm yearly

Teeth Sequence:

a-- lower incisor is + 1.0 mm to APo with CD = + 2.0 mm.

b--lower molar as determined by anchorage needs of d c.

c-- upper incisor change as needed from lower incisor

d-- upper molar = 3.0 mm distal to lower in normal occlusion

Each type of treatment has its own share in the prognosis of the short term skeletal change of patient.

The third factor is concerned with the actual objectives in movement of the anterior teeth. Lip functions change with tooth movement. Tonicity and character change remarkably with treatment. However, the original methods for anticipation of changes that he devised in 1950 are still the same today.

Now, long range prediction is another case. Over a period of time, natural growth rebound and physiologic recovery are experienced after treatment. This method reveals the anchorage available in the lower and the tooth movement needed in the upper to determine anchorage requirements.

- **Enucleation of third molar.**

He has practiced lower third molar enucleation in about 100 cases. With a long range forecast, he projected the mandible of the child all the way to his prospective maturity. The occlusal plane and erupted position of the lower first molar are included in the mandibular prediction. This means that we can be relatively sure how much space is going to be available posterior to the first molar if we do nothing.

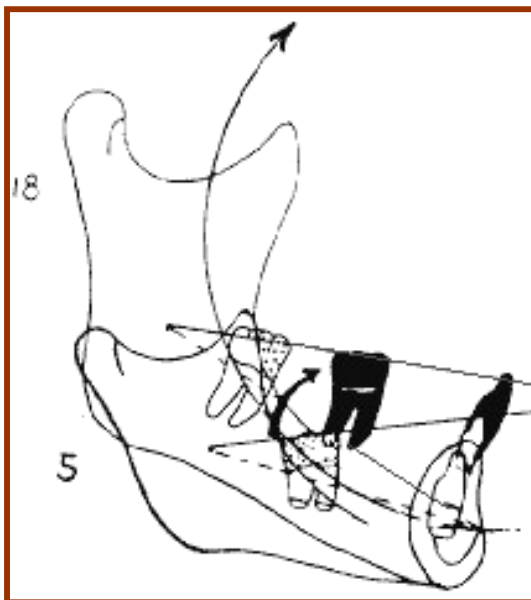


Fig. 10

Fig. 10 *Arc of growth as theory of superpositioning reveals the lower arch to develop upward and forward making space for the second and third molars. Some remodeling may take place, but average implant studies show a curve only slightly more open than shown here. Note space for lower third molar is favorable as long as as 50% of the teeth are forward of the external oblique ridge.*

Problems arise clinically in the posterior area, particularly in the lower arch during orthodontic treatment and sometimes without treatment. He states that as we intrude lower incisors with a utility arch, we push them downward into a stronger portion of the lower lip, and the lip resists their forward movement. The result is the lower molars being moved backward and over the top of a developing lower second molar. The third molar lies over the top of the distal margin of the second molar and now traps the second from front and back. Now, with the diagnosis from the long range forecast and with the prospects of this kind of treatment, we arrive at the amount of space that will be available for the second and third molar by maturity with a given treatment, or no treatment. When the prognosis of the

third molar is less space than 50% behind the external ridge, he recommends its removal.

The anatomy of the developing follicle of the lower third molar shows that it is an open bony window on the lingual aspect of the mandible.

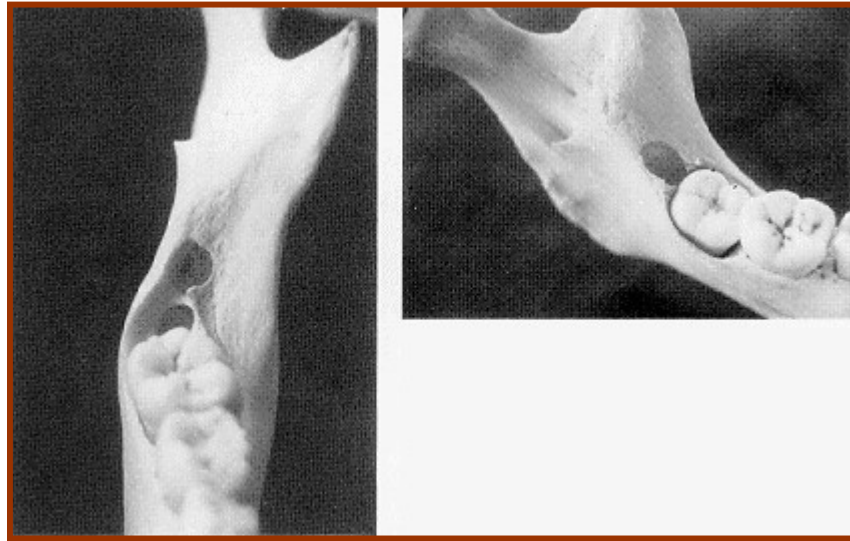


Fig. 11

Fig. 11. *Two views of developing crypt for the lower third molar, showing the open follicle on the lingual side of the ramus at the retromolar recess. Development level about age 9, but this stage may come in a range from 8 to 12 commonly.*

He contemplated this situation for a long time, and finally concluded that the only thing to do was to go in and spoon out the follicle. Dr Ricketts said that with the discovery of an arc as a working principle for the growth of the mandible, he was coming close to the true meaning of the word prediction.

The objective is “to foretell the future”, to master the unknown and escape the bondage of bewilderment.

A FOUR-STEP METHOD TO DISTINGUISH ORTHODONTIC CHANGES FROM NATURAL GROWTH

Cephalometric setups have been used by Dr Ricketts for determining the most appropriate objectives for each patient. By visualizing the conceivable result beforehand, precise plans for the skeleton, teeth, and soft tissues have been devised. In addition; desirable results and certainly better understanding are thought to be achieved through the use of “prediction” methods. All the skeletal changes, or even the physiologic changes that may take place during treatment, may often be referred to as “growth”. This is because physiologic change, treatment change, or growth change cannot be sorted out with any degree of assurance with most cephalometric methods.

Observations of Problems in Cephalometric Planning

Due to the proximity of the upper jaw with the anterior cranial base, and with the reliance that most clinicians place on the Sella-Nasion line, the principal focus in diagnosis and planning has often first been the midface. It followed directly that an attack on Point A and the maxillary arch had the primary attention in planning. With this thinking, clinical cephalometrics became reduced to convexity change or SNA-SNB difference, and the alignment of teeth in the profile and mandibular behavior were secondary, as prediction of mandibular behavior was estimated by the extension of the cant of the mandibular plane angle. No differentiation was taken into account between measurement from Frankfort plane and other cranial planes with common methods. Often, not even the same points on the mandible were selected in different analyses.

For the most cogent view, the BaN plane is recommended by Dr Ricketts.

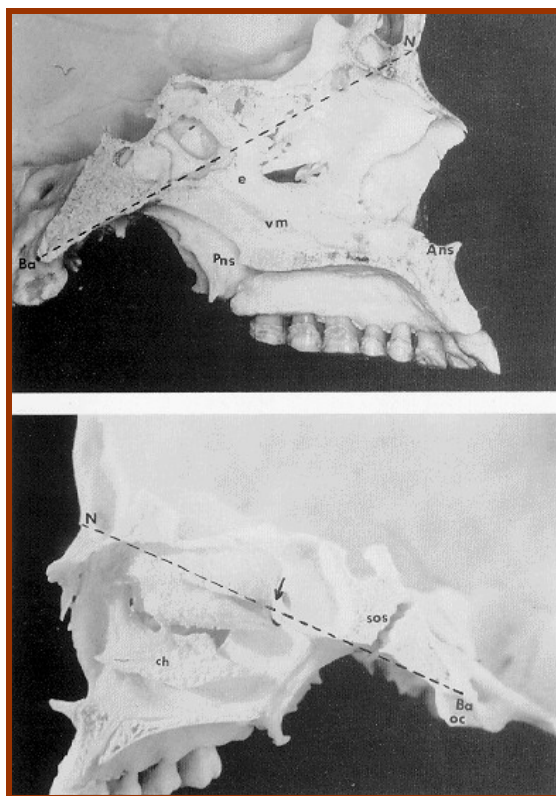


Fig. 1

Fig.1 a.(above) A skull at midsagittal section showing basilar portion of occipital bone and frontonasal suture area. Basion (Ba) is located on the anterior rim of foramen magnum at vertex of the angle of the clivus and nasopharyngeal roof. Nasion (N) is located at margin of nasal bone at the frontal junction. The connection of Basion to Nasion (BaN) forms a line of separation of the face from the skull and hence a basicranial axis for growth and structural reference. Note also the position of the vomer bone (vm) and junction with the ethmoid plate (e). Note anterior and posterior nasal spines (Ans-Pns).

a.(below) For orientation of those facing the x-ray to the right. The same section as above in an eight-year-old specimen. Basion and Nasion will be noted. Note also the wide sphenoid-occipital synchondrosis area (sos) separating the sphenoid from the occipital bones. Note the turbinates or conchae (ch) on the lateral nasal wall.

As early as 1950 with the viewing of Basion in laminagraph sections, Ricketts suggested that Y axis changes could be measured more

usefully from the Basion-Nasion plane. But, it was still difficult to determine, in some instances, whether a part of the change was a change in the position of Sella, or actually a change in the chin. It was shown that the cranial base angle, while constant on average, did exhibit a change of 5° in either direction over a three-year period of time. So, at least twenty years, there has been doubt and there has been room for skeptics with regard to the nature of orthodontic superpositioning, and consequently with the interpretation of results.

Position One

Three points are required for the cranial reference for this skeletal analysis. These are Basion, Nasion, and Pterygoid Point. Basion-Nasion super positioning has been considered to be the most trustworthy longitudinal base line.

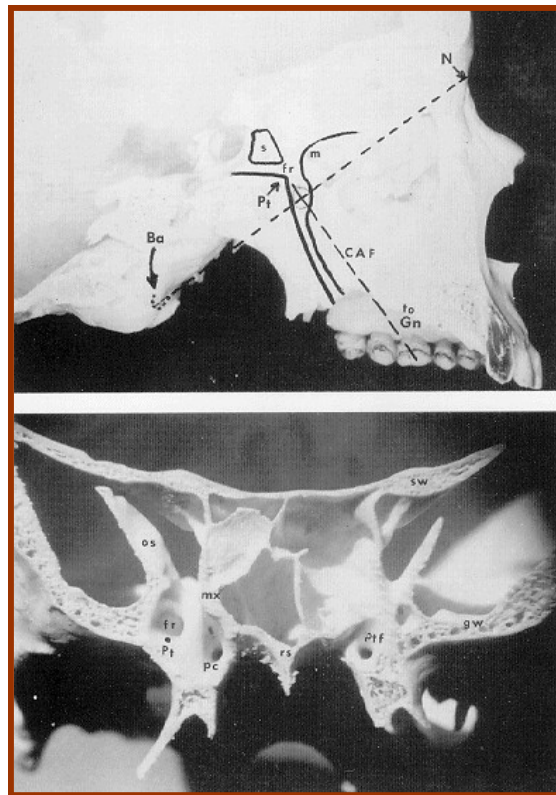


Fig. 2

Fig.2 The centre of the BaN plane, which is located near the rostrum of the sphenoid but also the top of the pterygopalatine fossa or the lower border of foramen rotundum, is near the center of the facial superstructures. A point was selected on the lower lip of the foramen rotundum (Pt) which is not to be confused with the pterygomaxillary fissure (PTM) which is located at the junction between the pterygoid plates and the tuberosity of the maxilla (Fig. 2 **a. (above)**) Section of skull at center of pterygoid plates through foramen rotundum (fr). Note channel entering the pterygopalatine fossa. Pterygoid point (Pt) is located at crest of bone at lower lip of foramen. Note its close relation to a center of BaN. This point is thought to represent the closest point and orientation to a center of least growth for serial reference. The Central Facial Axis represents the center of the cone of the face (CAF). Bone at base of orbital sphenoid (s). Top of maxillary tuberosity (m).

b. (below) A slanted frontal section through anterior margins of pterygoid plates showing foramen rotundum (fr). Lower and medial foramina are pterygoid canals (pc). Note the relation of the Pterygoid points (Pt) to the rostrum of sphenoid (rs). Note also large sphenoidal body and sphenoidal sinus. Note orbital sphenoid (os). Note small wing of sphenoid (sw). Note great wing (gw.)

By taking the lower lip of the foramen rotundum, as seen in the lateral film, the point has been described as pterygoid point (Pt). This point is used as a reference center (least change) and has taken the place of point Sella for longitudinal comparison.

A line from Pt to cephalometric gnathion (GN), selected at the intersection of the facial plane and mandibular plane, constitutes the Central Axis

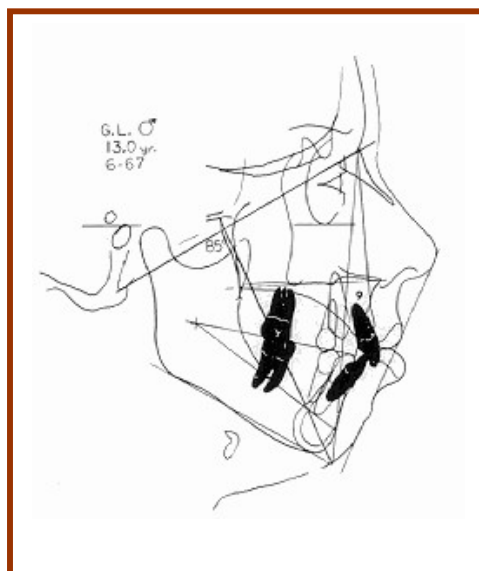


Fig. 3

Fig.3 Time 1 Case G. L., male, age 13.0 years with severe bimaxillary protrusion of the dentition. The diagnosis and treatment plan called for extraction of all first bicuspid with Grade 3 anchorage preservation on a scale of 4. Also, light anterior parietal extraoral traction was indicated by the forecast. Note Central Axis at 85° and other key reference lines for longitudinal analysis. The convexity was 9 mm. The lower lip protruded 7 mm from the E plane)

The Central Axis, for morphologic or skeletal static description, forms almost an absolute right angle to BaN for the average of the population as a whole. This is a very interesting fact in itself, as the clinical deviation (CD) of morphology is ± 3 degrees from the 90 degrees. It was found to be 90 degrees. Central Axis, however, can change in the

individual. As much as 6 degrees of change has been noted during the transition from the mixed to the permanent.

Position Two

Given the same Basion-Nasion plane, now the tracings are shifted to Position Two (at Nasion)

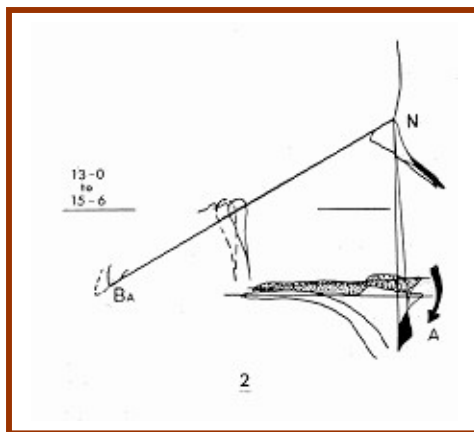


Fig. 4

Fig.4 (fig4 For the maxilla) The tracings are shifted on the same BaN plane to register at Nasion. This orientation shows a backward movement of Point A of 3.0° during treatment to help reduce the convexity. Some high pull extraoral traction was employed to the anterior teeth and only moderate effect is seen in the anterior nasal spine. If extraoral cervical traction had been used. Much more effect on the palatal plane would be seen. Note the nasal bone continued to move forward slightly. With vigorous cervical traction this is also reversed.)

The Basion-Nasion-point A angle is used, which corresponds to the SNA angle of Steiner The Ba-N-A angle is nearly an absolute constant without treatment This angle (measuring approximately 66 degrees) changes very little in the population growth samples, but furthermore, changes very little in the individual. The standard variation in a five-year period was found to be only ± 1.0 degrees. As this is reduced to yearly increments, .5 degrees becomes the practical variation for yearly increments. Minor changes are frequently manifested by the protrusion or

retrusion of the central incisor with local modification in the area of Point A as the cause, rather than a change in the basal maxillary position. Given another 0.2 degrees change for error, the hypothesis is that less than one-half of 1.0 degree change would be expected to occur naturally.

The constancy of this angle largely says that Point A essentially behaves with Point N. As N moves forward, A moves forward, and if N does not move forward, A does not move forward. The behavior of Nasion on the basal axis from PT area is 0.7° per year $\pm 0.26^{\circ}$. This would seem also to say that the protrusion of the maxilla is also consistent with a carrying forward of the bony superstructure in the area of Nasion. Ricketts believes this to be essentially so. At any rate, with this low standard deviation of change, the clinician can literally take absolute credit for most change in Point A that takes place during treatment, when measured with this method of superpositioning. It makes little difference whether it is on a short range or on a long range point of view. However, a distinction is needed to determine Point A change on a local alveolar basis or complete maxillary change by skeletal involvement which will be done later with Position Three.

Position Two therefore depicts the position of the maxilla and serves as a guide for diagnosis and further for treatment planning.

Position Three

Position Three employs the original method of Brodie and Downs with no differences in technique. The ANS and PNS is superpositioned (Palatal Plane) and registered at ANS (Fig.5 Position Three. For the upper teeth) Tracings are superimposed on palatal plane and registered at ANS.

Note the intrusion and backward movement of the incisor of almost 7 mm. The incisor without treatment would continue to erupt downward and forward about 1 mm during this time span. Remodeling of alveolar bone will be noted in the incisor area as Point A moved backward about 2 mm to explain major portion of convexity change. Note the upper molar almost 2 mm forward. However, the molar would have moved forward at least 1 mm during this development with the loss of the second deciduous molar and normal eruption.)

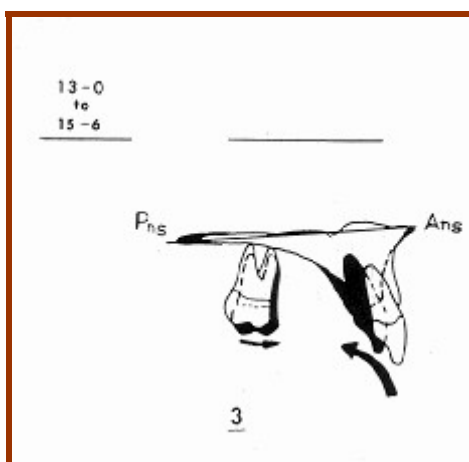


Fig. 5

While it has been shown that the descent of the palate is not all due to growth at the sutures, but is also accompanied by remodeling resorption, the palatal plane still serves as the best parameter for the assessment of maxillary denture change. Superimposed in this manner, the upper dental arch erupts downward and makes a slight forward gain of about 0.2 to 0.3 mm per year in terms of its position on the maxillary denture base.

With the natural tendency, and a low deviation of change of the upper incisor, the stability is also quite remarkable. Therefore, any change in the molar forward or backward, or the incisor forward or backward

during the course of two years, can be claimed essentially as being effected by the orthodontist rather than natural growth because a change of more than 0.4 mm in two years is unlikely unless the incisors protrude between the split in the lips.

Some minor exception can be taken to the foregoing hypothesis as space for the missing upper second deciduous molar is encountered. This also can be claimed to be an effect of tooth loss and is not a natural phenomenon in the presence of a full complement of teeth. By determining the changes in Point A from ANS, the amount of change in the maxilla can be verified in Position Three. In the case of G. L., the upper incisor tip moved upward and backward 6.0 mm, all of which is considered in the method to be due to treatment. The upper molar crown moved forward almost 2.0 mm, of which 1.0 mm was probably due to treatment.

Position Four

Position Four will require the learning of two new points and two new planes

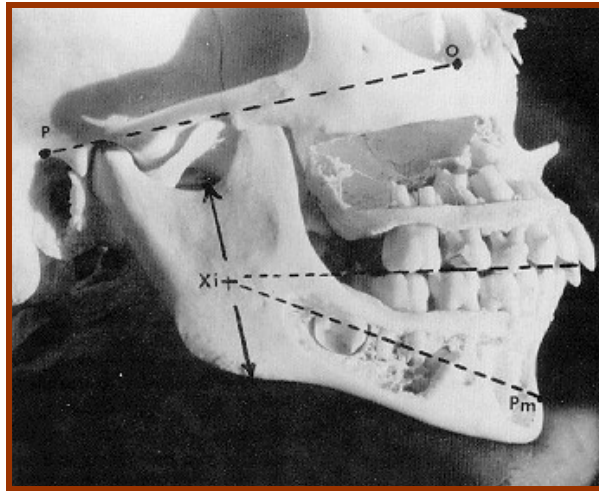


Fig.6

Fig. 6 Prepared skull of a mixed dentition subject showing a new method of orientation on mandibular points for the study of occlusal changes. Pm is located at crest of bone at the mental protuberance at point of start of recess on anterior contours. The centroid of ramus is selected at a common point by measuring minimum height and depth of ramus and was labeled Xi point. The connection of these two points is called the corpus axis. The occlusal plane is drawn through the plane of the buccal teeth and called the true occlusal plane. The angle between the occlusal plane and corpus axis tends to be highly stable. Note Porion and Orbitale.)

First, a point at suprapogonion (Pm— Protuberance Menti) was found necessary because a point at Pogonion on the anterior-most border of the symphysis cannot be depicted as a definite point in the vertical plane. Therefore, a point was selected at the mental protuberance and termed Pm. It was selected at a point at which the outline of the chin starts to recede in the profile, or at the top of the crest of the bony cortex in the outline of the symphysis in the area of the mental protuberance. This area has been shown by numerous investigators to be a location of least change. No

apposition or resorption or remodeling seems to take place at this site. It is the most stable point of reference for longitudinal comparison on the chin that the author has been able to determine.

It was found by Bjork that the lower border of the gonial angle resorbs in the usual growth pattern. This would say that the measurement of tooth eruption from the mandibular plane would not in fact be a measure of eruption, but also resorption of the lower border must be taken into account. Therefore, the mandibular plane is not a trustworthy reference for tooth eruption or tooth change.

As an alternative, a second point which represents the centroid of the ramus was located and labeled "**Xi**" point. This point was selected by measurement on the mandible, and is located at a halfway point between the lowest point of the sigmoid notch and a point immediately inferior to it on the lower border of the ramus in the Frankfort horizontal orientation (Fig. 6). (Also midway on the minimum depth of the ramus.) The Xi point also proved to be a strong biologic point which represents the mandibular foramen and the center of rotation of the mandible. The connection between Pm and Xi formed a plane and was termed the "**Corpus axis**".

The true occlusal plane was drawn through the bisection of the buccal tooth overlap. Ironically, the extension of this true buccal occlusal plane passes closely to the Xi point in a remarkably high percentage of cases. The angle between the occlusal plane and the corpus axis was noted to be among the highest correlated of all the measurements subjected to computerization. This would seem to make it useful for superpositioning (and for prediction as well). With this angle used as a yardstick, any change

in the occlusal plane from the corpus axis would, therefore, be essentially a change brought about by treatment. The standard variation is 0.68 degrees each year.

The lower molar tends to erupt straight upward from the corpus axis registered at PM at a right angle to the Frankfort horizontal as the whole occlusal plane moves straight upward, and the occlusal-corpus angle remains almost constant. The lower molar and lower occlusal plane erupts about 0.8mm per year upward from the corpus axis. Likewise, the lower incisor moves directly upward from the corpus axis as arch length changes are not usually encountered. However, the lower incisor also seems to hold to the APo plane on average. The loss of the lower second deciduous molar also adds about a 1mm shift to the normal forward tendency. Therefore, a forward or backward measurement from these points on the occlusal plane may serve as excellent parameters for the evaluation of tooth movement in the lower arch.

Four points of superpositioning were recommended by Dr Ricketts for evaluation of treatment results. These four positions, based on characteristics of natural development were presented to serve as a guide for the methods of comparison during treatment.

THE EVOLUTION OF DIAGNOSIS TO COMPUTERIZED CEPHALOMETRICS

In the early days of orthodontics, the patient constituted the only record. The clinician could only observe, describe or measure directly for records, because at that time even the plaster model had not been developed. Progress was painfully slow; information was accumulated only with great effort and was of questionable reliability.

The primary concern and aim of treatment was alignment of teeth in the individual arch. This was essentially limited to the upper arch, because that arch was the most obvious. The objective for alignment of the teeth was caries prevention, because it was thought that broad cervical contacts of the teeth were conducive to decay. In addition, it was recognized that imbrication "marred" the beauty of the smile.

However, other factors began to be considered and more adequate appraisals were needed consequently diagnosis became more involved and better records became necessary.

Evolution of objectives

In order to explain contemporary objectives in orthodontics, Dr Ricketts had divided orthodontic history into five general eras. It was seen that added goals in treatment evolved in each era; hence, diagnosis for the consideration of these objectives became more complex. The five eras were

1. Pragmatism— up to about 1875;
2. Empiricism— 1875 to 1925;
3. Experimentation— from 1925 to 1950;
4. Scientific theory— from 1950 to 1965;

5. Cybercultural communication— 1965 to the present.

Twelve objectives or considerations in orthodontics have developed over the course of this evolution as knowledge and responsibility have grown.

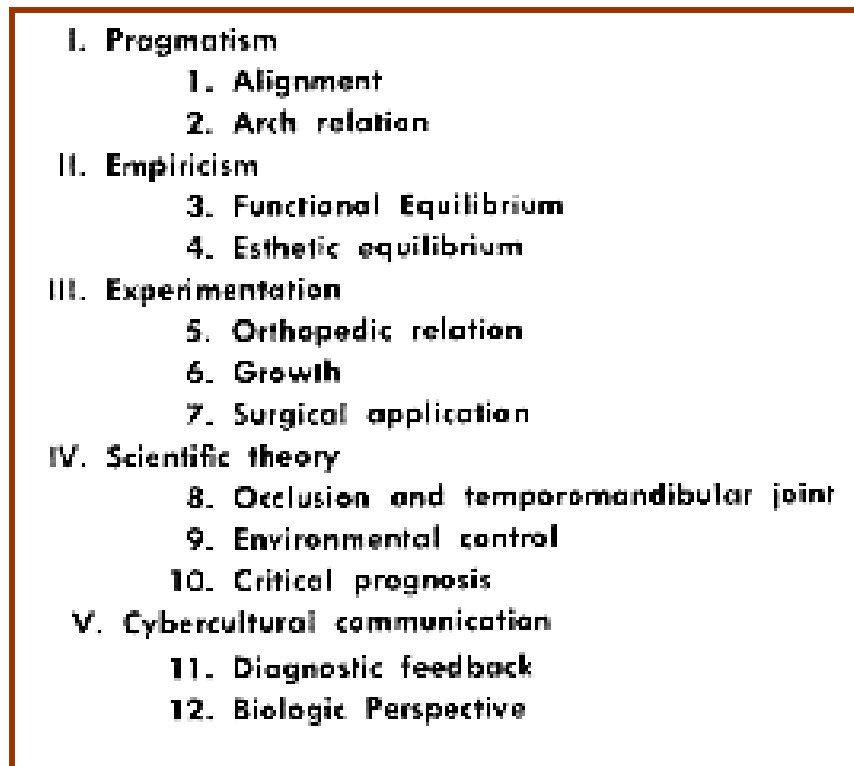
- 
- I. Pragmatism**
 - 1. Alignment**
 - 2. Arch relation**
 - II. Empiricism**
 - 3. Functional Equilibrium**
 - 4. Esthetic equilibrium**
 - III. Experimentation**
 - 5. Orthopedic relation**
 - 6. Growth**
 - 7. Surgical application**
 - IV. Scientific theory**
 - 8. Occlusion and temporomandibular joint**
 - 9. Environmental control**
 - 10. Critical prognosis**
 - V. Cybercultural communication**
 - 11. Diagnostic feedback**
 - 12. Biologic Perspective**

Fig. 1. *Eras in orthodontics.*

Pragmatism

During the early period, treatment and diagnosis were pragmatic and two main objectives emerged.

Objective 1

Ricketts mentioned first objective as “Arch Allignment”. As mentioned above, the aim for straight alignment was the first goal and expansion of the arch was the procedure. As evidence of this limited objective, the earliest appliances were characterized by Fauchard's "bandalette" and other forms of

labial arch to which the teeth were simply ligated outward. Other forms of appliance evolved with screws or springs designed to push the teeth outward from within.

Objective 2

“Correction of arch relation” was the second objective given by Ricketts. Some earlier writers mentioned the need for approximation of the arches to each other, but it was not until Kingsley gave substance to the idea of arch correction by his bite-jumping procedure that arch relation became a distinct diagnostic factor. Extraoral traction was recognized but was principally employed for the purpose of upper anterior tooth retraction or for chincaps for cases of prognathism.

Still, the patient was the only record. The era was still pragmatic, as the ends were thought to justify the means, and the diagnosis of irregularity and bite relation were the two basic considerations.

By the middle of the 1800's, trays had been perfected and models were made of plaster, mostly from wax or compound impressions. Plaster impressions also came to be employed, but the plaster cast brought with it a simplified classification of malocclusion with the description of normal occlusion by Angle.

Era of Empiricism

The advent of the plaster cast and the knowledge of a useful, simple method of classification changed the course of diagnosis and treatment. Teeth were observed to be inherited in sets and each tooth seemed to be important to the whole to the minutest detail. Arch length became a concern and certain indices were proposed, such as the Pont index, for the prediction

of proper arch size and form as based on tooth anatomy alone. The slow development of knowledge and the setting of certain hypotheses yielded an era of empiricism which was to extend through the first quarter of the 1900's.

Diagnosis came to be made from the upper molar because it was hypothesized that this tooth was the least variable and the most stable and reliable single entity. The art portion was formed and the model was trimmed to stand occluded on the desk for viewing and study, usually related to the occlusal plane. Treatment planning centered on molar occlusion, as did most of diagnosis.

Objective 3

Ricketts mentioned third objective as "Functional equilibrium". Time revealed other problems and diagnosis became extended. It was found that the arches could be aligned individually and could be corrected to each other, but the whole mass was often functionally incompatible or occlusally unstable. The search was on for functional equilibrium. Muscle action and the functional realm became an added dimension. It was at this point that orthodontics became a specialty and an independent science. Its problems in this regard were not directly germane to dentistry in general.

The problem of diagnosis in any branch of medicine has always stemmed from etiology. In all clinical problems, the combined elements of heredity and environment must be considered as underlying causes. The role of heredity continued to emerge to the orthodontic clinician, who noted the similarity between siblings and similarities of offspring to their parents. However, conclusions without profound investigation were loose and the

principal cause of a malocclusion was frequently claimed to be one of abnormal function or at least in some manner connected with environment. In fact, this whole era might be typified as the age of functional morphologists by Ricketts.

Objective 4

Ricketts objective four was “Esthetic equilibrium”. In addition to function and from the earliest time of concern in orthodontics, esthetics was a question. A strictly empirical procedure was followed and most of the decisions on facial art were value judgments. Nothing concrete in esthetics was accomplished in this era, although scholars pressed for an acceptance of variation. The photograph was employed loosely for diagnostic purposes. Angle was the strongest of advocates of the preservation of the full complement of teeth, but he held Appolo Belvedere as an ideal in facial beauty and harmony in spite of the fact that this model possessed a "flat" type of denture.

Case championed the cause of facial esthetics and even extended his study to the cast of the soft tissues of the face. Case concluded that bimaxillary protrusions existed and that the interests of esthetics were best served by the judicious extraction of teeth in patients with delicate structure, large teeth or tight limited musculature. At any rate, these arguments served as a steppingstone in progress, and new dimensions were added to diagnosis.

Era of Experimentation

With the first four objectives as a background, other aspects of diagnosis began to take shape. Because hypotheses were set and efforts to prove a theory developed, the second quarter of the 1900's was called the era of experimentation by Ricketts.

Objective 5

The fifth objective by Ricketts was “Orthopedic jaw relationship”. The first movement was the growing concern of basal bone relationships. Anthropometric measurements were obtainable but, in order to orient the casts as observed in nature, a technique of gnathostatic orientation was developed. This technique revealed the cant of the denture related to the Frankfort plane and disclosed abnormal skeletal relationships. In effect, this introduced the problem of orthopaedics because the denture was related to the orbit and brought skeletal structures into the consciousness of the orthodontist. Thus, orthopaedic relation became a point of direct concern in diagnosis and treatment. The stage was therefore set for measurement of the head with the x-ray.

Broadbent, using the principles of the anthropometric cephalostat, constructed a cephalometer or head-positioning device. He employed ear rods in order to obtain oriented standardised head films that were trustworthy in accuracy and reproducible in the same patient at a later date. As a carry-over from gnathostatics, the orbital plane was erected from the cephalometric tracing which corresponded to the gnathostatic cast orientation. Thus, orthopaedic relation of the jaws was describable by the x-ray technique and facial typing became a consideration in diagnosis.

Objective 6

“Growth utilization” was the sixth objective by Ricketts. The cephalometric method itself served as a tremendous catalyst to the profession and among the investigators, giving rise to a dimension in diagnosis that had formerly been only assumed growth .

Growth came under scientific scrutiny by means of capabilities of measurement. The fourth dimension, the dynamics of induced change or growth was added to diagnostic criteria.

Among the early hypotheses developed in this period was that of the stability of the growth pattern by Brodie. The findings and conclusions regarding growth led investigators to cast doubt on many of the prevailing ideas of previous conclusions and gave heredity a strong boost as the major etiologic factor in diagnosis. Thus, Ricketts concluded that not only the basal relation of the jaws became a part of diagnosis, but also the base of the skull and the housing or origins of the jaws were shown to be important.

Although proposed primarily for the study of growth, the cephalometric x-ray method proved to be the orthodontic clinician's most useful tool for morphologic and functional diagnosis.

By 1940 Brodie's original findings had suggested orderliness to growth and this was interpreted as a stability of the growth pattern. Therefore, stable morphology and proportion were expected to be present and were thought to prevail.

Concomitant with these investigations was the clinical work of Tweed. He recalled patients treated earlier and was disappointed with relapses. He also focused diagnosis away from the molar and placed it on the lower incisor, and he used the split cast to demonstrate and to teach his clinical theory. He concluded that the lower incisor was to be placed directly over the bone of the symphysis and, therefore, diagnosis must include the lower incisor as a starting point. This was an important shift in diagnostic procedure.

Objective 7

Ricketts mentioned objective seven as “Surgical application”. Diagnosis and treatment of the orthopedic relations characterized this period. Although principles of growth had been established, understanding of the growth of the individual patient was still rather nebulous, and some began to doubt the conclusions of certain studies which had emerged. In addition, a third consideration to be reckoned with was the effect of surgery related to orthodontics or problems of occlusion. Because it was suggested that growth of the maxilla was altered following cleft palate surgery, the kind and extent of the surgery itself became a factor in diagnosis. He also said that, surgical procedures were developing for the correction of mandibular prognathism. Diagnosis of the need and consideration of surgical osteotomies for the treatment of Class III patients was promulgated at this time.

Ricketts noted that all three major diagnostic criteria prevalent in this era (that is, orthopedics, growth, and surgical application) were propelled into significance mainly through the tool of cephalometrics. Brodie maintained the outlook for preservation of all the teeth to achieve harmony with maturity, while Tweed influenced by the conclusions of Case and his own personal experience, followed esthetic grounds to a much "flatter" profile than that accepted by Brodie. The whole subject of esthetics remained controversial.

Era of scientific theory

This was the climate for the post-World War II period. The foregoing experimental era had brought the basis for a host of cephalometric measurements and schemes for analysis. In that field, Downs' analysis was the most notable, as he reduced the total skull pattern into the basal skeleton

and the denture components. He added classification of the facial structure to the previous dental classifications of Angle. Other analyses, such as that of Steiner, focused mainly on profile relations but included other morphologic features. Bjork developed a concept of facial patterns following phylogenetic and craniometric observations and discussed the implications of growth. Theories were proposed for treatment based on cephalometric measurements, and standards for successful orthodontic results came to be narrowed and refined.

Objective 8

Occlusion and temporomandibular function was the eighth objective by Ricketts. This era was typified by the addition of three more objectives or at least the crystallization of ideas which had been generated before. One concern was the subject of occlusion.

Detailed impression materials, high-speed cutting and wider use of anesthesia brought an awareness of the proper treatment and preservation of occlusion to the forefront, and oral rehabilitation had become almost another specialty. Bite registrations were sought, and posture of the condyle in the fossa was investigated. Description of normal inclined plane relations had been presented by Angle and others, but the dynamics of function and the role of dental articulation, particularly the role of the canine became points of inquiry. In addition, the temporomandibular joint had been a "blind spot," and its importance was revealed by cephalometric laminagraphy in studies by Ricketts. The physiologic rest position, the lever action of the mandible, pathologic changes or adaptations of the joint and terminal hinge position were studied.

Behind this functional idea emerged the entire field of kinesiology as

applied to dentistry. Contributions of the teeth to the entire kinetic chain of the posture of the head were recognized and emphasized by Brodie. The denture came to be studied in all three planes of space; consequently, the posture of the head itself was related to occlusion. The teeth were looked upon as having a much broader purpose than simply chewing. It was no longer an issue of anatomic occlusion it was a problem of dynamic occlusion with proper vertical dimension and normal respect for condyle fossa relations.

Thus, in diagnosis, areas far removed from the teeth came to be matters of concern. Diagnosis was expanded to analysis of the muscle and neuromuscular systems. Function of the lips came to be related to problems in bite function.

Objective 9

Ricketts ninth objective was “Environmental control”. The scientific theory era also brought renewed interest in the environment as an etiologic factor. Heredity had come to be regarded as the primary and most important factor in etiology, but it was recognized that man always will be "bombarded" by his environment. The adverse factors in environment became problems in diagnosis to those who studied their patients carefully. Environment usually was considered to be involved with function alone, but the total aggregate of environment was noted to include hormones, climate, nutrition, disease states and psychologic states as well as the physical forces on the teeth by function or habits. Certain of these environmental factors which could be controlled within limits became a part of usual differential diagnosis. Diet was important for control of caries, as well as the practice of fluoridating the teeth. Dental hygiene was a factor in health of the soft

tissues. Prolonged systemic diseases were limited, but allergies were common and influenced treatment and results. Psychologic states or temperament were often a part of habit patterns and, for the most part, habits detrimental to the development of occlusion required direct diagnosis. The respiratory tract loomed as an important diagnostic consideration. Particularly, the tongue and lip function constituted important factors for concern. Mandibular posture, chewing patterns and even conditions caused by mimicry became significant. Therefore, control of the environment as an objective and the role of environment as a diagnostic factor emerged strongly in a new light.

Objective 10

“Critical prognosis” tenth objective by Ricketts. Diagnosis contains an element of prognosis because the decision reached regarding the nature of a condition includes that which will happen if nothing is done. Developments therefore caused a critical prognosis to be taken into consideration, which meant extensive and complete diagnosis as a basis.

Details thus were added to cephalometric analysis. This included the cranial base, cervical vertebrae, glenoid fossa, characteristics and locations of the individual components of the facial complex, such as the upper and lower jaws, together with the nasal cavity. The functional dynamics of the mandible were considered as well as soft tissues in speech, breathing, and deglutition. Conditions of esthetics were taken beyond strict subjectivity as normal and abnormal lip and mouth relations were described.

Cephalometric films of patients treated with extraoral traction began to suggest skeletal changes in the midface which were beyond the usual. Not

all cases which appeared overexpanded in treatment were observed to relapse. Some grew better and some worsened with maturity. Because of this variety of behavior, men began to take a closer look at the mechanisms of growth in the face. Direct application of the vectors and gradients of growth was sought and the idea of critical prognosis or prediction assumed utmost importance. The tool again was cephalometrics. The behavior of the patient had to be estimated in the light of the treatment itself.

Certainly, the orthodontic model alone was inadequate for diagnosis. Even the description of orthopaedic relation added to model diagnosis was inadequate for complete analysis. The projection of growth, together with the prognosis of orthopaedic and soft-tissue change, became the frame of reference for diagnosis and hence prognosis. The method became controversial in view of the biologic nature of the situation.

Diagnosis was becoming involved and complicated. Many measurements were proposed which became confusing. The tracing of films and the erection of lines and planes of reference was time consuming. Men failed to analyze their patients routinely. The analysis was technical, and the tendency grew for the clinician to gloss over the details or simply to leave detailed analysis and prognosis undone. It was obvious that help was needed for sophistication in contemporary diagnosis. It was only natural to turn to advances in technology in the broader spectrum of science for this kind of assistance.

Era of Cybercultural Communication

The head film lent itself to optical scanning and graphic display for accurate and reliable measurement. Thus, the head film (both the lateral and the frontal views) offered a practical use for the computer. The computer had

been employed to describe, digest and store prodigious amounts of information in the form of data. This information concerning all aspects of diagnosis from all sources in addition to measurements from the head film, was subjected to advanced equations and answers were supplied with lightning speed. Once this kind of procedure was perfected, older methods became quickly outmoded and crude by comparison. All that was needed was for the combined disciplines to put it together.

Objective 11

Ricketts eleventh objective was “Diagnostic feedback”. Information once was stored only in the brain of the individual clinician and was limited to his own personal experience with treated cases. Now, through the computer, a practical experience could be extended to virtually the total population. Information was gained through the cooperation of orthodontists and general dentists all over the world who would apply their patients' records to this development of advanced technology. This meant that knowledge or a basis for judgment was extended in manifold fashion, as the feedback to the clinician was enormous by comparison with his limited personal contact and private practice.

Objective 12

The last objective by Ricketts was “Biologic perspective”. Man, in this cybercultural era, lived in a period of total involvement and instant communication. In the cybercultural era was a need to consider man in a total biologic perspective. Automation and computerization can supply the professional man with information of a quality and quantity which heretofore has not been possible to accumulate.

This frees the clinician to evaluate man in his complete needs and to

prescribe to those needs in keeping with respect for the dignity of each individual in an age when individual identity is in serious jeopardy.

Summary

The thesis here was that orthodontics has moved beyond the pragmatic and empirical level and has become a profound science. This evolution was traced through twelve major objectives that have emerged throughout orthodontic history. Progress has been and is being made by cephalometric computation. The cephalometric x-ray is employed to describe skeletal and denture conditions in an accurate, critical manner. In a similar vein, statistics are employed to describe measurements and data for improved understanding. The development of electronics has improved processes of communication to formerly inconceivable levels. It is to our great advantage that all of these developments in technology would converge and be put together for man's common good in the computer.

Ricketts concluded that the clinician could benefit best from the computer by understanding the function of statistics, the function of central tendency, and the expressions of normal and abnormal variation. This yields a more profound basis for judgment, increases in confidence and extends the depth of perception in diagnosis.

PERSPECTIVES IN THE CLINICAL APPLICATION OF CEPHALOMETRICS

Dr Ricketts had mentioned the perspectives in the clinical application of cephalometrics in the following phases:

First Phase

Roentgenographic cephalometry has made an increasingly notable impact on clinical orthodontics over the past decades. The first movement initiated by Broadbent as the method developed was for serial study alone. This idea was embraced by Brodie and almost 30 years later, at the second cephalometric workshop, these two still held out for its application to be solely for longitudinal studies, rather than clinical diagnosis.

In the same era both Hofrath and Maves, who had developed “teleroentgenography” concurrently with Broadbent, were prescribing this for prosthetic planning and for following operative procedures. Thus, planning of treatment and monitoring of change were inherent potentials of the tool from the beginning and many new applications have continued to emerge.

It is quite clear that the most significant applications of the cephalometric radiograph have been in clinical orthodontics. Fifty years after its inception, it is the standard procedure for the overwhelming majority of the orthodontists.

Second Phase In Clinical Application -Points And Planes

The second major movement was a concern among investigators for establishing reference bases for description for morphology as well as for

longitudinal comparison. Broadbent used the Bolton Triangle with “R” registration, while Brodie and Bjork concentrated on Sella-Nasion and the anterior cranial base. Tracings were used by Brodie and his colleagues to study treatment result in the 1930’s, culminating in 1938 report. Downs used that information to choose or select that treatment for the individual pattern.

In those years Tweed and his followers were already advocating extraction and they were bent on placing the lower incisors over basal bone. Cephalometrics was an obviously useful method for evaluation of the position of the lower incisor relative to symphysis. The mandibular plane soon became plane of reference for planning, much to the consideration of conservative fraction.

Other objections raised were the use of lateral film on a two-dimensional medium to represent a three dimensional object and using such a static tool rather than one of “dynamics” which would take growth and physiologic changes into account.

Third Major Phase -Morphologic Description And Typing

The original Downs descriptive analysis was taught to the first reunion meeting of graduates of the University of Illinois Orthodontic department in 1948. This was before Steiner and Tweed had presented there own cephalometric interpretations of there clinical ideas.

Wylie divided the dimensions along the Frankfort plane into contributing linear components, an approach that was later expanded by Coben measuring from point Basion. The profile describing using SNA SNB was developed by Reidel in the 'Northwestern' analysis. All of these concepts were applied in various pure and combined approaches.

On going to California in the early 1950's Ricketts was challenged by colleagues for a direct answer to the question of clinically useful information to be derived from cephalometrics that the practitioner could not obtain from dental casts and oriented photographs.

This key question, the practical application in terms of helping to determine exactly what to do for the individual patient, continued through the years as Steiner, more than anyone else, refined and thought the application of cephalometrics to clinical problems.

In 1960 Ricketts published two clinical papers in an attempt to answer some of those questions asked by students and clinicians. The first one was a report on the morphologic findings in 1,000 cases consecutively seen in clinical practice. It was an attempt to clarify application, entitled "A Foundation for Cephalometric Communication."

Description of morphology and dental relationship was one aspect. The second was classification, categorizing conditions in terms of there clinical requirements and difficulty. The third was the study of change, comparing the morphology of single patient at different stages of development and treatment. The fourth was its application in communication of the first three among clinicians and patient.

The fourth application made the clinician using cephalometrics stand above the rest. With the ability to describe and compare, came ability to explain things and to find out new information. Above all, was the ability to communicate with the rest of the profession in sophisticated and meaningful language? The clinician lacking the tool of cephalometrics simply had no sound basis of supplement conjecture in selecting treatment or analyzing

changes.

The second 1960 publication by the Ricketts was on the analysis of treated cases. The possibilities and the effects of treatment using multibanded orthodontic technique and extra oral traction were explored in depth with cephalometrics. Previous cephalometric and laminagraphic findings published by Ricketts in 1955 used no controls. In 1960 one hundred non-treated patients were included as controls.

Changes were measured in five different areas in logical sequence. First were the changes in the cranial base. The second area was changes in the lower jaw complex, the third in the upper jaw complex and the fourth in the upper and the lower dentures. The fifth area was soft tissues changes in the nose and lips.

The outstanding conclusions were,

1. The findings that significant orthopedic change was accomplished
2. The tooth movements possibilities and control were more extensive than had previously been believed possible.

Fourth Phase- Growth Forecasting And Treatment Planning

The fourth major movements in cephalometrics were the attempt at prediction of treatment results. During the previous period the subject of growth forecasting had also been under exploration by Ricketts. This was an outgrowth of cephalometric laminagraphy of the temporomandibular joint. Long-term growth forecasting had not proven trustworthy with the methods of projection used during the years of 1950 to 1965. However short term forecasting did prove adequate for the period of actual treatment when combined with the likely effects of the treatment. Treatment designs

incorporating growth effects had proven to be quite appropriate and indeed could be recommended at a clinical level for the establishment of objectives and the planning of anchorage.

It was during the period that two other essential subjects needed to be straightened out. First was a determination of which all of the possible points and planes of reference were the most useful and dependable for description and secondly, which were most useful and dependable for evaluation of growth or treatment changes.

Some cephalometric analyses were confusing because they attempted to combine descriptive morphology, analysis of growth and treatment changes and establishment of treatment objectives without distinction.

Point Sella had become popular due to more of its ease of identification than to its scientific merit or anatomical dependability. This problem was clearly apparent from the transcript of the second cephalometric workshop at the Bolton Foundation in 1959, in which it was recommended that cephalometrics had no place at the clinical level. Very little agreement was reached regarding specific reference points because no data was available to test one against the other.

The Third Dimension and Computer Analysis

The second problem prevailing at the time was that cephalometrics at the clinical level had not advanced beyond a two-dimensional application. Transverse three-dimensional morphology and growth were seldom considered.

It was apparent that all of these problems lent themselves to the

application of computer technology. While previous attempts had already been made, Ricketts was engaged in a new series of computer investigations starting in 1965.

In the research over a five-year period, methods and data from most of the material published in cephalometrics up to that time were incorporated. The idea was to take all of the different methods and test them against each other and arrive at an objective consensus. Correlation test were made for each measurement with all the other measurements. Data from frontal and lateral views of new untreated longitudinal series were used.

One half of the subjects were males. Half were class II and half were class I or normal occlusion. All were followed through the dentition. Twenty of the subjects were recorded from the age of the five years. The combined review of all of the current analysis, along with the findings and the data employed for the master computer study, provided a new level of knowledge. This was used in reliable a composite that was then studied in detail by Ricketts.

For the purpose of descriptive morphology, the nature of the problems makes it useful to divide the information in the “comprehensive analysis” into seven fields. The idea was to:

1. Locate, evaluate or assess of dysphasia.
2. Identify those areas within the complex that were treatable by conventional methods.
3. Identify and evaluate those areas which could work against treatment or the factors which, the clinician should take into account in treatment.

As a second application of the computer aimed at clinical and practical application, twelve distinctly superior areas of superimposition emerged for evaluation of changes in the jaws, changes in the teeth, and changes in the smallest tissues.

Data was established to aid the clinician in differentiating that part of the correction made by the treatment and that part of the change attributable to growth alone.

One of these was for changes in the chin, Ba-N registered at cc. Second was for maxillary body change, Ba-N registered at N. The third method was not changed from the original Brodie-Downs orientation, using the palatal plane registered at ANS for evaluating change in the upper teeth. The fourth was for the changes in the lower teeth, Corpus Axis registered at Pm. All were proposed as result of the computer studies of the early 1970's.

The 6TH Phase-Increased Data and Confidence for Morphological Interpretation

The most revealing measurements for communication of a descriptive analysis of the skeletal and dental dysphasia were chosen by Ricketts for each of the lateral and frontal views.

Different individuals can be assessed for their independent characteristics rather than being compared to one standard value as was done with the Downs, Steiner and Tweed analysis. A computer adds the capacity for further biological correction, processing each measurement for age, sex, racial type and actual size.

Lateral Analysis

For clinical application, the most important initial information

pertains to chain location. Factors contributing to this information are: One is related to basion-nasion and two to the true Frankfort horizontal based on the location of true portion rather than the ear rod.

The Facial Axis

The most useful anatomical construction in both description and growth analysis is a central axis of the face or the facial axis. This axis is constructed by connecting cephalometric gnathion with cranial points “Pt” this is related to the cranial axis.

Pt point is located at the lower border of foramen rotundum, which is observed at the root of pterygoid plates at the lower border of the body of the sphenoid bone. This can be a useful reference point for both singular and serial analysis. When Pt point is difficult to identify, a template may be used, as the maxillary nerve that exits from foramen rotundum makes its entrance into the sphenopalatine fossa at the upward and backward curve of the pterygopalatine outline.

As Gn is connected to Pt point and the line extended, it will cross the Basion-Nasion line to form an intersection point called “cc” (for cranial center). Measurements are made at cc. The angle of intersection of the facial and cranial axis is called the facial axis angle.

The mean for the facial axis angle for the general population just happens to be 90°. The perfect right angle is perhaps the ultimate in angular terms. The standard deviation is only 3°. This measurement provides a frame of reference that will indicate whether the chin is upward and forward or downward and backward. It serves admirably as a central reference axis in the face.

Another convenient use of facial axis mentioned by ricketts was for determining the overall type of pattern of the patient for whom treatment is being considered. It was statistically verified by Ricketts to be the most consistent growth axis of any of those proposed and studied so far. It was understood, however, that variations in basion or nasion could occur in extreme pathologic dysplasia. For such conditions further interpretations and secondary methods were needed.

The Facial Angle

The facial angle is well known as the angle formed by the facial line (N-Po) with Frankfort horizontal plane. Despite repeated publications and extensive lecturing on this subject by ricketts and others, still use of ear rod as a representation of portion was done, due to error in technique and variation of the soft tissue around the ear, the ear rod has been noted to be located well over 1 cm from the true ear hole.

With all of these consideration in view, a repeatable selection of true portion can be made. This has been shown by clinical testing to be as accurate and repeatable as selecting the arbitrary visual center of Sella turcica. By bisecting two external canals and bisecting the two orbital rims for orbital, a true Frankfort plane can be constructed.

The Facial plane was described by ricketts as a line connecting nasion with pogonion, located on the anterior curve of the outline of the chin. The facial plane crosses an extension of the true Frankfort to form the Facial angle. By adulthood, in the male particularly, this angle also reaches about 90°. However, during growth it is usually less, increasing about 1° every three years. The morphological standard deviation is 3°. The Facial angle is the most statistically reliable descriptor of chin depth. It expresses the

forward or backward position of the chin and is both useful and dependable for a representation of relative mandibular prognathism.

The Mandibular Plane

A mandibular plane has been popularized in orthodontics as long as cephalometrics has existed. Various points have been used to define the lower border of the mandible, but the most common and most useful are the inferior border of the angle and the menton at the middle of the symphysis, as described by Downs.

In effect, once the symphysis position is defined by the facial axis and the facial angle, the mandibular plane represents more than anything else, the vertical height of the ramus. What has been typically interpreted clinically as a high mandibular plane angle is often no more than a relatively short vertical height of the ramus. In turn, a short ramus height is often caused by a diseased condyle head with an altered growth potential, or by inadequate musculature.

Low mandibular plane on the other hand, represent adequate ramus height and are usually associated with strong healthy condylar heads and musculature in patients with a history of good growth of the mandible. So called "low-angle cases" are those who will more effectively resist treatment of a deep bite by eruption of posterior teeth, while high angle cases with "weaker mandibles" tend to open up with little resistance. "Weak" and "Strong" mandibles are generally associated with weak and strong musculature. These are probably the factors which have led to the wide use of the mandibular plane as clinicians express instinctive and related structure and foundation.

However, the angle itself as measured from any cranial base or facial base is not the accurate predictor that many assume. Its standard deviation is greater than those of the facial axis and facial angle. Like the facial angle, the mandibular plane changes with age and the racial progress of growth. Therefore, any appraisal of the mandibular plane must likewise be age and sex-related.

The Mandibular Bend

The “mandibular bend” angle measures the angulations of the condylar process to the body of the mandible. It is measured as the angle of the condyle axis (Xi through the center of the condyle neck) to the posterior extension of the corpus axis (Pm to Xi). This angle tends to increase about three degrees every five years ($0.6^{\circ}/\text{yr.}$) as the mandible grows, for a total increase of about ten degrees from age three to maturity.

This change with growth is largely an effect of vertical growth of the ramus, so the change will be negligible with no ramus growth and above average with large growth increments.

This change also reflects the “mandibular rotation” or “condyle rotation” with growth, providing objective measures of that visualization.

Maxillary Dysplasia-Point A to the Facial Plane

The anterior-posterior position of the maxilla is of great clinical significance from both functional and esthetic point of view. Because the upper jaw is central to the profile, the simplest and best expression of the location of the maxilla is a direct linear measurement from point A to the Facial plane.

This is a measure of convexity, and of all the measurements in the

face, convexity is one of the most controversial. Establishing meaningful definitive values is the most difficult. This difficulty is compounded by the fact that convexity can also change with age, with mandibular growth and with treatment. Convexity is also somewhat dependent on racial type, further challenging orthodontic objectivity.

Palatal plane to FH

The palatal plane is constructed by connecting the anterior nasal spine and posterior nasal spine.

In the interest of vertical analysis, and in the interest of recognition of the nasal capsule as a part of orthodontic objectivity, the palatal plane has loomed into significant importance. This is particularly true, since the plane is recognizably variable. When relating the nasal floor to harmony and balance with the remainder of the face (despite its relation to the anterior cranial base), the objective in orthodontic treatment has come to be one of a palatal plane reasonably parallel to the Frankfort horizontal plane. The desired value is 0° or 180° , with a standard deviation of 3° .

Denture Height-The Oral Gnomon

For this contemporary measurement, two new points are required beyond the traditional early points selected.

One of these is Xi-point, given by Dr Ricketts at the centroid of the ramus, derived by bisecting the vertical height and the horizontal depth of the ramus. It is a very useful and strong biologic point, almost always located immediately over the mandibular foramen where the mandibular nerve enters into the mandible.

The second point is the vertical point on the symphysis called PM or protuberance mentii. While pogonion is easily discernible on the anterior curvature, it is not precisely defined vertically. PM is selected at the upper termination of the heavy cortical bone of the symphysis, at the start or races for the incisive fossa. This essentially coincides with the lower limit of the resorptive area above the chin. A line from PM to Xi-point represents the corpus axis and can be taken as another measure of length of the mandible.

A useful measure clinically, particularly in open-and closed-bite individuals, is what has come to be called oral gnomon. It is the angle made by connecting anterior nasal spine (ANS), X and PM points. It effectively represents the denture height, or lower facial height, or vertical relationship between the maxilla and the chin.

Dental Relationships

In the more comprehensive analysis, the relationships of the teeth are described in the lateral head film in both horizontal and vertical directions. The molars, cuspids and incisors are related similar to the image that can be extracted from viewing a dental cast.

Lower Incisor to A-Po Line

The relation of the tips of the incisors to the anterior most extensions of the maxilla and mandible (or the A-Po line) has proven through several decades to be a most practical method of assessing lower incisor position.

Ricketts mentioned one interesting feature of relating the lower incisor to the A-Po line is that the mean value changes very little with growth. The norm values changes only slightly from the deciduous dentition right on through to maturity. Most of all the studies of normal and natural

dentitions by Ricketts find the position of the lower incisors about 2 mm ahead of the line A-Po line, with a standard deviation of 2 mm.

Upper molar to PTV

The assessment found for this dimension is based on a perpendicular line from the Frankfort plane to the anterior most margin of the cranial base of the pterygoid plates. From a point (PR) selected at the most posterior outline of the pterygo-palatine fossa, the line drawn perpendicularly to Frankfort is called the Pterygoid Root Vertical or PTV.

In contradiction to the measurement from lower incisor to A-Po line, this value does not change with growth. As a rule of thumb, 3 mm plus the patient's age is used, with an accepted deviation of 3 mm, the upper first molar can be moved distally to the millimeter equivalent of the patient's age with no serious increase in the risk of impaction of posterior teeth.

The Interincisal Angle

Interincisal angles of around 135° were described by Downs in his original analysis. However that normal sample was chosen with some bias against protrusion of anterior teeth. Most normal samples of adult Caucasian individuals show average angles closer to 130° .

However, the interincisal angle does change with time. As the jaws grow in height, the teeth upright slightly. As the lower incisor tends to follow the A-Po line, the upper incisor contained by the lower lip.

In many malocclusions interincisal angles may within normal limits and the incisor relationship still be badly deranged.

It was the Ricketts object to achieve 125 to 126 angles in therapy,

over treating this relationship to allow for retention uprighting, which is quite common. This lower angle quite provides a good plateau on the upper incisor for articulation of the lower incisor and smooth incisal guidance.

Thus, three main measurements are noted in the denture: lower incisor to A-Po for the lower arch, molar to PTV for the upper arch, and interincisal angle for inter-arch relations.

Lower Lip to E line

The last factor in the lateral film is soft tissue, especially the relationship of the lower lip to the esthetic plane. The problems in evaluating esthetics are compounded by differences in racial types and the constitutional types within the races. However, a start must be made, somewhere to evaluate esthetic, and the lower lip to the E line (nose to chin) has proven to be highly satisfactory in the Ricketts experience. The labial surface of the lower lip is influenced by the both lower and the upper incisors, while the upper lip is influenced only by the upper incisor. The upper lip is located ideally approximately 2 mm further behind the line than the lower lip. This tends to hold true for most patients. As the nose grows and the chin develops, the lips gradually appear to contract into the face. Starting with the lips slightly ahead of the esthetic line in the juvenile stages, the lower lip has dropped behind this line by adolescence and continues to retract in adults. This can occur especially rapidly with maturation of males in the late teens or early twenties.

In the oriental and Black races, the nose tends to be proportionally shorter and slightly wider and particularly in the Black, the lips are somewhat thicker than seen in White populations, the author feels that a good objective is easy closure of the mouth with little or no strain, pursing or excessive

mentalis action. This will achieve a most relaxed expression and graceful, healthy, harmonious relationship.

The Frontal Analysis

The frontal head film had been used for growth studies but until computer research in 1968 detailed objective for the clinician was not forthcoming. Lack of interest and experience combined with difficulty in attaining consistently satisfactory orientation in the frontal positioning in the head holder at the time of exposure limited progress in the frontal analysis. Another factor was the lack of accepted reference points and the acquisition of enough clinical data in both normal and treated patients to enable establishment of standards for actual clinical use.

New horizons developed the need for orthodontic criteria in terms of transverse assessment. The development of palatal widening and maxillary orthopedics, the demonstration of mandibular posturing devices such as the Frankel appliance, the characteristic changes occurred in the frontal dimension with extra oral traction, and an awakening awareness of the relationship between respiration and growth all expanded that need.

One of the primary points of interest Ricketts was width of the nasal cavity, because of the importance of attaining normal respiration in the orthodontic patient. These measurements of nasal width were in combination with the palatal plane in clinical diagnosis, and while treatment changes cannot be covered in the scope of this discussion, the nasal cavity can be altered with extra oral traction and attention to the nasal capsule has come to be a major concern to orthodontic clinician.

Mandibular Width

One reason for difficulty with the frontal head film was attributable to the continued efforts to evaluate the mandible from the gonial angles and condyles, and the midface from the zygomatic arches. These points are all far removed from the teeth, and their variability resulted in low correlations. Values useful enough to be practical at a clinical level could not be derived until points closer to the molar teeth were selected.

Basal mandibular width is better described by points just below the trihedral eminence, called Ag (for antegonial tubercle). This is a much more stable area, undistorted by the muscle attachments.

Maxillary Width

Maxillary width is evaluated from the mandible, just as convexity or maxillary relation is measured from mandible. Because there are two sides and two maxillae, the measurement is made for each side. In order to establish a line from which to measure, "Frontal Facial Line" (actually two lateral lines) is constructed from inside margins of the zygomaticofrontal sutures to the before mentioned Ag points. This is related to "J" point or point jugale, which is defined as the crossing of the outline of the tuberosity with that of the jugal process as viewed in the frontal film. About a 10 mm distance from J point to the fronto-lateral facial line is desirable.

Symmetry

The next measurement in skeletal relation is the maxillary and mandibular midlines. By relating point A Pogonion to the midsagittal plane, symmetry of the skeletal mid-line can be assessed. A midsagittal plane is dropped through the top of the nasal septum or crista galli, perpendicular to

the line through the centers of the zygomatic arches. By this method, symmetries can be located within the maxilla or the mandible, or in combination. This information by ricketts assists in the diagnosis of unilateral conditions and severe midline deviations.

Thus, of the ten measurements for the frontal, the skeletal parts are represented by five, i.e. the nasal width, maxilla to mandible on each side and midline deviations.

Denture Relations in the Frontal-Molar Width

In the denture pattern the primary interest is the lower molar width relative to the skeleton. Just as the lower incisor was evaluated from basal points in the upper and lower jaws, so is the molar related to basal bone near its position. In this instance, however the lower molar measurement changes with age. Both the right and left sides should be evaluated.

Actual Intermolar Width

In addition to the molar relation to the jaws, the intermolar width can be measured from the buccal surface as portrayed on the radiograph. There is a 5% to 10% enlargement which should be considered when relating the measurement from the film to the dental cast, but this is relationship within the radiograph.

Intercuspid Width

In addition to the width at the lower molars, the width between the tips of the lower cuspids can also be assessed. These teeth also change relationship during the time, of eruption, requiring the appraisal of age effects in any evaluation.

Denture Symmetry

Similar to basal midlines, the denture midline is assessed from points between the upper and lower central incisor roots. The ideal is that the central sagittal plane falls on all these midline points.

Upper to Lower Molar Relation

Width differences between upper and lower molars are useful in identifying actual and potential crossbites as well as asymmetries. The measurement is made at most prominent buccal contour of each tooth as seen in the P-A view, and recorded as the buccal overjet of right and left upper molars.

The average value is 1.0 mm + 1.0 mm. Class II malocclusion may show a negative value suggesting a crossbite exists. This is a result of mesial rotation and positioning of the upper molar into a region where the arch width is narrower. Such cases require expansion in conjunction with any retraction therapy to produce compatible arch form without crossbite.

THE 7TH PHASE-CONTEMPORARY SERIAL ANALYSIS

While the Steiner analysis was a great step in the advancement of cephalometry for the clinician, it still proved to be inadequate, particularly for longer term growth analysis and specifics in the details of treatment. It focused on changes from the anterior cranial base alone, without any central facial axis. For analysis, broad interpretations in directions of facial development could not be reliably made from such unstable directors as a mandibular plane that is known to undergo extensive remodeling with growth, and a point B that does not represent true basal bone and is influenced by movement of the incisors.

A more complete cranial base is preferable, one near the interface between the face and the entire floor of the brain case. The Ba-N plane has proven to be the most reliable longitudinal clinical reference. Ironically, the small standard deviation of change in the facial axis (from the Pt to Gnathion) with growth narrows the frame of reference to a point.

Again, the research with the computer by Ricketts was responsible for the development of some of these measurements now thought to be critical in the four position analysis discussed earlier. This may be considered a major breakthrough for the clinician seeking confidence in the clinical use of cephalometrics.

For simplification of analysis for changes in the mandible, maxilla, and upper and lower teeth, pertinent data was shown in tubular form, together with extent of change which might lead the orthodontist to suspect that a change was accomplished by therapy. There was always rare extremes, however, as the values were reduced to standard deviations of change or standard variation between time one and time two.

The 8TH Phase-Biologic Growth Of The Mandible And Face

The 8th movement in cephalometrics has been the recognition of the racial course of mandibular growth. While Moss envisioned the growth of the mandible as a logarithmic spiral reasonably constructed via the path of the mandibular nerve, Ricketts found that the mandibular segment of such a spiral is closely approximated by a circular arc. This can be easily constructed for assistant in long-range forecasting of the size and form of the mandible.

While data in terms of blind studies are not yet published, the racial

method of prediction works with uncanny accuracy and is quite trustworthy for clinical use in the absence of growth related pathology.

In addition to superimposing on arcial forms, the location of vital centers from which growth appears to radiate in an orderly manner is another concept. These vertex centers seem to be identified with the growth of other oral, nasal, and orbital capsules in the face and indeed with the brain itself. Thus, as an eighth move in cephalometrics, departure from the traditional point and planes is required for a better understanding of the biological nature of morphology and growth*

The 9TH Phase

While the Golden Section and Phi relationships have been known to artists and mathematicians for centuries, their direct application to the face by ricketts from a therapeutic viewpoint has only recently come under inspection. The Golden Section and Fibonacci numbers seem to be compatible with both the fields of mathematics and biology. The Golden Section is not a mere mathematical presence scientific investigations in the field find that proportion of 1.618. or its reciprocal 0.618, as a basis of beauty, harmony balance, unity and grace.

Several composites of normal and well treated patients all point to the fact that in normal facial morphology there are several places where these divine proportions can be recognized .When the skeleton and the denture are in normal arrangement and normal function and beauty, these relations even transcend racial differences.

These arrangement and relationships are useful for patients with extreme dysplasia and particularly in those requiring surgical correction?"

ugly patients are indeed made quite beautiful when the skeletal arrangement follows this principle.

BIOPROGRESSIVE THERAPY

“Bioprogressive therapy” It is a highly flexible, versatile method composed of a body of principles.

All of these developments in edgewise formed the background for the present bioprogressive method. Bioprogressive therapy may be considered an evolution from the edgewise technique, with features of certain light wire methods incorporated. The development in edgewise technique formed the background for the present Bioprogressive method. By 1950 certain edgewise clinicians were becoming concerned with some of their results. Some root resorption was not common. The use of round arch wire in the leveling stage of deep bite cases seemed to be leading to the development of protrusive dentitions. Extraction was often advocated on only therapeutic ground. Even some patients extracted for objectives of lower incisor stability often were found to be imbricating after treatment. This caused many clinicians to pause and examine the prevailing trend in treatment methods and enquire into the causes of some of the problems being observed. Certain breaks from the edgewise full banded convention and technique were started.

Large round headgear tubes were soldered on strips prior to banding because the double tube setup on upper molar came to be common place. The maxillary arch was observed to expand successfully (when permitted to do so) with a plain 0.45 inch dental bow as the class II malocclusion was corrected. Arch form changes in the lower arch also were noted following treatment on upper arch only. Both Kloehn and Brodie reasoned that

significant environmental influences were exerted apparently through the function of the forces of occlusion.

Another change which took place in edgewise was the departure from the complicated use of 2nd order bends in the upper arch in the treatment of class II patients. Straight arches with sliding hooks and methods to slide teeth on an archwire were introduced to move buccal segments distally as advocated by Wright in about 1949. However elongation of the upper anterior teeth under class II intermaxillary traction still occurred, as well as from extraoral cervical pull and J hooks of the arch. Both of these tended to produce “Gummy” smiles in patients.

The extrusion of the lower molar and the upper incisors by intermaxillary elastic pull was considered to be the primary factor. Prevention of incisor interference and holding of the lower molar downward were foreseen as factors in anchorage preservation of the entire arch as the prevention of dumping of the occlusal plane. As the incidence of extraction increased borderlines were unsettled. In the Storey and Smith experiments, it was discovered that optimal translatory retraction occurred in the ranges between 150 and 300 gins of force. This was based on the pressure hypothesis that a tooth was being moved through cancellous bone in space closure. However Ricketts pointed out that the influence of compact bone as cortical plates must also be recognized in the analysis of movement. Deliberate experiments were set up by Ricketts at the clinical chain in attempting tooth movements through, against or around heavy plates of compact bone with a variety of force. An effort toward the use of a lighter force was placed in scientific protocol in order to approach the clinical range of forces as suggested ‘by Storey’s work.

One of the recognized problems in all kinds of treatment was the rotation of the mandible or the downward and backward dropping of the chin during treatment resulting from either extraoral traction as tooth extrusion from intermaxillary forces or even with simple bite plates. Prevention of incisor interferences became a new problem in mechanics.

Principles of the Bioprogressive Therapy

Ten principles have been developed in an attempt to communicate an understanding of the mechanical procedures that Bioprogressive therapy may use in developing a treatment plan, including appliance selection and application specific to each individual patient.

1. The use of a systems approach to diagnosis and treatment by the application of the visual treatment objective in planning treatment, evaluating anchorage and monitoring results.
2. Torque control throughout treatment.
3. Muscular and cortical bone anchorage.
4. Movement of all teeth in any direction with the proper application of pressure.
5. Orthopedic alteration.
6. Treat the overbite before the overjet correction.
7. Sectional arch therapy.
8. Concept of overtreatment.
9. Unlocking the malocclusion in a progressive sequence of treatment in order to establish or restore more function.
10. Efficiency in treatment with quality results utilizing a concept of prefabrication of appliances.

Ricketts pointed out that the influence of compact bone or “cortical plates” must also be recognized in the analysis of movement (Fig. 1).

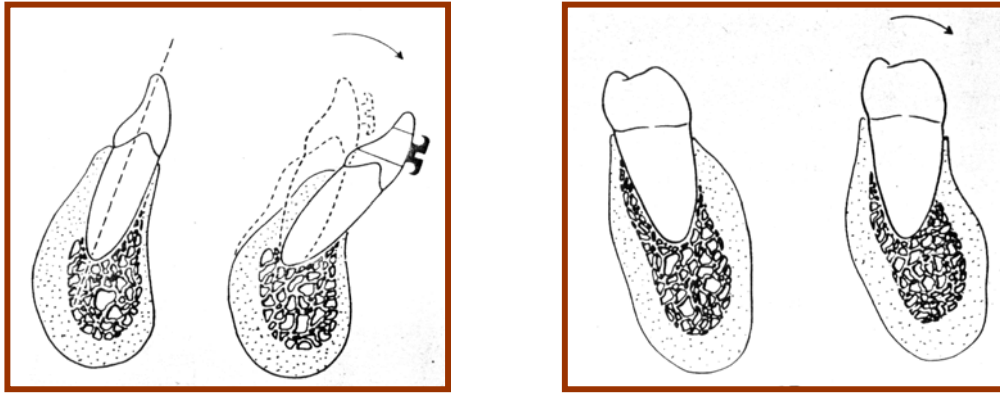


Fig 1

The external or internal bony alveolus exerts distinctly different qualities than cancellous bone when encountered in tooth movements, as had been noted by many clinicians. The study of movement against or through cortical bone therefore needed to be taken into account.

By the 1950's many clinicians had become preoccupied with extraction procedures or keeping teeth “over basal bone.” Studies of anchorage, therefore, often did not pertain to other types of treatment, such as expansion or full arch correction under the pull of intermaxillary elastics, because it was not believed that molars could be moved distally. The amount of arch slippage permitted in the given Class II case and the subsequent changes in the environment attending the reciprocal correction of overbite were often not regarded fully because it was also believed by many clinicians that anchorage could not be estimated or predicted, even on a cursory basis.

Deliberate experiments were set up by Ricketts at the clinical chair in attempting tooth movements through, against or around heavy plates of compact & bone with a variety of force. An effort toward the use of lighter forces was placed in scientific protocol in order to approach the clinical range of forces as suggested by Storey's work

Developments toward progressive therapy

The fixed apparatus

Preformed bands

Pinching of bands required expensive, time-consuming, and customized procedures. Work with preformed chrome alloys led to narrowing and half-sizing of molar and incisor bands together with softening of material for ease adaptation. During the late 1950's premolar and canine forms were developed. For chronologic reference, the Ricketts typodont for the American Board examination in 1958 was in fully preformed bands for all teeth. The work of banding was vastly reduced, and preformed banding with the premounted brackets and tubes was demonstrated on closed-circuit television at the 1962 meeting of the American Association of Orthodontists in Los Angeles (Fig- 2)

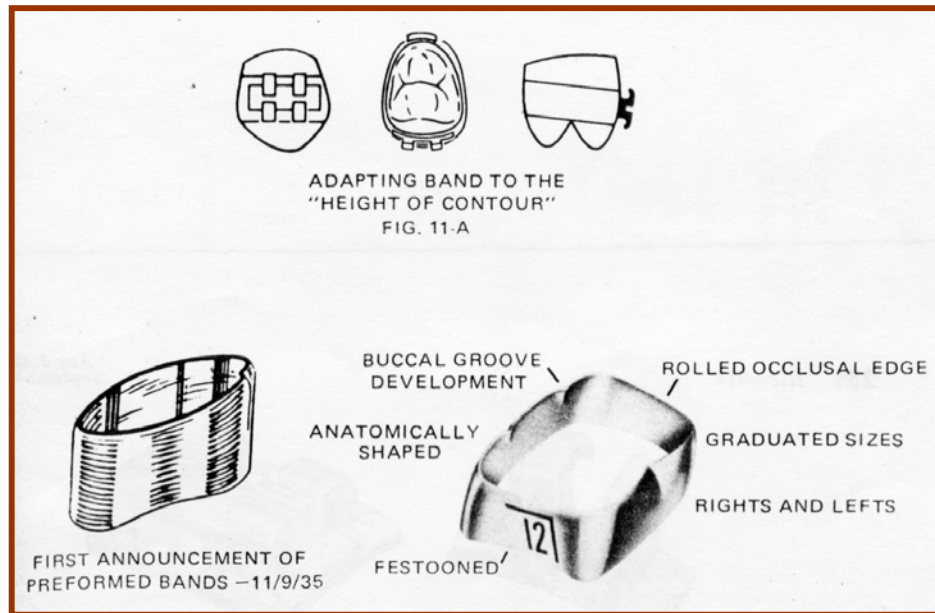


Fig 2

Siamese 0.018 by 0.030 inch bracket

Increased mechanical efficiency was achieved over the staple for rotation. One development was a rotating bracket. However, a double purchase on the tooth was thought to provide better control for all movements (Fig. 3).

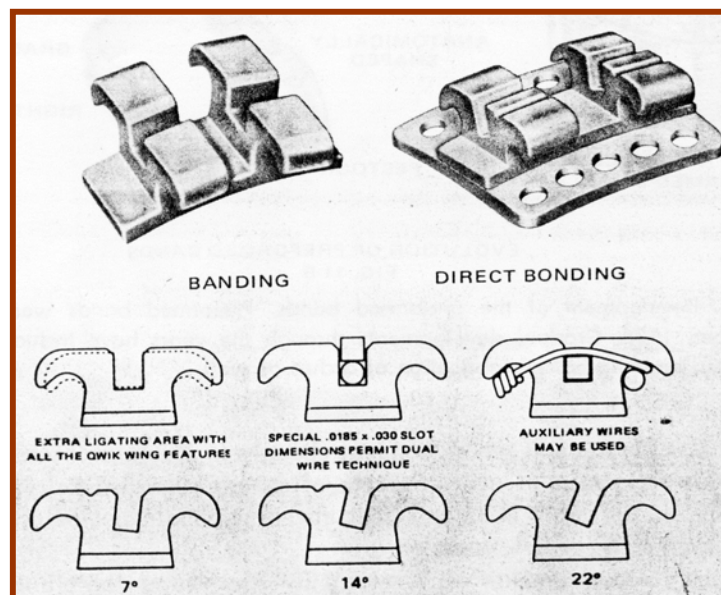


Fig. 3

Two soldered brackets had been used on molars and central incisors for great advantage in control with secondary edgewise. These were designed by Swain to be milled into one gold bracket and were subsequently milled in the chrome alloys as they came into use. Therefore, a wide-flanged easy-tie 0.018 by 0.030 inch Siamese bracket was designed by Ricketts for ease of ligating and uprighting access and flexibility of elastic attachment. This design was an evolution from the original Steiner design. The narrow slot was developed in consultation with Steiner and Lang. This bracket is fabricated on bands can be bonded directly.

Background for bioprogressive designs: -

Premounting of buccal tubes on gold strips prior to pinching ultimately led, to formulas for the mounting of all tubes and the redesign of the tubes altogether.³⁰ With the development of standardized preformed bands, Ricketts, for the new therapy, advocated a bracket and band arrangement for alignment of band edges to marginal ridges, for the “line of occlusion” in fitting and cementation (Fig. 4).

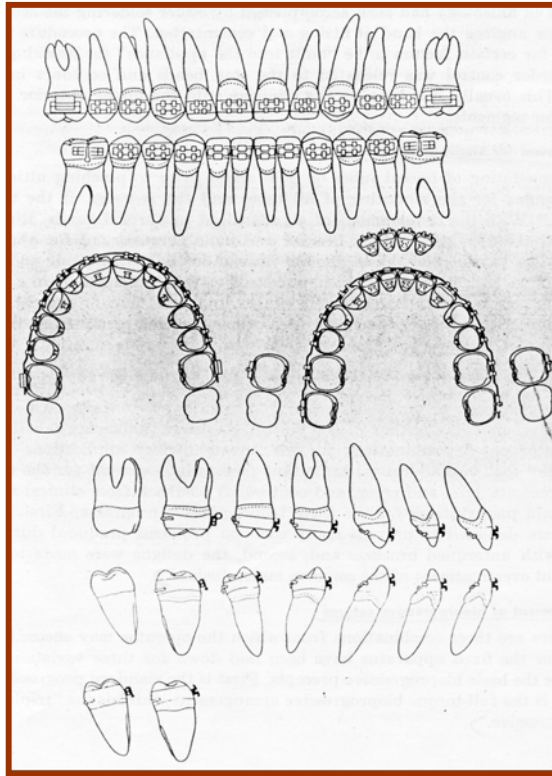


Fig 4

This meant that brackets should be premounted in a standardized manner and that formula for prewelding and bracket design should be worked out. These moves permitted a straight-wire approach to treatment with the exception of lower buccal torque and first-order bends.

Ricketts took two additional important factors, into account for the designs as measurements, trial and error, and continuous feedback from clinical results led I to certain prescriptions for the three bioprogressive programs: First, the formulas were designed to prevent many common problems produced during treatment with untorqued brackets and, second, the designs were made to assist in I sufficient over treatment of the common malocclusions.

Development of bioprogressive set-ups: -

Prescriptions for the fixed apparatus have been laid down for three variations, but all still use the basic bioprogressive precepts. First is the standard progressive setup; second is the full-torque bioprogressive arrangement; third is the “triple-control” bioprogressive.

Much effort, time, and expense would be required to make a perfect individual prefabricated set up in terms of torque tip and rotation for every tooth. It would possibly be a good practice if, indeed, this were the objective with the final appliance. However, in view of the need for buccal or labial inclinations for anchorage the overcorrection of rotations, and the over treatment of arch and jaw relationships, an absolutely straight wire finishing is not necessarily the goal and arch form is also a fundamental first-order consideration.

Considering the beauty of intraoral adjustments with the bioprogressive therapy, particularly those of a minor nature, the gain to be experienced with absolute torque, tip, and rotation bands, and brackets might be questioned.

Standard bioprogressive

As mentioned before, the edgewise appliance formed the basis for bioprogressive development. For the original bioprogressive therapy standardized tipping was studied designed, and modified over a period of years for clinical application (Fig. 5).

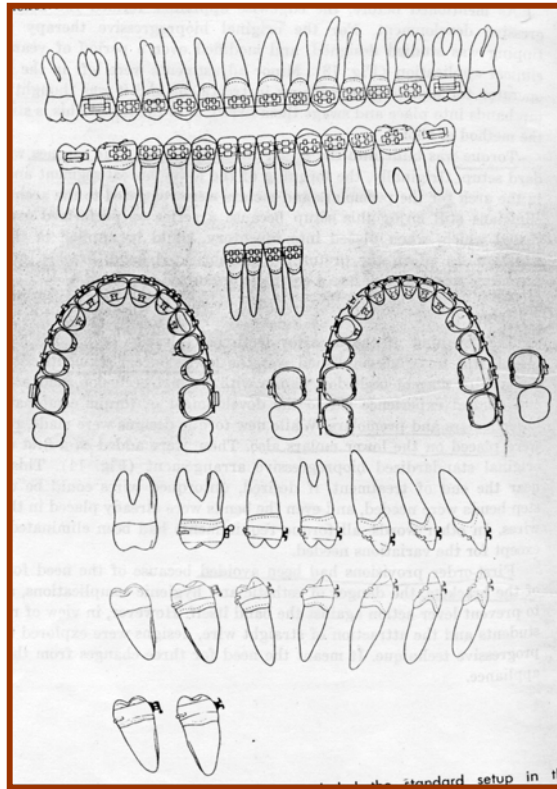


Fig. 5

Minor adjustments were left in the hands of the operator for individual conditions in treatment and it was thought advisable to tap bands into place and swage them firmly onto the teeth. This is still considered the method of choice.

Torque was built into the upper incisors and all four canines with the standard setup. Originally, the torquing of the lower buccal segment and step bends in the arch for the premolars and molars were relegated to the arch wires. Many clinicians still enjoy this setup because a series of preformed arches was designed which, when placed into inventory, could be applied in the individual situation. In effect, the preformed, prefabricated band, bracket, and arch wire inventory was designed into a complete organized approach.

Full Torque

The torquing of the anterior teeth had already been made, and the only torque still to be accomplished was the lower buccal segments. Studies on patients with normal occlusion, skulls with normal occlusion, and actual practice and clinical experience led to the development of torque combinations for the lower molars and premolars. While new torque designs were made, rotation tubes were placed on the lower molars also. These were added as a first option to the original standardized bioprogressive arrangement (Fig. 6).

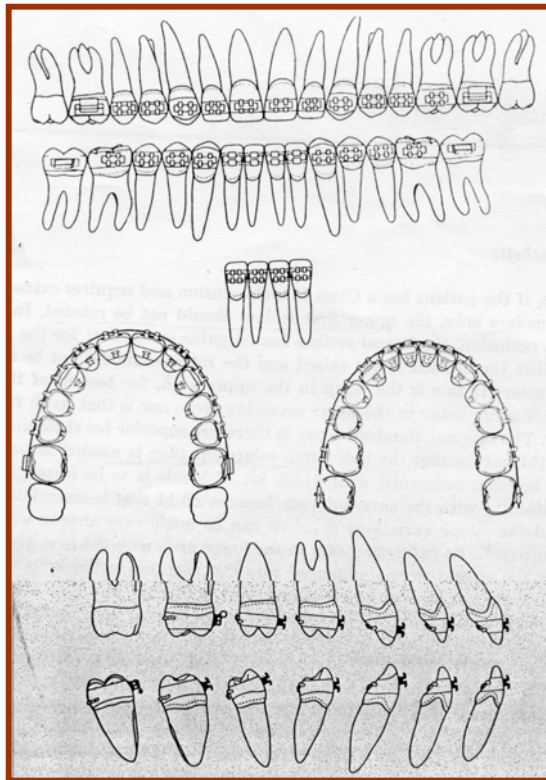


Fig. 6

This meant that near the end of treatment, if desired, untorqued wires could be used. Lateral step bends were needed, and even the bends were already placed in the preformed wires. In other words, all torque

requirements had been eliminated in the wire except for the variations needed.

First order provisions had been avoided- because of the need for bulking-up of the brackets, the danger of esthetic and hygienic complications, and the need to prevent lever action against the band itself. However, in view of requests from students and the attraction of straight wire, designs were explored to fit the bio-Progressive technique. It meant the need for three changes from the full torque appliance.

Triple control setup

In order to step certain teeth outward, the adjacent teeth would need to step inward (Fig. 7).

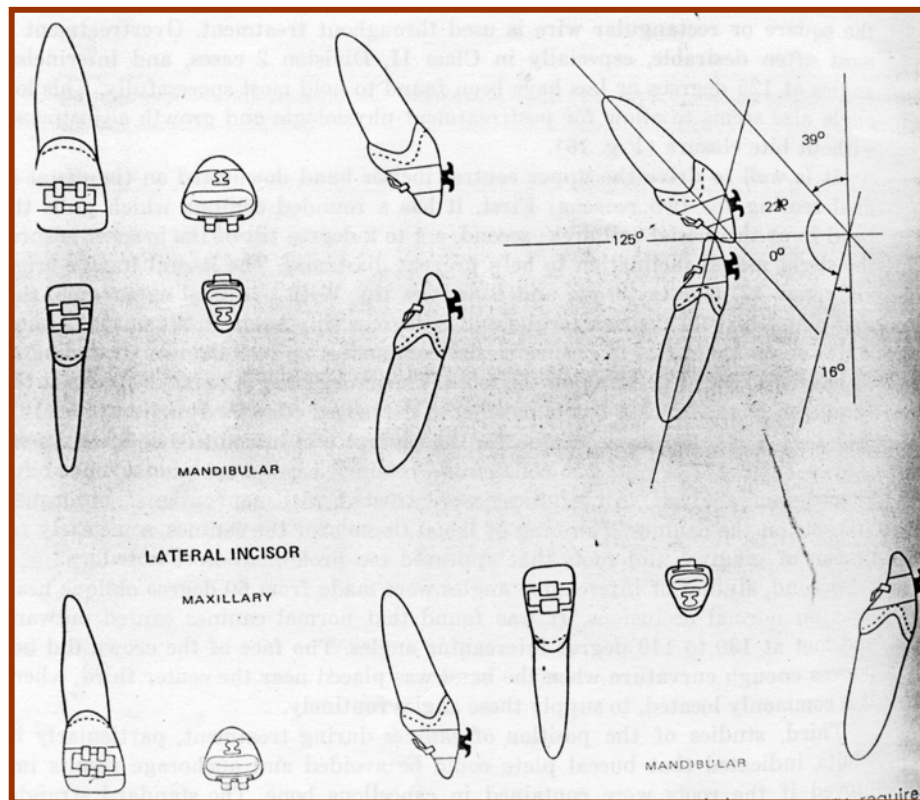


Fig. 7

First, all the canine brackets would need to be raised to produce the buccal step for the first premolars. Second, because the molar needs to be stepped buccally from the second premolars and in order to obviate the step in the wire, the second premolar is raised so that it will be aligned lingually. The flaring of the upper molar tube to produce rotation of the upper molar was thought to produce needless extension into the buccal mucosa and complicate expansion. Many clinicians have difficulty in placing enough rotation and in remembering to adjust it at every appointment. The third move was to rotate the upper molar tube.

The options for variation in treatment still need to be available, however. For instance, if the patient has a Class II malocclusion and requires extraction of upper premolars only, the upper first molars should not be rotated. In this event, for best occlusion, the buccal section has no gable or bayonet for the molar. This means that the bracket is not raised and the rotation should not be made in the upper molar. If this is the setup in the upper arch, for best fit of the teeth the step bend is not made in the lower premolar area; nor is that tooth fully rotated distally. The original standard setup is therefore superior for these unusual cases. All this means that the individual treatment plan is needed before the orthodontist becomes concerned with which kit of bands is to be employed. There is little difficulty with the anterior teeth because all of that is essentially standardized and the minor variations required can be made very simply with intraoral adjustments. In an extraction case in the lower arch with the first premolar missing and the second premolar moved into the position in the arch normally occupied by the first premolar, a 7 degree torque bracket

would be needed on that; tooth, which means that the technique becomes further complicated.

Standard bioprogressive (original)

Let us now list these prescriptions, together with a certain rationale of their use. Second-order and third-order factors are built into the bracket and tubes A for the anterior teeth. First-order factors will be considered later.

Provisions for tipping (second-order control) : - (Figs. 5, 6 and 7)

The operator should be able in fitting, particularly with the band driver, to angle the band on the tooth up to 3 to 4 degrees without band distortion. The more malleable band can “draw” this much. Small angulations are too difficult to be seen with the naked eye for premounting, and therefore tipping of at least 5 degrees or more was recommended for prewelds, leaving the finer detail to the ; technician at cementation.

All bands therefore receive brackets parallel to the band margin except the following:

Upper lateral incisor	8 degrees down on distal
Upper canine	5 degrees down on distal
Lower canine	5 degrees down on distal
Lower first molar	5 degrees down on mesial

The tipping of the bracket (or tube) is a compensation for tooth morphology and natural fit of a band on these teeth. To reiterate, by driving, the band can be adjusted and stretched 2 to 3 degrees of angulation.

Provision for torque (third-order control) : - (Figs. 5, 6 and 7)

Some changes were made from time to time in certain angulations, but again feedback from problems in treatment and results achieved in thousands of cases lead the following prescriptions:

For standard bioprogressive, full-torque bioprogressive, and triple-control bioprogressive

Upper central incisor	22 degrees (root to the palatal)
Upper lateral incisor	14 degrees (root to the palatal)
Upper canines	7 degrees (root to the palatal)
Lower canines	7 degrees (root to the palatal)

For full-torque bioprogressive and triple-control bioprogressive

Lower second premolar: -14 degrees (root to the buccal except in first premolar-extraction case;

For full-torque bioprogressive and triple-control bioprogressive

Lower second premolar: - 14 degrees (root to the buccal except in first premolar-extraction cases)

Lower first molar: - 22 degrees (bracket or double-tube root to the buccal)

Comments on teeth

Incisors some may believe that 22 degrees of torque on the upper central incisor is excessive. However, a study of problems in initial arch placement in maxillary protrusion cases shows that first arch placement may lead to forward root movement. With the 22 degree bracket, torque is

automatically treated if the square or rectangular wire is used throughout treatment. Overtreatment is most often desirable, especially in Class II, Division 2 cases, and interincisal angles at 125 degrees or less have been found to hold most successfully. This low angle also seems to allow for posttreatment physiologic and growth adjustments without bite closure (Fig. 8)

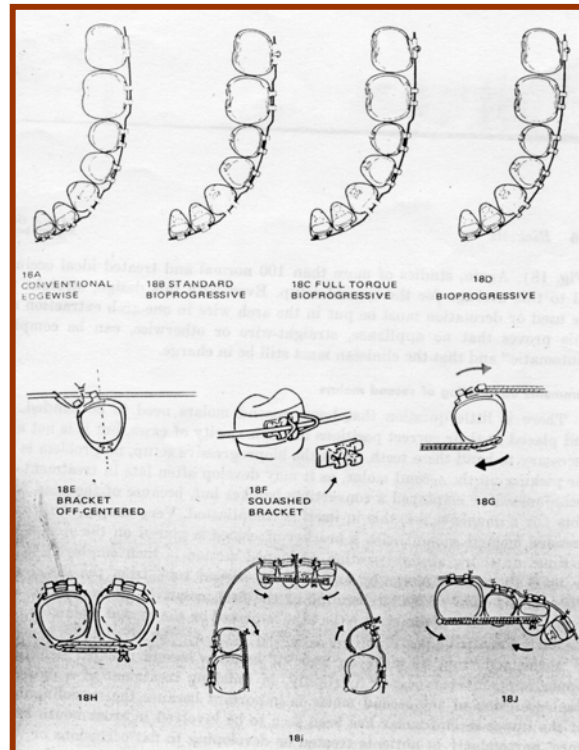


Fig. 8

It is well to drive the upper central incisor band downward on the distal in final seating for two reasons: First, it has a rounded contour which pulls the band in at the mesial call area; second, a 1 to 2 degree tilt of the bracket ensures the slight mesial inclination to help prevent diastemas. The lateral incisor originally was 17 degrees torque and 5 degrees tip. With practical experience, this was changed to 14 degrees torque and 8 degrees tip. Again in seating, the band is driven on the distal to ensure mesial

contouring up to 3 degrees or ending at 10 to 11 degrees, depending on the tooth. The entire issue is to make sure that the alignment of the bracket box is parallel to the incisal edge for function (Fig. 8).

Canines The 7 degree torque for the canines was introduced following four studies. First, 200 consecutive retained cases were photographed for occlusogram analysis. All of these were treated with conventional untorqued brackets on the canines. Thinning of labial tissue over the canines, some early recession of gingiva, and roots that appeared too prominent was noted.

Second, studies of intercanine angles were made from 60 degree oblique head films on normal occlusions. It was found that normal canines canted outward and met at 130 to 140 degree intercanine angles. The face of the crown did not possess enough curvature when the band was placed near the center third, where it is commonly located, to supply these angles routinely.

Third, studies of the position of canines during treatment, particularly in; adults, indicated that buccal plate could be avoided and anchorage results improved if the roots were contained in cancellous bone. The standard straight bracket on the canine inclined the root too far to the labial and proved to make root angulation more difficult in adult extraction cases. This has also been observed in patients treated by the Begg method. This is one feature or difference in the bioprogressive and Andrews straight-wire arguments. Detorquing can be accomplished very easily near the end of treatment by contracting with r00™ wire if torquing of the central incisors or canines is considered excessive for individual case. However, in my experience, this is quite rare.

The fourth study was also of normal occlusion in skulls and cephalometric frontal tracings. The normal lower canines were slightly inclined laterally and forward. In their proper angulation, they stress down their long axes and therefore possibly support the corners of the mouth better than if the roots are inclined more lingually.

The angulation is 5 degrees standard for mesial inclination of the tooth. In the upper, driving to seat on the distal can add another 3 to 4 degrees. If individual teeth warrant it. Again, the bracket box should be parallel to the mesial and distal contact areas to ensure final occlusion.

Lower posterior segments

In the lower arch in ideal normal occlusions, a progressive torque will be noted. These are quite evident in a frontal head film. Studies of sectioned normal skulls suggest that the lower first premolar crown is almost straight upright. However, a lingual crown cant starts at the second premolar. Experimentally and from a practical viewpoint, this angulation averaged about 14 degrees.

The lower first molar was found to average about 20 to 25 degrees, and a 22 degree torque for the bracket or tube was found to be acceptable. Almost a 10 degree difference was observed between the first and second molars. Individual occlusions were noted in which a tube placed on the buccal surface of the third molar was 45 degrees. These torque positions of lower molar roots are highly significant for proper anchorage with bioprogressive therapy. The tipping of 5 degrees (down on the mesial) has been standard and worked out well for 20 years.

Provision for rotation and step outs

First-order control with standard and full torque bioprogressive

It is supposed that rotations of teeth in line with the arch may be considered 'first-order control. Certain of these provisions can be built into the brackets: lower molar, 12 degrees (to the distal); lower molar tube, 12 degrees; all remaining, teeth, as dictated by initial rotations.

The step-out step-in provisions in rising of selected brackets were discussed, with the full triple-control wire descriptions'. They were 0.6 mm. steps, on the average.

Rotation of teeth

Ligation to eyelets was needed for rotation when single brackets were used, although ligature "figure-of-eight" ties for reciprocal rotations have always been used, if available. If slight over rotation is desired with the Siamese bracket, one or all of four procedures may be considered:

The band may be cemented slightly off center, so that a single ligation will cause excessive rotation. This prevents the need for anti-rotation design on a bracket. Only one bracket need to be tied.

One bracket can be filled with an elastic or squashed shut with pliers to produce a block or fulcrum. It can be reopened later with a pin cutter if necessary.

Reciprocal ties or A-elastic chains can be used with Siamese as well as single brackets.

Lingual cleats are placed throughout for counter moments or couples of force which now can be provided from the inside of the arch. These

lingual cleats are highly efficient and are a strong argument for banding instead of direct bonding only to the labial or buccal side.

Because of the lower molar form and the need for right and left precontoured lower molar bands, it was decided to include in the lower molar tube design also a rotation of 12 degrees. This helped to further reduce arch wire manipulation . Again, studies of more than 100 normal and treated ideal occlusions led to this average for the typical setup. Even with this design, straight tubes are used or derotation must be put in the arch wire in one-arch extraction cases. This proves that no appliance, straight-wire or otherwise, can be completely “automatic” and that the clinician must still be in charge.

Comments on banding of second molars

There is little question that lower second molars need to be banded, used, and placed in their correct positions in the majority of cases, but it is not always necessary to band these teeth. With the bioprogressive setup, no problem is posed for picking up the second molar, as it may develop often late in treatment. Some I techniques have employed a convertible bracket but, because of the need for two 1 slots (or a double tube), this in itself is complicated. Very simply, with the progressive method a band with a bracket of choice is placed on the second molar. A separate short, straight section or looped section is then employed to rotate or level the second molar by entering the second tube from the distal aspect. This can be done without rebanding of the first molar. If, of course, the second 1 molar is available at the start, the tube is placed on the second molar for routine ideal arch control.

Some orthodontists make an issue of banding second molars, including the upper ones, in every case. Certainly, in finishing treatment of a patient, the final occlusion of the second molar is important because the mesiolingual cusp of the upper second molar has been seen to be involved in cross-mouth interference, particularly in patients treated or developing to flat occlusions or without canine or corner guidance in function. However, studies have shown that the second molar may not reach its normal occlusion with natural development sometimes until the age of 16 years. It is my practice, therefore, to band the upper second molar only rarely, and this is usually for cross-bites and Class III conditions. In many cases, banding the second molar complicates treatment and inhibits Class II correction and may even lead to needless extractions. Observations on thousands of postretention cases show that this tooth will usually drop into normal function on its own. The major exception is the presence of an impacted upper third molar. In this event, the third molar may be removed early or the second molar may be removed if the third molar is large, healthy, and in good position.

If the tooth is banded, a normal upper molar band is prepared, fitted, and placed. The upper second molar normally inclines slightly buccally. If Class II elastics are employed, the canting of the occlusal plane may intrude the upper first molar. In this event, banding of the second molar is advised routinely.

The background and philosophy for development of bioprogressive therapy has been briefly explained. Organized studies leading to biologic forces need and consequent wire sizes to be used have been reviewed.

The prefabricated fixed apparatus or bands and brackets used with technique have been explained. Feedback from treated cases, using intraoral photographs, study models, and particularly cephalometric analysis, has led to the gradual development of the present schemes. The standard bioprogressive setup, the full-torque arrangement, and the triple-control formulas have been described.

With the availability of prefabricated bands and bracket designs, organized in a plan together with performed arches and modules, most of the arch-wire bending at the chair has been eliminated.

With the fixed apparatus standardized for bioprogressive therapy, Slight individual adaptation of bands can be made to make it a very efficient and economical procedure for routine clinical use—thus its flexibility. Second-order (tip) and third-order (torque) control are supplied in the bracket and tube design and their prefabrication as discussed earlier.

To reduce time-consuming arduous tasks at the chair while at the same time producing better standardized and controllable mechanisms of superior quality, many recommendations were made for commercial production of arch forms and sections or for rising of certain brackets for a triple-control arrangement

The arch sizes were organized in the bioprogressive system (fig. 9).

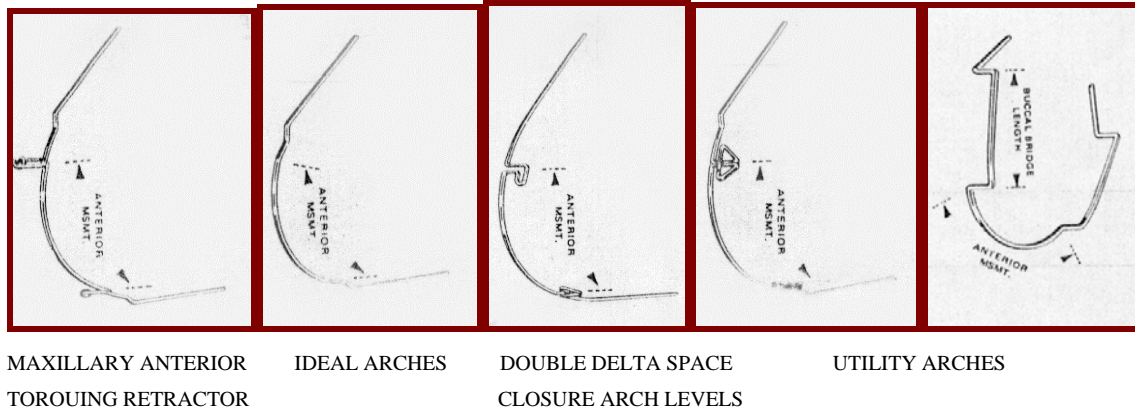


Fig. 9

Fig. 9.. *The standard wires preformed to accompany the preformed bands and prefabricated assemblies. These wires come in various sizes and the millimeter reading in that which is measured between the distal aspects of the two lateral incisors in the typical patient. The utility, the double delta, the closed helix, the .deal, and the finishing arches are common sequences employed.*

In order to select an arch wire, for the individual patient, a measurement was made from the distal margin of the lateral incisor to the same point on the opposite side and converted to a numbered arch. The system is standardized same numbered arch for each individual can be used throughout treatment without changing sizes in the five continuous arch types provided. In other wards, a No. 5 ideal arch size would be followed by a No. 5 finishing arch. The arch types are the idea!, utility, double-delta, closed-helix, and finishing.

Provision in the standardized ideal arch for aid in detailing (first-order control): -

As stated before, the “ideal” arch principle is used essentially to perfect the individual arch. As the upper arch is coordinated to the lower (the lower is the Base) and brought together with intermaxillary traction, a finished occlusion will allegedly result with the edgewise arch philosophy. Ho help minimize the thickness of bulky brackets and to help simply

inventory and procedures, first-order control (step bends) are provided in in performed arches. Loops and controlled activations are needed particularly for efficient treatment. During treatment the ideal arch is employed for near-final alignment and arch form. The essential differences between the design offered here and the traditional edgewise may be seen in Fig. 10.

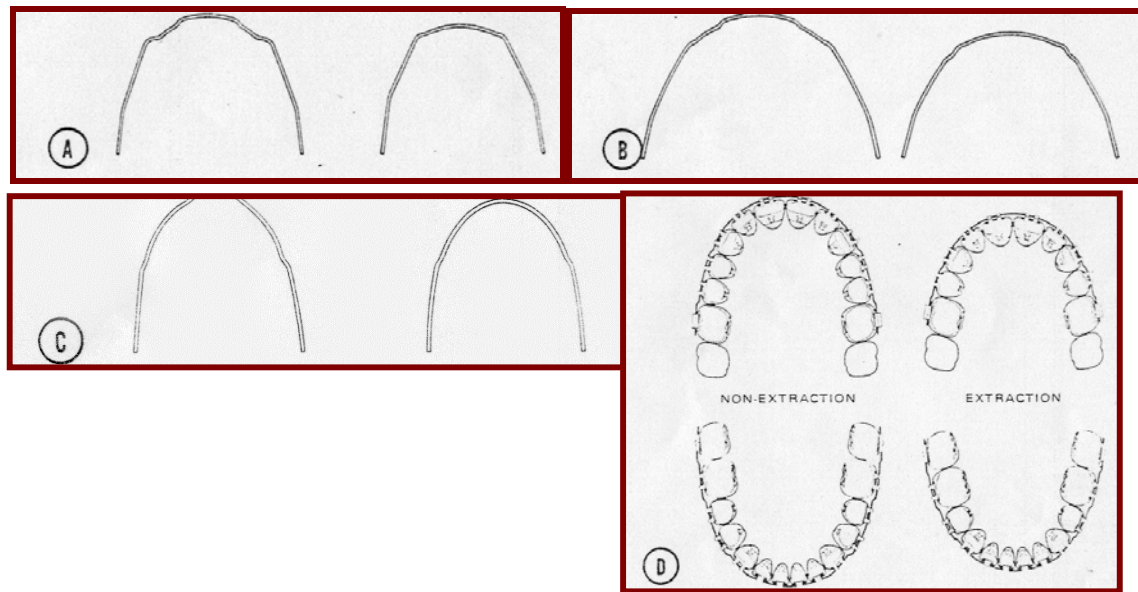


Fig. 10

Fig. 10. Throughout the evolution of edgewise therapy the edgewise arch took forms, starting with Angle in 1929 (A), described by Wright in Anderson's textbook the 1930's (B), by Tweed in his textbook and practice in the 1940's and 1950's (C) on to the bioprogressive forms as described by Ricketts in the 1960's and 1970's (D) The conventional patterns are fashioned following the trifocal elliptical principle of Brodes and the biparameter catenary curve of Schulhof.

The bioprogressive arch form is characterized by flattening the canine area rather than boxing out at the canine eminence. A slight gable is used mesial to the canines and a definite buccal step is used at the distal aspect of the canine for the first premolar in both arches. Finally, definite step bends (and rotations if rotation tubes are not used) are made for the molars. This includes the lower rotation (12 degree average) as well as the upper rotations

(15 degrees average). With the bioprogressive method, these step bends may be placed by the clinician technician, or assistant.⁴¹ with the triple-control bioprogressive setup, these steps bends are essentially eliminated)

Other Preformed Arches

The utility arch. This vertically offset arch is employed for a variety of Purpose. It is commonly a starting appliance but can be employed any time throughout treatment.

The double-delta arch. This arch is used for integration of buccal and anterior segments or for space closure following segmented therapy (Fig. 11).

The vertical closed-helix arch (torquing). This arch is used for space closure bat, used upside down in the upper arch, is very efficient for torquing with space closure of upper incisors (Fig. 11). It may, however, be used in the conventional (loop to the gingival side).

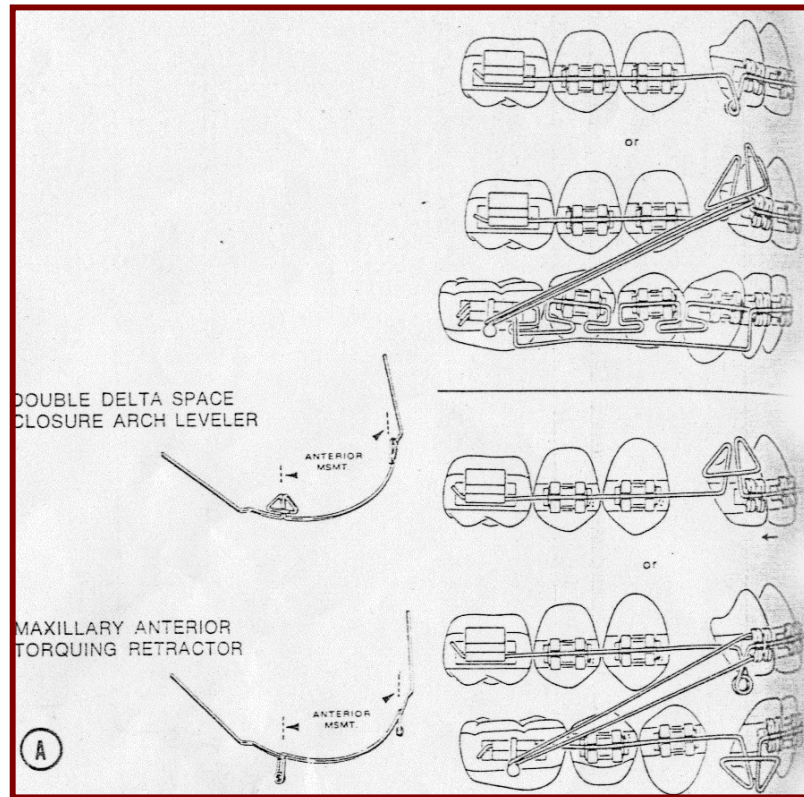


Fig.11

Fig.11. The application of integrating arches. The double-delta loop serves as a spool reducer and is used to level and integrate the arches (A). Note that the intermaxillary traction should be placed over the mesial bracket rather than over the anterior loop is anchorage problems. Too much force on the anterior loop scleroses these teeth and inhibits convenient correction. If the elastic is to the anterior teeth, it should be very light and the total force should not exceed 300 Gm. at any time. For retraction of the upper anterior teeth, 90 Gm. is sufficient for each central incisor and 70 Gm. for each lateral incisor. Intraoral photographs (B and C) before and after activation on Patient K. B. (3-week interval) shows the same setup in actual clinical experience; a "T" series can also be seen. D shows a vertical helix being used for torquing incisors.

The finishing arch (horizontal loops included). This 0.018 by 0.022 inch arch is used for space closure," torque, arch-form control, and overtreatment at progressive debanding. This size of wire is employed because of spaces spanned (Fig. 12).

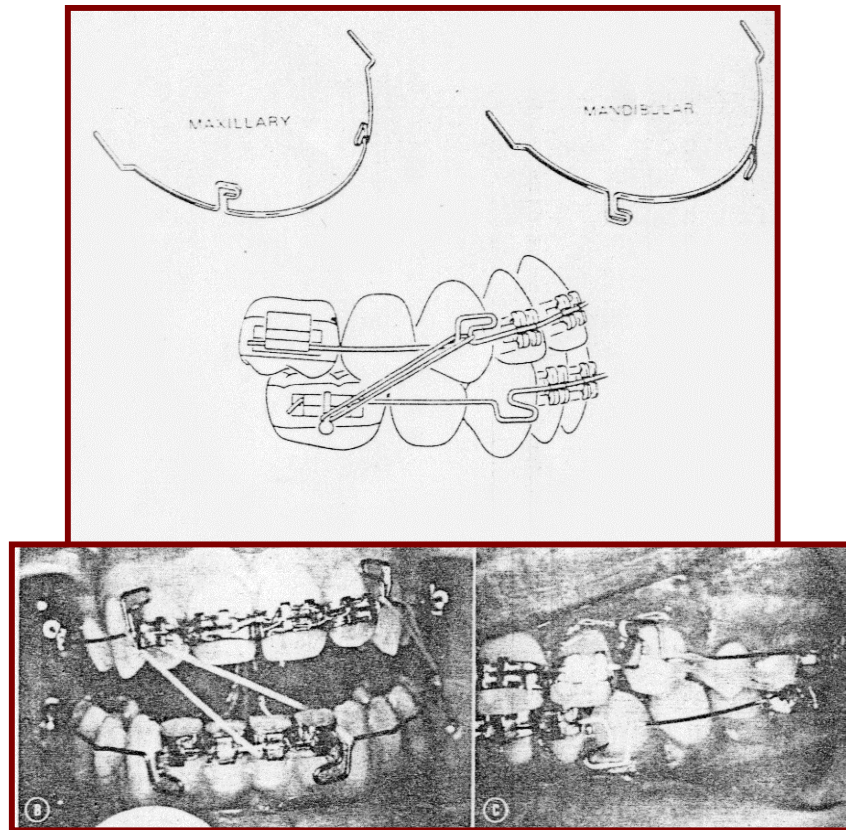


Fig. 12

Fig. 12. *Progressive debanding is usually employed, the goals being space closure and overtreatment. The drawings (A) show the setup for extraction and nonextraction. B and C The actual arches in the mouth; the lower loops are opened approximately 1 to 1.5 mm and finishing in Class II cases is usually accomplished by distal retraction of the upper incisors from the pull of intermaxillary elastics off the lower incisors. This will keep the upper buccal segments from jerking forward. If the buccal segments are adequately over treated,, then conditions will permit tiebacks or activation of the upper loops from the stability of the upper molars.*

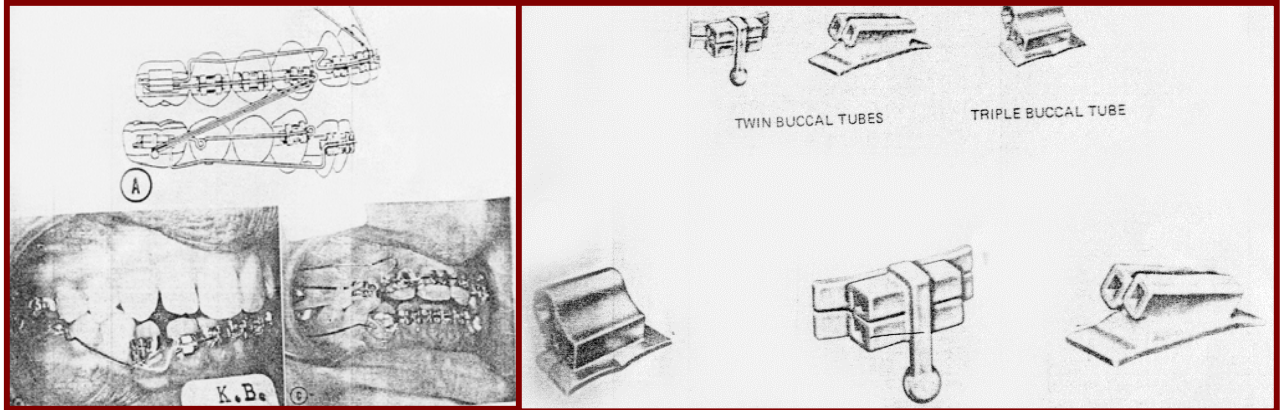
Other auxiliaries in prefabrication and preforming procedures. The laser welded and plastic-covered face-bow.

The quad-helix appliances. Special application of- each of these appliances is also needed.

The bumper or buccal bar. This large round wire is adaptable for bumper are in the lower arch and can be used in the upper arch as a traditional “E” arch, particularly for rotation, expansion, or contraction of upper molars.

The lingual retainer bar. This 0.038 inch blue Elgiloy bar is adapted and was assigned for making the 4/4 retainer directly in the mouth.

Birth of “utility” therapy. As a consequence, double tubes for the lower molar were designed. The utility arch was born as a new approach to treatment. This arch was so named with the observation that this approach offered a wide range of usefulness and served much as a wide variety of uses in a technique control and treatment of lower incisor overbite by intrusion, therefore, also was introduced as a method of treatment in nonextraction



cases (**Fig. 13**).

Fig. 13. A diagram of common set up for a class II div 2 cases, Twin buccal tubes and the upper triple buccal tube

Deep bites could now be treated to the level of the premolars rather than by premolar extrusion. This made anchorage appear in a different light. The true occlusal plane was drawn through the buccal occlusion and not the

bisection of the incisor overbite (Fig. 14, 15 represent a patient treated according to this theory.)

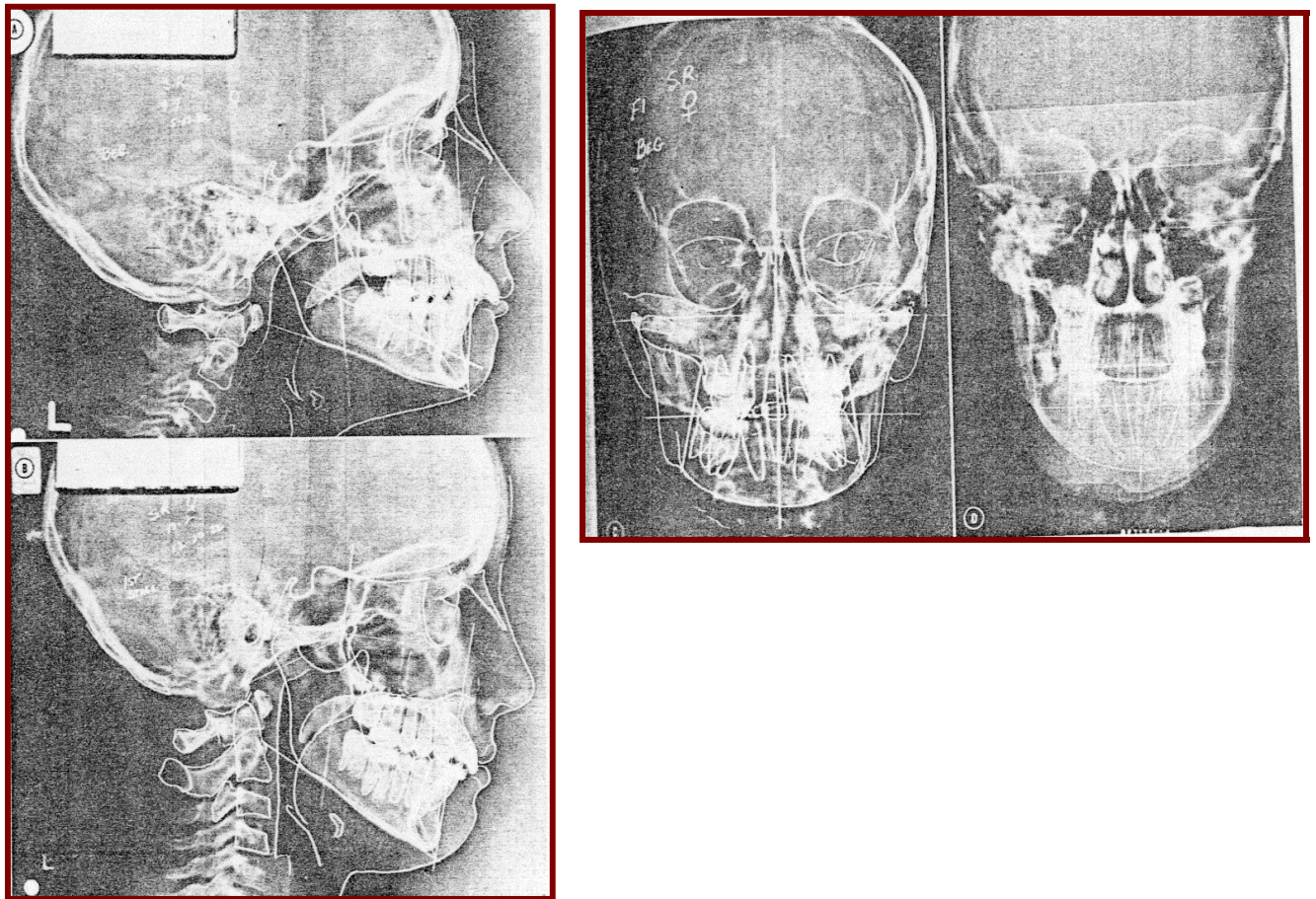

Fig. 14

Fig. 14. Patient S. R., a girl, from the ages of 9 years 7 months to-12 years 7 months. A. The beginning condition of the deep-bite. Class II, Division 1, with crowding in both the upper and lower incisors. B. The case after the initial expression of the utility arch and the headgear. Note that the convexity has been reduced from 6 mm. to about 1-5 mm in this stage. The patient still has lip strain; this is the conclusion of the first stage. C. the buccal sections banded, a continuation of the upper headgear, and the patient now ready for canine retraction off buccal sections in the upper arch. D. The case following the use of intermaxillary traction on the buccal sections; the teeth are banded in preparation to overtreatment.

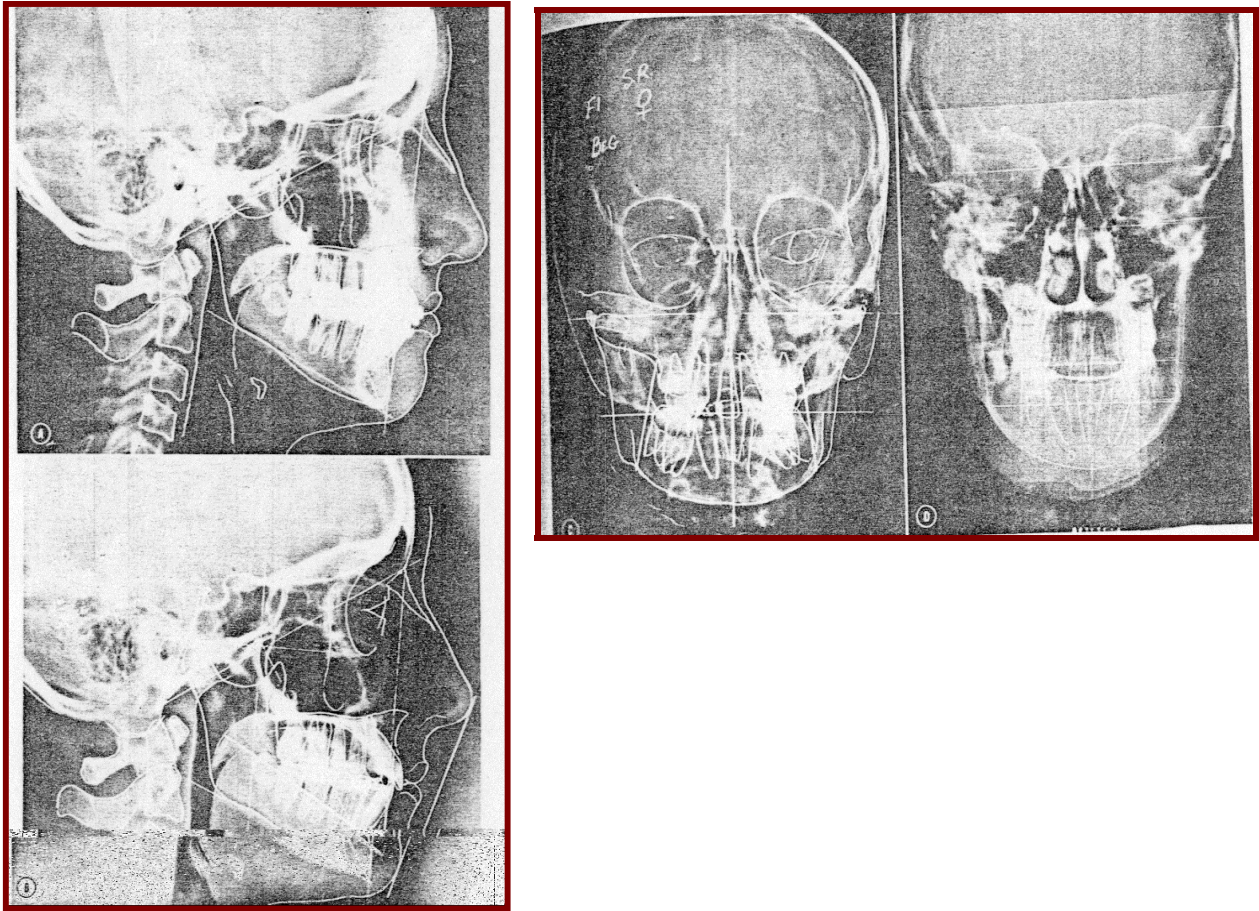


Fig.15

Fig.15. Patient S. R. A, The over treated stage showing the patient brought almost to an end-to-end relationship with full-banded therapy exercised; the patient is now ready for progressive debanding and space closure. Note the flattening of the denture from now to' retention. B. shows the patient wearing a fixed retainer from premolar to premolar in the lower arch. It shows an intermaxillary relationship that is holding and a convexity of 1 mm, together with the lower incisor to the APo plane of 1 mm, which is the peak of the curve of idealism in the treated orthodontic case. C, Frontal view with the nasal cavity narrowed and the upper arch narrowed. D. Frontal head film after treatment showing a good potency in the airway. The patient is holding well in retention.

Reduction of wire sizes. By this time the size of the wire was reduce to a 0.016 inch square to be used routinely in the 0.018 by 0.030 inch Siamese bracket. This technique and appliance provided a method for maintaining three dimensional control at all times, especially at the very

beginning. A return of Angle's original principle of three-plane controlled forces throughout treatment was made. By employing the 0.016 by 0.016 inch blue Elgiloy utility arch with incisor depression, upper incisor extrusion was avoided during space closure incisors traction and intermaxillary traction. Techniques were designed to prevent the elongation of the lower molars (just contrary to the prescribed effect of the Class II activator). In addition, an effort to prevent some of the extrusion of the upper molars was also made in certain open-bite or long-face cases during treatment. New designs in the extraoral appliance were made for checking extrusion of the maxillary molar.

Summary of bioprogressive development

Industrial technology in orthodontics led to preformed bands. With the development of prewelds, the field gradually moved away from one simple bracket or tube to a torque-tip rotation setup for individual teeth. With these developments, the same general philosophy was extended into providing preformed continuous arches, performed sections, and predesigned modules to further eliminate work at chairside while increasing control, efficiency and standardization.

As it was realized that orthopedic change was possible and that maxillary alteration could be controlled, new application of the headgear was made. The upper incisors were deliberately not banded until the later phases of treatment. When it was observed that any of the teeth could be intruded, deep-bites were treated in the level of the premolars rather than extruding the posterior teeth which rotated the mandible backward. As it was realized that permanent expansion was possible through the premolar and molar areas and that changes in arch depth could be quite significant to the

prognosis, a whole new attitude developed with regard to sophisticated treatment planning.

Anchorage considerations

Although sixty features of this technique have been listed, for the purpose of anchorage consideration only five major distinctive qualities are covered here. These are orthopedic or skeletal alterations, the use of growth, the concept of cybernetic feedback in planning, and muscle considerable. Although cortical bone was discussed in Part I, more respect and discussion for cortical bone is thought to be important enough to warrant further attraction.

Extraoral traction (skeletal anchorage). The normal lower incisor varies but balance homeostatically to both jaws (Fig. 16).

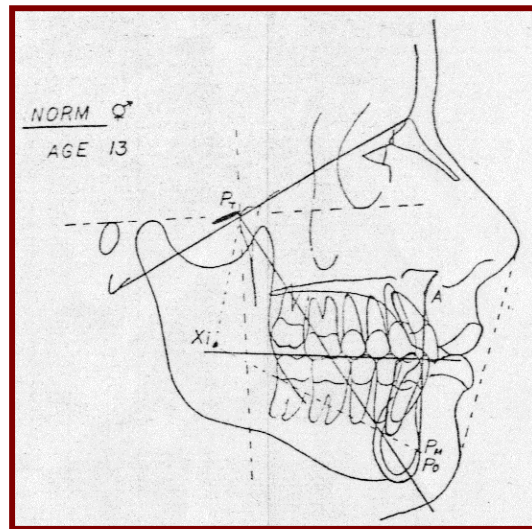


Fig.16.

Fig.16. The 13-year norm as programmed in the computer. At age 13 there is very little morphologic difference between males and females. Cut-offs for growth start at age $14^{1/2}$ for girls while in boys growth continues to the average age of 19. Note that the lower incisors at -1 to -2 mm. ahead of the APo plane.

The incisor is conveniently measured between pogonion and point A (the anterior limit of the denture base), from which areas the mouth muscles originate. These points change and are changeable with treatment. Thus, the calculation of original anchorage needs is related to two skeletal factors—the mandible (represented by Pm) and the maxilla (represented by point A). The essence in planning is the consideration of skeletal relations that will be present at treatment's end and at majority together with functional equilibrium of the lips.

A first major factor in the calculation of anchorage needs is the determination of the tooth movement needed for the lower incisor. This calculation starts with the amount of orthopedic change desired in point A or a change in convexity (fig 17).

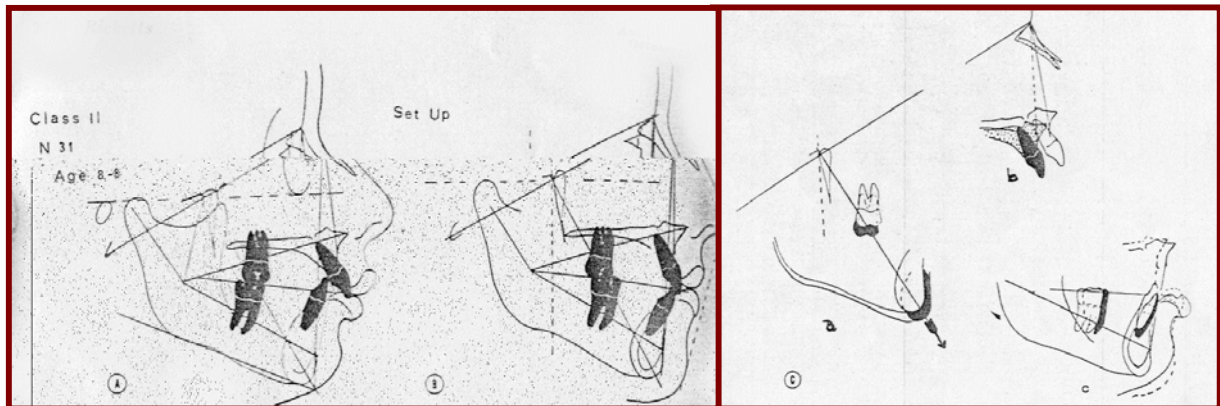


Fig.17

Fig.17. A. The composite of a group of thirty-one patients at age 8 years 8 months selected for Class II, high convexity. In comparison to the normal composite for that age the mandible is slightly shorter and reproduced and the maxilla is slightly protrusive, suggesting that class II malocclusion is a combination of both mandibular and maxillary problems. B, A cephalometric setup for the average of that group with 2 years of natural growth added to include changes for 2 years. Note, for the ideal, the reduction of the convexity and the placement of the lower incisors at +1, 22 degrees to the APo plane, which satisfies the esthetic equilibrium of the soft tissues. C, The analysis of changes needed for treatment in the foregoing typical class II case. In the chin growth is downward and forward 5.2 mm. and the facial axis is not changed. The upper molar is moved approximately 4 mm. downward and 2 mm. backward. Note, in b, the alteration of

the palatal and the movement of the upper incisor together with the palatal, as would be exhibit by the use of cervical traction in the condition. In c the before and after treatment tracings are superimposed over the corpus axis at Pm. Note that the lower incisor is introduced and brought forward; the molar is shifted forward approximately 2 mm. to account for the arch-form that usually accompanies treatment. Note also the relative change in the cant of the APo plane of point A is brought backward over the chin.

In a growing patient, however, the need for skeletal point A alteration is first contingent upon the amount of convexity reduction caused by mandibular behavior. The learned orthodontist is therefore obliged to make some sort of estimate of ultimate facial morphology at maturity; whether he calls it is prediction, a prognosis, or whatever.

The amount of change desired in the midface (point A and also the soft tissue nose) affects the decision for the choice of direction of force, its duration, and the timing of extraoral anchorage. Certain appliances are not known to affect skeletal behavior; others have been shown to produce effects. The needs decided upon affect the decision for anchorage preparation and amount of force to be employed later with maxillary traction. The convexity factor is to be considered even in simple Class I extraction therapy. Therefore, a cephalometric setup – or at least, the orthopedic thought form—is required in practically all cases for complete sophistication (Fig. 17, B).

Natural growth as a factor in dental anchorage. Natural growth expectancy – if understood—is a primary basis for planning. Orthodontics involves a plan for either maintaining or moving the molar teeth. This is obvious in Class II and Class III cases, but even in Class I cases with

extraction an issue may revolve around the amount of slippage forward of molars permitted in space closure (fig 18).

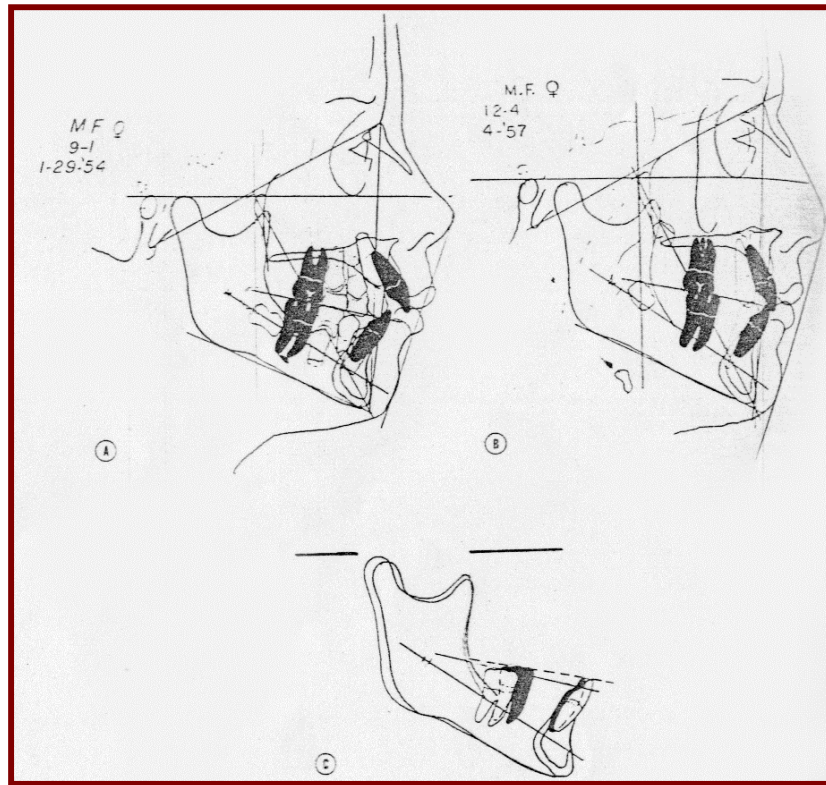


Fig. 18

Fig. 18. - Patient M. F., c girl. A, At age 9 there is a Class I malocclusion with open-bite crowded dentition treated with modified secondary edgewise in 1954. B, The effects of intermaxillary elastics with slippage and elevation of the lower molar as a result of space closure and Class II traction. C, The behavior of the occlusal plane as a result of extraction and space closure. If the bite were closed, the occlusal plane would probably have tilted extensively.

Very simply, the effort was made to determine the contribution that growth (or physiologic rotational change) can make toward the correction or to the detracting of the case . Use of the growth forecast plus the added; visualized treatment objective in a graphic form results in the treatment design. From this the clinician may determine whether an arch needs to be moved or left alone

Mandibular growth contributes to anchorage planning in that the jaw movement through carries the entire arch and thereby reduces lower anchorage need. On the other hand, unfavorable growth or behaviors increases anchorage problems and further complicates the plan. Growth, included in the setup, is therefore equated to mechanical anchorage and is a very real phenomenon. A Treatment design with cephalometrics is quite fundamental even when no growth is expected or when the patient is an adult or a growing child with a Class I malocclusion (Figs. 19 and 20).

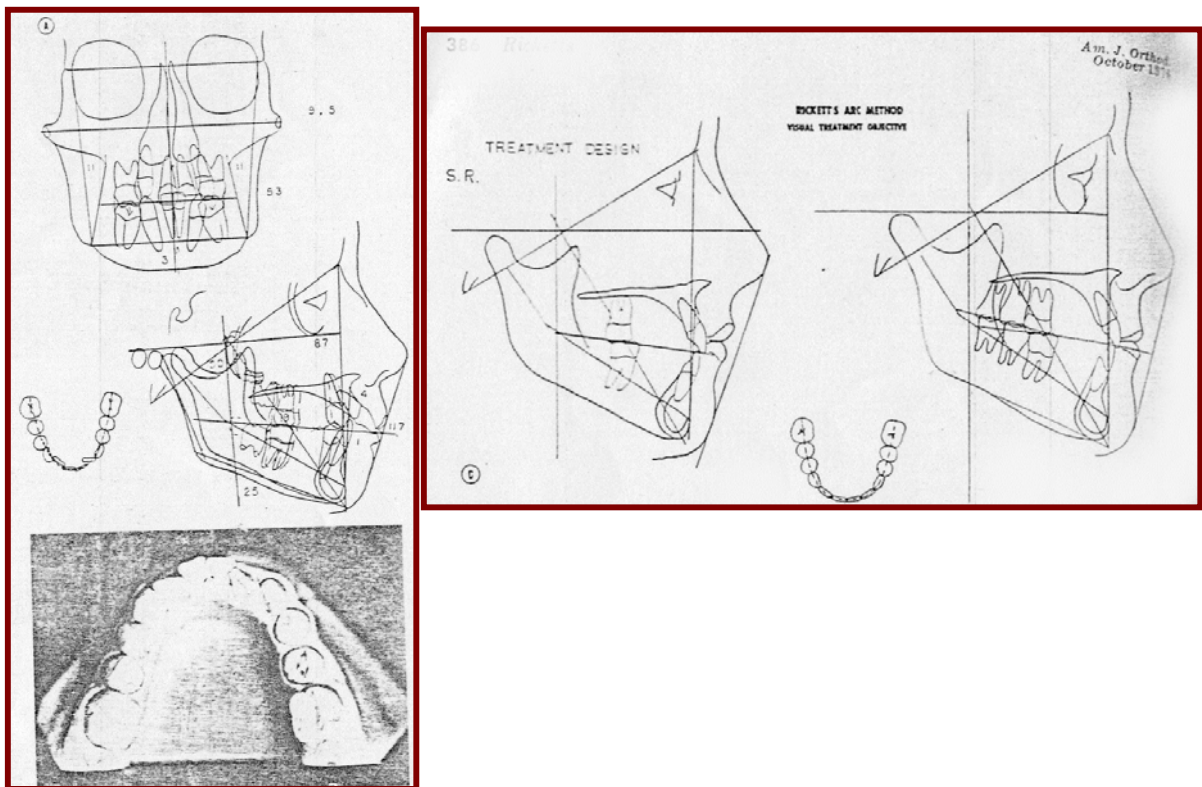


Fig. 19

Fig. 19. A, Renderings of Patient S. R. with the arch form and length as copies from the wax impression or the photographic processed copy of the cast as shown below. Note the 4 mm. convexity, the elevation of the lower incisor, and the excessive maxillary dental protrusion. C, A considering of the short-range forecast with the treatment design. D, The long force cut with ultimate arch form and size relationship based upon requirements of the case. Note questionable third molar space.

Anchorage needs are further complicated by two dental factors: the needs of the upper arch and the needs of the lower arch.

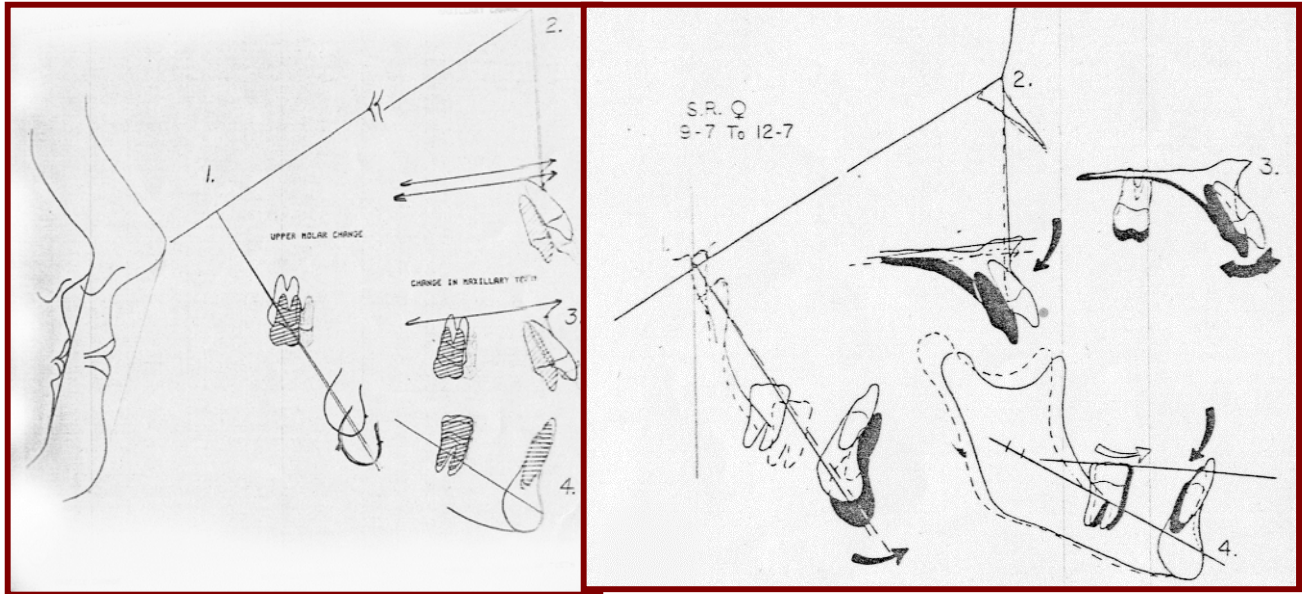


Fig. 20,

Fig. 20, A. The treatment design for Patient S. R., a girl, at age 9.54, constructed from comparisons of beginning, short-range, and long-range prognoses. The treatment alternatives on the right side will be noted, with certain findings programmed for treatment as required by patients of this kind. On the left is a comparison of the esthetics results at maturity. Note that the upper molar is to be moved backward approximately 4 mm. as the chin is growing forward and downward (in position 1). Note from position 2 that the maxilla and upper incisors are moved distally. Note also the change made from alveolar (in position 3). In position 4 the lower incisor will need to be intruded, while the lower molar needs to be stabilized. The treatment plan consisted of starting with the headgear on the upper arch and a utility on the lower arch, followed by continuing treatment with banding on the premolars in the lower and a section in the upper. This was followed, in turn, by a utility on the upper with intrusion and Class I intermaxillary fraction on the upper arch, leading up to idealization and finalization with progressive stripping. **B.** The actual analysis of Patient S. R. as treated, showing the strong relationship between the treatment planned by the computer and that actually produced. Compare the computer rendering to the actual changes as produced at short range (3 years as against 2 years in the plan).

Muscular effects on anchorage. Another major factor in anchorage is the observation of muscular anchorage—muscle, first of all, from the labiolingual or buccolingual complex as demonstrated by the bumper techniques but further the kinetic chain of muscles concerned with the opening or closing of the bite and the rotation of the mandible. Physiologic stabilization of the mandible therefore, becomes a part of the consideration in applying a technique for treatment.

It appeared from detailed cephalometric study that the lip was strong enough to interference the entire dentition to a position more backward than anticipated normally.

Later work in a series of clinical experiments led to the use of 0.045 inch wire placed around the arch and downward toward the sulcus; this was labelled “bumper.” Observations of that technique led to the conclusion that the lower lip alone was effective enough to move the lower molar distally, followed by the drift of lower premolars. This was clear evidence of the effectiveness of the perioral area not only to retract the anterior teeth but a inhibition of forward development of the entire lower denture in anchorage (Fig 21, A). The bumper came to be used infrequently because the utility trades the incisors and increases arch length (Fig. 21, B)

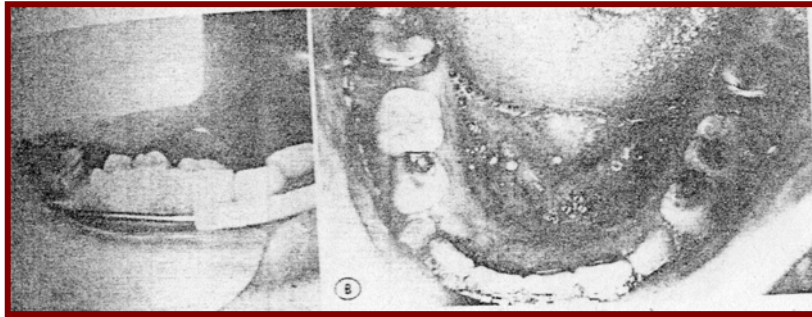


Fig. 21

Fig. 21. A. The effect of a lip bumper in moving the lower molar distally. Note that the 3 mm. of space opened up between the lower second deciduous molar and the permanent molar as a result of the lip force from a 0.045 inch wire covered with and stopped at the mesial aspect of the molar and placed near the crevice third crown of the lower incisor. B, Similar effect on the lower first permanent molar in the patient treated with only the utility arch. Intrusion and advancement of the lower against the lower lip actually moved the lower molar distally, as shown on this.

Cortical anchorage as a fundamental factor. The fifth matter of direct concern is cortical anchorage. Compact bone not only offers resistance to the tooth movement but, conversely, it can be used for anchorage and is recognized and employed to advantage. This is accomplished by situating the teeth behind the heavy compact elements of bone so that the pressure of the root is almost in direct contact with bone incapable of easy backward resorption.

This has proved to be a main source of anchorage for intermaxillary elastics for anchorage for retraction of teeth when it is desired that units within the same arch be moved (Fig. 22).

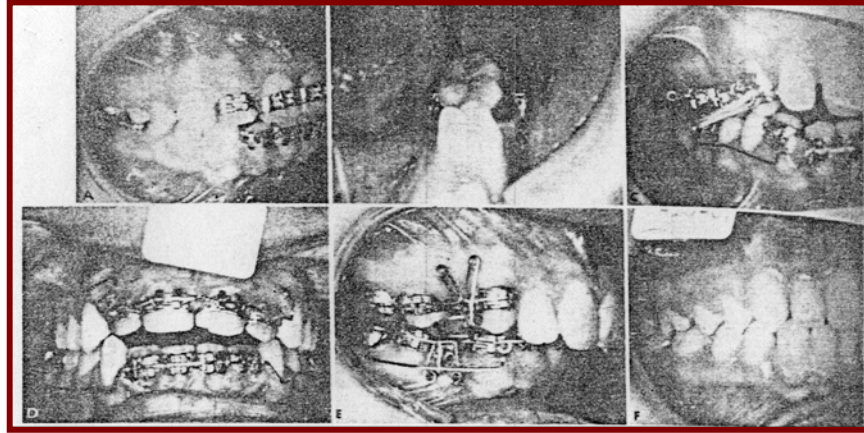


Fig.22.

Fig.22. A, Case demonstrating the effect of cortical bone on anchorage. This was a full Class II, Division 1 case treated without banding of the premolars. Note the anchor position of the lower molar. At one time 500 Gm. on each side was exercised in intermaxillary elastic pull. B, Torque (22 degrees) double-tube design with utility engaged. C, Another case showing intermaxillary elastics used off the buccally torqued lower molar while at the same time the lower canine is being ligated downward as the upper buccal section it being reduced. D, Upper and lower utilities working to intrude the upper and lower incisors as elastics are employed to reduce the Class II malocclusion. Note that premolars are as yet not banded. E, Buccal root torque on molar also helps to prevent forward displacement during space closure in extraction case. F, Uprighting of molar will tend to occur naturally with normal forces of occlusion, but finishing should be conducted to preparation for this event.

As movements were routinely studied, teeth did not always move as had been anticipated under usual prescriptions. In the analysis of these situations it was discovered that the roots did not move when teeth were brought into high pressure contact with the cortical plate of bone. Consequently, a study was conducted in which cortical bone was investigated at different stages of development. As the lower molar was tipped buccally at its roots and trapped beneath the external oblique ridge of external alveolar plate of bone in the mandible, better stability was observed (fig.22). Anchorage, therefore, seemed to be effectively enhanced by a

procedure for holding or producing “buccal root torque” while at the same are slightly expanding.

As the lower molar was tipped distally, the root seemed to be trapped beneath buccal plate and consequently became the anchor site. The crowd was observed to move distally by a tip-back bend on the molar at the same time that it was buccally expanded, particularly with the utility arch free of premolar banding (fig. 23).

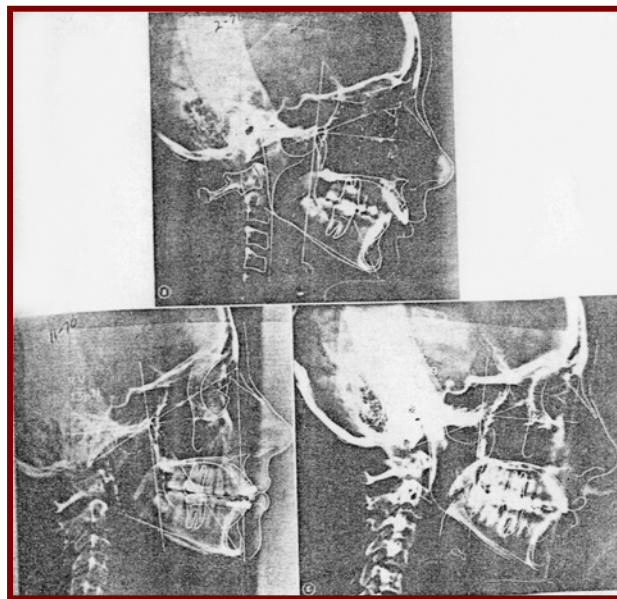


Fig. 23

Fig. 23 *The analysis of Patient R. V., case shown in Fig. 45, A Class reduced by elastics and no premolars banded. A, Before treatment, at age 13 years 2 months. B, after class II traction, at 13 years 11 months. C, Four years later at 17 years 8 months. D, Analysis shows orthopedics of maxilla and only very slight displacement of molar with oral root movement during uprighting.*

SUMMARY

While edgewise was the background, sufficient departure from traditional edgewise therapy has been made to warrant a new label, “bioprogressive therapy. It was so named because of the practice of progressive banding and a planned progression of events in sequential order. Eight steps usually form the frame of reference. Ironically, it can be applied in the very young and in the very old.

In order to fully apply the recommendation of the proponents of this method, mechanical forecasting, physiologic forecasting.

Size 0.016 by 0.016 inch blue Elgiloy wire is commonly but not extensively used. Loops or forms are bent in the wire for lighter and more continuous pressure on teeth to be moved. Soldering of auxiliaries has been eliminated as well as the heat treating of wires. The 0.016 by 0.016 inch to 0.016 by 0.022 inch yellow. Elgiloy is used for detailing near the end of treatment. The 0.018 by 0.022 inch is the largest wire employed, and it is used for spanning distances between teeth in the progressive debanding phases.

Anchor teeth are stabilized against cortical bone; hence, cortical anchorage. In order to position and control the teeth behind or away from cortical bone or against away from muscle or to intrude into or extrude away from the bony alveolus three-plane control is utilized. A limited use of round wire employed with this technique except for specific isolated conditions in which there is place for tipping or simple alignment and rotation of teeth. Used as a triple-control technique, the progressive method excels in proper overtreatment and for, delivery of anchorage.

A continuous arc-h is broken up into segments or sections so that movements in desired planes of space are not complicated and anchorage can be shifted in favor of the desired move.

The technique usually involves orthopedic correction, particularly in the maxilla, when such corrections are needed. When this technique is combined with the activator or mandibular posturing devices, an application can be made to provide an anchorage approach to include growth and maxillary and mandibular orthopedics.

Muscle anchorage definitely is considered in anchorage planning and utilized in its fullest application, even to posttreatment rebound.

The leveling of the arch by the extrusion of the premolars is considered to be contraindicated. Thus, intrusion of anterior teeth, either upper or lower, is a practiced art with a bioprogressive technique. With this approach, a tremendously wide range of flexibility is possible, and overtreatment is the byword. This flexibility permits the clinician to overcome tooth-size discrepancies, as overtreatment of a part of the arch can easily be attained.

Another virtue of the “progressive” approach to treatment is particularly thought provoking: absolute standardization is not appealing and is the aim. Rather, a body of principles has been developed. In depth diagnosis, prognosis, and designing are advocated for patient, depending upon his particular individual needs.

Visual objective “designing” with cephalometrics as a reference for planning is strongly recommended, although “intuitive planning” is

practiced with this method as well as others. In applying specific progressive therapy to its greater potential, however, the biologic and mechanical principles are put together cephalometrically for each individual patient only after his unique personal requirements are determined. In this manner, the philosophy and science of orthodontics can be practiced with the spirit of the artist.

UTILITY ARCH

Every major approach to orthodontics has had one characteristic which stands out in the minds of orthodontic clinicians universally as a medium for describing that particular approach or technique. Probably the most recognizable single entity in the bioprogressive therapy would be that of the UTILITY ARCH. It forms the base unit around which the mechanics in all types of cases can be employed. It is the catalyst which ties together all the different types of mechanotherapy.

The utility arch was born following the observation of depressed lower, second bicuspid in extraction cases. Following the move to lighter forces into the range Storey's recommendations from a studies in 1952, it was not until about 1958 that oblique x ray studies showed, with sectional retraction, the lower second bicuspid could not withstand the tipping force against the first molar during unusual space closure.

It has been assumed, based on previous histological work and the ascertains of biologists and histologists in the field, that intrusion of teeth was impossibility. During space closure with loops, however, the canines often tipped backward excessively, particularly with rapid closure. In addition, the molar and bicuspid as a unit both tipped together. Actually, this action intruded the bicuspid.

In seeking a method to maintain an upright position on the lower molar and to thereby prevent bicuspid intrusion and the further collapse of the bite as many had previously witnessed in extraction cases. Ricketts made an attempt to employ the four lower incisors as anchorage in some manner. Single tubes were still in use on the lower molars. So, a simple .016 round

wire was formed as a continuous arch, placed under the second bicuspid brackets and loped over the molar tubes at the end, to be locked down behind the extension of the section retractor. This move before activation put the forward part of the arch downward toward the sulcus and, as it was raised and engaged in the lower incisors, it exerted an elongating affect on the bicuspid as a lever against the molars.

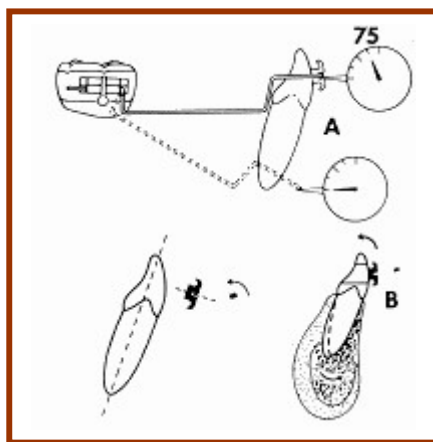


Fig. 1

Fig 1 *When the lower utility arch is engaged in the lower Incisors, approximately 50 to 75 grams (A) of Intrusive force should be applied. Slight labial root torque (5° to 10°) allows the lower Incisor to avoid cortical bone in its intrusive movement (B).*

This set up served to keep the anchor unit upright. In observing the behaviour of this mechanical arrangement it was soon discovered that the lower incisors tended to tilt forward, but also they were seen to depress. Careful examination of intraoral x-rays and cephalometric tracings confirmed that the incisors had intruded. This rapid movement tended also to extrude the canine and tip it distally as the sectional was employed at that time.

Simultaneous with that development Ricketts attempted to reduce the wire size and character together with loop designs to keep the force within the 150 gins limit hypothesized then for cuspid retraction. The need for

lighter wires with milder forces had suggested the need for narrower bracket slots. A move down to the .018 bracket was made after certain experiments, and because of the discovered need for a second wire or section to operate in a different plane of space, the dual or double tube was initiated. Also in order to control the flaring of the lower incisors, the force was further reduced and a .016 x .016 blue Eligiloy was designed. Because of the span in the arch designed. Because of the need for a longer level with lighter force, it took the present form of the U arch. A step mesial to the molar was made as a buccal bridge section was formed together with an anterior step to reach up to engage incisors. In the beginning, it was only to be used together with retraction sections in extraction cases.

However after having made the observation of intrusion of the lower teeth, further applications of this design were made. Tipbacks against the molars with light wires began to show also an intrusion of the lower canines. The incisors remained in deep bite as it then became a greater problem to intrude the lower incisors through the depressed canines without again extruding them and tipping them distally. Obviously it was almost an impossibility to work these teeth simultaneously in the most desired positions in both planes of space. The utility arch then became the method of choice as a starting appliance in deep bites or with crowded lower anterior conditions.

Multiple loops were designed to engage the anterior teeth in crowded cases and subsequently it was seen that a wide variety of conditions could be handled. It could be used to gain arch length it could be used to close arch length. The loops could be incorporated at the location of any of the bends because the form of the arch itself constituted long vertical loops on either

side.

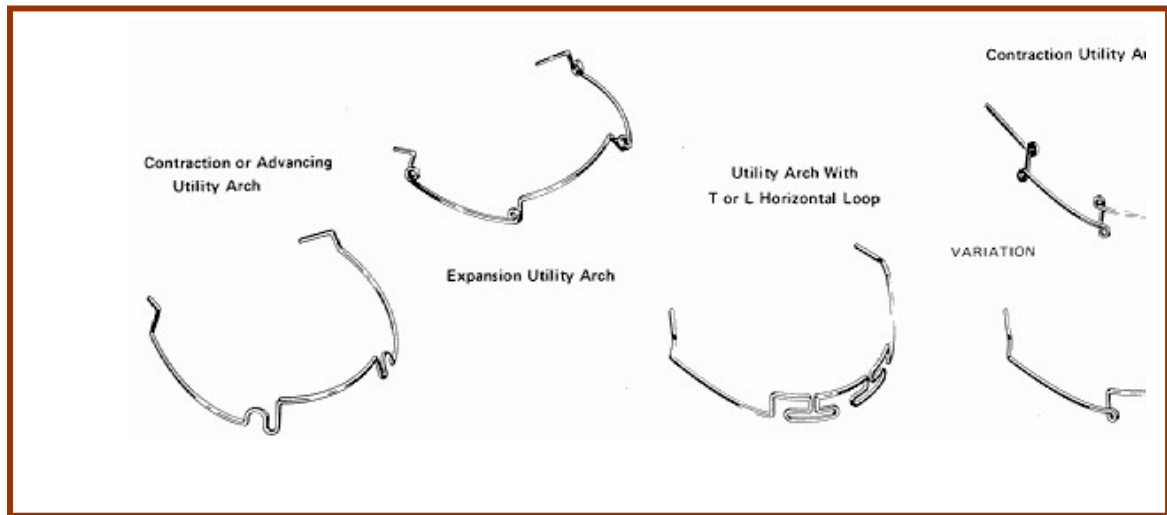


Fig. 2
Fig. 2 Mandibular utility arch

It was particularly amenable to intraoral adjustments. For this reason, it was given the name utility arch, simply because of its utility. It therefore became the starting appliance for class II division 1 and class II division

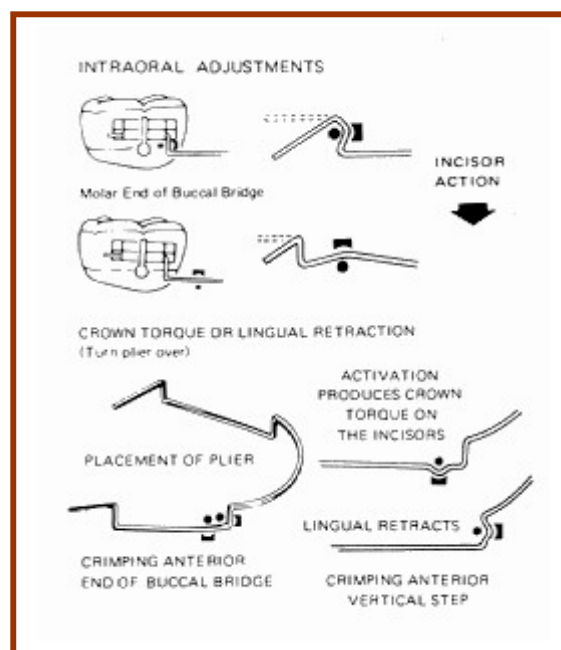
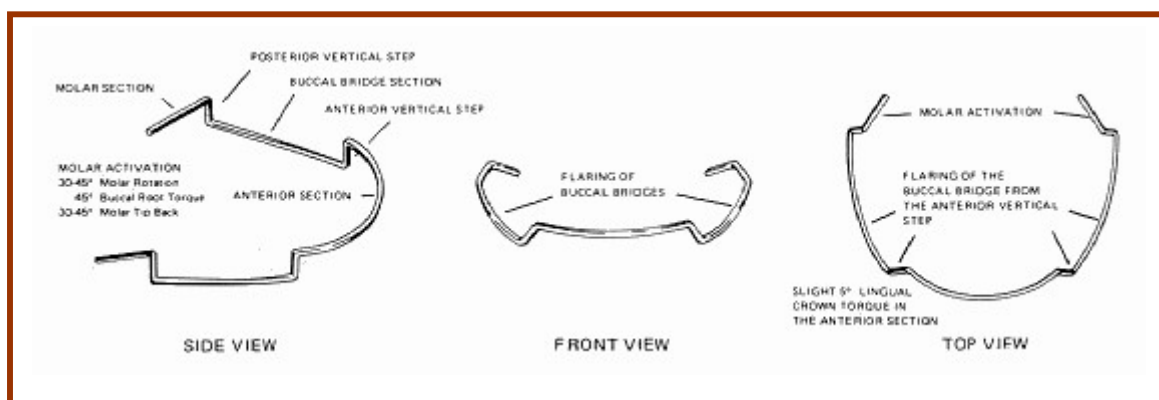


Fig 3 Intraoral adjustments

It becomes the appliance in the mixed dentition case in order to avoid most of the need for banding of the primary teeth.

Many clinicians tried to abuse the use of the utility as did Ricketts in the beginning. It is hard to realize that a .016x.016 blue Elgiloy wire will offer sufficient strength and stability to do the job for which it is proposed. Just because the utility arch is a starting appliance, it should be understood that it can be employed again any time during the course of treatment to regain lost overbite due to retraction of anteriors. A wide variety of stock utility arches are available and can be adapted into routine daily practice.

**Fig 4 Utility Arch**

TYPES OF UTILITY ARCHES: -

Although many configurations for utility arches have been described four types of arches can be defined, based on their use.

Passive Utility Arch

The Passive Utility Arch (Fig. 5) is used for stabilization or space maintenance in either the mixed or permanent dentition. A passive utility

arch can be used in the mixed dentition to maintain arch length during the transition of the dentition. In many respects, the utility arch acts in the same manner as a lingual arch because the passive utility arch prevents the mesial migration of the molars, particularly in the lower arch. The utility arch also may influence the eruption of the posterior teeth by holding the cheek musculature away from erupting teeth, allowing for spontaneous arch widening.

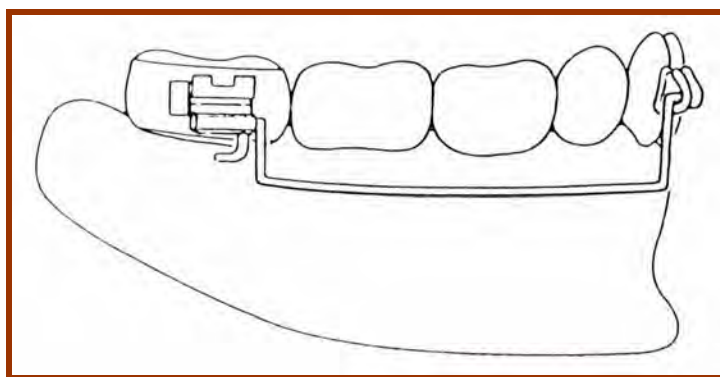


Fig. 5. *Passive utility arch. Note that the posterior vertical segment fits snugly against the auxiliary tube of the lower molar band.*

The passive utility arch also is used in the permanent dentition, primarily for the maintenance of anchorage. In non-extraction patients, the passive utility arch is particularly useful after molar distalization has been completed

In many techniques (e.g., Wilson distalizing arch, NITI coils, distalizing magnets), a large space is opened posterior to the upper second premolars as the first permanent molar is distalized. One of the challenges to the clinician is to maintain molar anchorage while the upper premolars are retracted. In combination with a transpalatal arch, extraoral traction, or a Nance holding arch, a passive utility arch can be used to incorporate the

anterior teeth as anchor units . “Driftodontics” (i.e., tooth movement produced without active orthodontic forces being applied) then are used to allow the premolars to migrate posteriorly without active orthodontic treatment.

Passive utility arches also are used as anchorage appliances in extraction cases . Prior to canine retraction, a passive utility arch that extends from the first molars to the incisors is placed. Canine retraction then is initiated, using the incisors as additional anchor units.)

Activation. No activation of the passive utility arch is required.

Intrusion Utility Arch: -

The intrusion utility arch (Fig. 6) is similar in design to the passive utility arch, but this arch is activated to intrude the anterior teeth (Otto et al., 1980).

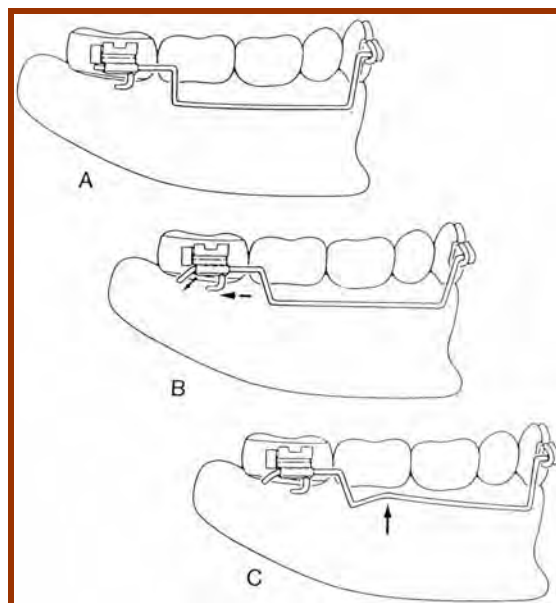


Fig. 6. *Intrusion utility arch. A) The intrusion utility arch first is bent passively to the existing occlusion. Note that the posterior vertical segment lies at least 5 mm ahead of the auxiliary tube on the lower first molar. B) Retraction of lower incisors can be produced by grasping the distal end of the molar segment with a pair of Weingart pliers, pulling the segment posteriorly, and then turning the segment gingivally. C) Intrusive forces can be produced by using a loop-forming*

plier to place an occlusally-directed gable bend in the posterior aspect of the vestibular segment.

After activation, a light continuous force is delivered by the long lever arm from the molars to the incisors. The utility arch should produce 60-100 gms of force on the lower incisors, a force level considered ideal for lower incisor intrusion (Bench et al., 1978). The overall effect is intrusion and possible torquing of the lower incisors as well as a tipping back of the lower molars. Expansion or contraction of intermolar width can be achieved by widening or narrowing the archwire. Molar rotation is produced by appropriately activating the molar segments of the arch.

Activation. Two types of forces can be produced using this design: retraction and intrusion. With a simple utility arch, a modest amount of incisor retraction can be achieved by grasping the end of the molar segment with a Weingart plier distal to the molar tube and then turning this segment gingivally after pulling the wire posteriorly through the tube (Fig. 6B). Care must be taken that the protruding end of the wire does not encroach on the soft tissue of both the cheek and gingiva. This type of activation prevents proclination of the lower incisors during intrusion.

Intrusion of the anterior teeth can be produced in one of two ways. First, the utility arch can be bent passively to fit the existing occlusion, as has been described previously. After ligating the utility arch into the anterior brackets, an intrusive force can be produced by placing an occlusally-directed gable bend in the posterior portion of the vestibular segment of the archwire (Fig. 6C). A loop-forming plier, such as the 881 loop-forming plier (Masel Orthodontics, Bristol, PA), can be used for this type of intraoral activation. These loop-bending pliers must have a concave surface next to

the loop-forming portion of the plier; therefore, not all loop-bending pliers, such as omega loop-forming pliers, can be used for intraoral activation of the utility arch.

Bench (1988) has advocated an alternative method of activation of the utility arch to produce intrusion. This type of activation involves placing a tip-back bend in the molar segment. The tip-back bend causes the incisal segment of the archwire to lie in the vestibular sulcus. The intrusion force is created by placing the incisal segment of the utility arch into the brackets of the incisors. This activation creates a moment that allows for the long action of the lever arm of the utility arch to intrude lower incisors. It has been our experience that placing distal crown torque in the molar segment sometimes leads to a posterior tipping of the first molars. Thus, activating the utility arch by placing a gable bend in the posterior aspect of the vestibular segment (Fig. 6C) seems to avoid unwanted molar tipping. In the case of a maxillary utility arch, tipping of the molars also is reduced through the concurrent use of a transpalatal arch.

Bench (Bench et al., 1978; Bench, 1988) also recommends the placement of buccal root torque in the lower molar region to anchor the roots of the molars in cortical bone. This type of force also produces lingual crown torque that is counterbalanced by placing 10 mm of expansion in the utility arch in the molar region during appliance fabrication.

Retraction Utility Arch: -

The most common type of utility arch used by the senior author is the retraction utility arch (Fig. 7A). This type of utility arch can be used in either the mixed or permanent dentition to achieve retraction and intrusion of the

incisors by incorporating loops in the archwire anterior to the anterior vestibular segment.

Retraction (Fig. 7B) and intrusion (Fig. 7C) can be produced by activating the retraction arch in a similar fashion previously described for the intrusion utility arch. The incorporation of the loop into the design allows for a longer range of activation. Perhaps the most common use of the retraction utility arch is during the final stages of comprehensive edgewise treatment. In an extraction case in which the canines have been retracted, space opens distal to the upper lateral incisors. In non-extraction cases, a similar but smaller space is often open distal to the lateral incisors due to molar and premolar rotation as well as due to Class II mechanics.

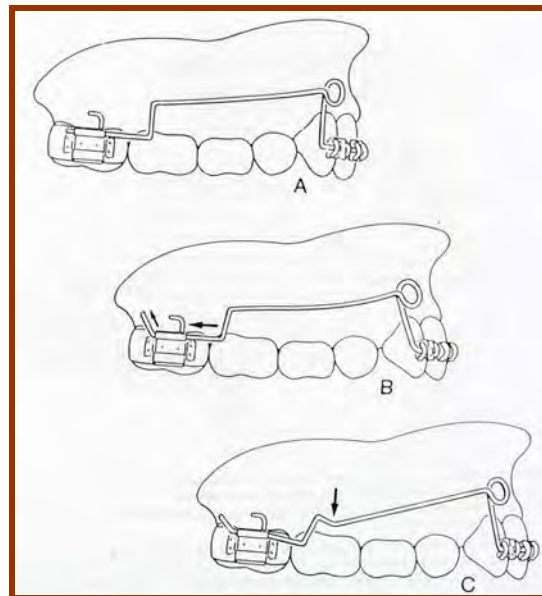


Fig. 7

Fig. 7. *Sagittal view of maxillary retraction utility arch. A) Before activation. B) Retraction of the molar segment of the archwire. C) An occlusally-directed gable bend has been placed in the vestibular segment of the archwire to produce incisor intrusion.*

A retraction utility arch can be used to close this space by retracting the upper incisors. This arch also provides the necessary intrusion that often

must precede the retraction of anterior teeth.

The retraction utility arch is used less commonly in the mandible. However, it may be used in cases of dentoalveolar anterior crossbite in which there is some proclination and spacing of the lower incisors. In these types of cases, the anterior crossbite can be corrected using a retrusion utility arch, while the spacing between the incisors is eliminated through the use of elastomeric chain.

Utility arches also can be combined with bonded orthopedic appliances. For example, buccal tubes can be incorporated into a variety of acrylic splint appliances (e.g., bonded RME, Herbst). A utility arch can be fabricated so that it is anchored posteriorly in the buccal tubes of the bonded appliance and then can be used to move the anterior teeth in all three planes of space.

At this point, a 90⁰ bend is placed with a 142 arch-bending plier. A loop-bending plier is used to place a loop in which the end of the anterior leg crosses behind the posterior leg. After a 5-8 mm vertical segment is formed, another right angle bend then carries the wire across the anterior teeth. A gentle anterior contour is placed in the wire to simulate arch form, and an offset also is placed in the canine region.

On the other side of the arch, the anterior vertical step is created in the interproximal area between the lateral incisor and canine. The retraction loop is formed with the loop-bending plier and then the loop-bending plier (rather than the arch-forming plier) is used to create the 90° bend in the horizontal vestibular segment. The wire then extends to the posterior vertical segment at the middle of the second premolar. In most instances, the length of the

horizontal vestibular segment can be estimated, based on the length of the horizontal segment on the opposite side. Care must be taken to make sure that the utility arch does not encroach upon any fixed appliances present, including ball hooks or Kobayashi hooks.

Activation. As with the intrusion utility arch, there are two possible types of activation. First, a Weingart plier can be used to grasp the extension of the utility arch posterior to the auxiliary tube. The wire is pulled 3-5 mm posteriorly and then bent upward at an angle. Care must be taken that this protruding end of the utility arch does not impinge on the cheek or gingiva. Second, an occlusally-directed gable bend in the vestibular segment can be used to produce intrusion, as has been shown previously in Fig. 7C.

Protraction Utility Arch: -

The protraction utility arch (Fig. 8) is useful for proclining and intruding upper and lower incisors.

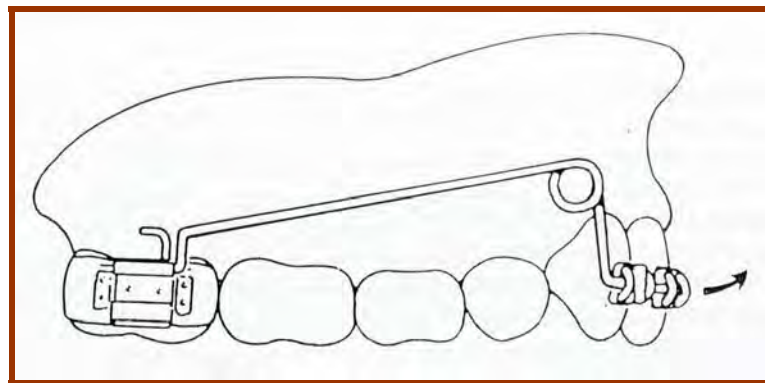


Fig. 8

Fig. 8. Protraction utility arch. Note that the posterior vertical segment is flush against the auxiliary molar tube. When passive, the anterior portion of the utility arch should lie approximately 2-3 mm ahead of the incisor brackets.

In the permanent dentition, it is used commonly for proclining and intruding maxillary incisors in Class II, division 2 cases, especially in

patients with an impinging overbite (Fig. 9).

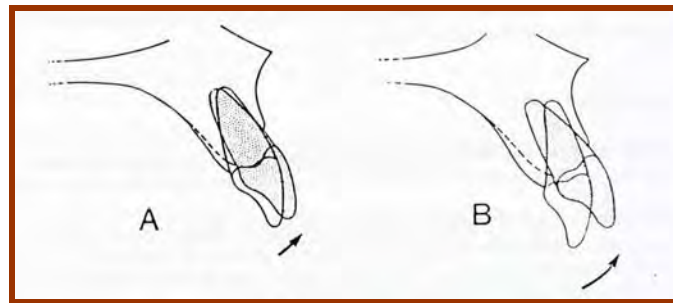


Fig. 9.

Fig. 9. *Movement of upper incisors using a protraction utility arch. A) Simple flaring. B) Protrusion and intrusion.*

This archwire is used to provide clearance between the upper and lower incisors to allow for placement of brackets on the lower dental arch. The protraction utility arch also is used during the presurgical orthodontic phase of treatment in patients undergoing a mandibular advancement to decompensate the position of the upper incisors.

This type of utility arch also is used during the mixed-dentition period prior to functional jaw orthopedic appliance therapy. In the case of Class II patients who have retruded upper incisors, brackets can be placed on the upper anterior teeth, and bands can be placed on the upper first molars (perhaps supported by a transpalatal arch). A utility arch can be used to procline and intrude the incisors as necessary. Often a simple intrusion arch without loops is needed in the lower arch.

The anterior vertical step is usually 5-8 mm in length, depending on patient tolerance. The incisal segment courses through the incisor brackets, and the utility arch is completed in a similar fashion on the other side.

Activation. When the protrusive utility arch is passive, the anterior

segment lies about 2-3 mm anterior to its ultimate position in the incisor brackets. The protrusive force is produced by tying the anterior segment of the utility arch into the anterior brackets. An occlusally-directed gable bend in the posterior aspect of the vestibular segment is used to produce intrusion.

The protrusion arch is reactivated by removing the anterior segment from the brackets, bending the posterior vertical step forward from 90° to 45° and replacing the arch wire in the brackets. Other adjustments can be made in both the anterior and posterior vertical steps to produce further activation.

CLINICAL PROBLEMS

By far, the major complications associated with the use of utility arch involve the soft tissue. One of the major difficulties in fabricating the utility arch, whether it is for the maxilla or the mandible, is in placing the horizontal vestibular segment between the gingival and buccal tissues. If the posterior step is made too long, or if the horizontal segment encroaches on the gingival tissue, the wire can become embedded easily. If the horizontal vestibular segment is placed too far laterally, tissue irritation and the buildup of fibrous tissue along the inside of the cheek can occur; In instances in which tissue irritation occurs in the areas adjacent to the vestibular portion of the utility arch, clear or grey sleeving (“bumper sleeve”) may be used to shield the tissue from the edges of the wire.

Another major area of concern is the formation of the loops of the retraction utility arch. If these loops extend too far into the vestibular area or protrude anteriorly, severe irritation can result and patient discomfort can occur. The patient should be given wax at the delivery appointment to aid in

the break-in period after the utility arch has been inserted.

THE QUAD HELIX APPLIANCE

(Innovation by Dr Ricketts)

The quad helix appliance is an evolution from a type of vulcanite appliance originally advocated by coffin. The plain w arch expansion palatal type of appliance originally was used by Ricketts to treat cleft palate conditions. It was particularly advantageous because more action could be gained in the anterior area than in the posterior area (or the reverse could be true depending upon the activation). Many problems were encountered in its early use, particularly when it was made in the laboratory on the cast. Very often the .040 gold wires employed originally would be annealed at the site of the solder attachment and the forces of occlusion would distort the appliance. The general form of this palatal appliance is similar in form to the basic Crozat maxillary appliance. Also about this same time in 1947, a button was being placed on the palate with half round tubes for the use by Nance for holding arches. Ricketts modified this by placing loops for back action and building in active rotation.

In the beginning it was assumed that this was simply a dental appliance but after the advent of suture splitting, Ricketts studied many frontal head films of patients treated with the appliance which suggested that nasal cavity had widened more than the normal growth expectations.

In order to widen the range and yield more flexibility Ricketts incorporated helix loops in the posterior loops at the start. Later two more were employed in the anterior part of the palatal arch. With the advent of preformed bands, it was decided that the appliance could be made directly, just as it could be formed in the laboratory. Because the appliance would be

reactivated before insertion, it was not thought necessary, to be adapted in the absolute manner as would be on the cast. Therefore the notion was formed that this could be performed and prefabricated which would assist in quality control, standardization and efficiency in operation, and it was labeled the quad helix as descriptive of the four loops.

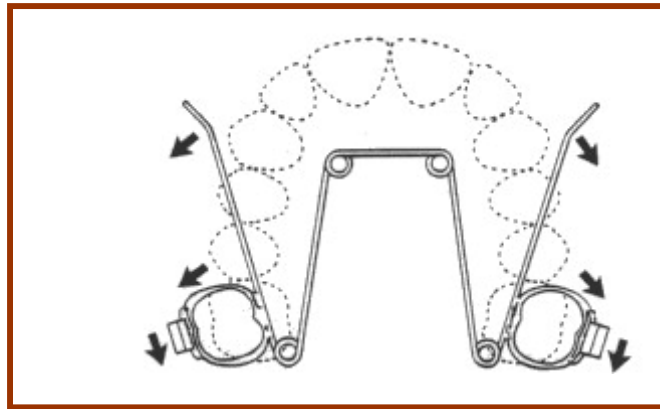


Fig1.*The quad-helix*

In the beginning, it was called two in one, three in one or four in one appliance. Because the appliance is made with preformed bands with tubes previously mounted, it can also be used (after it has been deactivated) for a face bow attachment. Used passively and without activation, it can serve as a holding appliance. However, with the arms usually expanded resting against the lingual surface of the crowns of the upper canines or at the cervical margins of the tooth, it is usually considered to be an expansion appliance plus a rotation appliance.

When a palatal bar is constructed forward and bent downward in the mouth, it also may serve as a thumb sucking habit breaking appliance. If spikes are introduced against the anterior section and pointed downward in the space between the teeth, it is used as a thumb appliance.

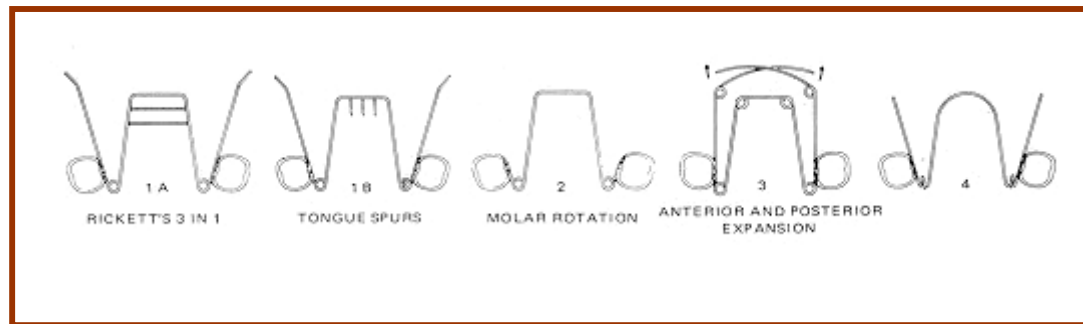


Fig 2. *Modifications of the quad-helix appliance*

If light spikes are soldered on the bar and extended downward, it can serve as a tongue thrust appliance. It can also be used as an anterior bite jumping appliance, or an appliance to unravel the crowding in anterior teeth when lighter palatal wires are extended to the anterior teeth. The basic appliance, therefore, has many uses and many forms or adaptations and is remarkably efficient.

Recent Research-

Dr Ricketts mentioned that the quad helix appliance exerts a palatal suture widening effect. It is slower and not as dramatic, but it separates the suture in pace with the speed of new formation of bone. As the frontal section of the laminograph x-rays were studied by Dr Ricketts, it appeared that new bone remodeling took place at a slower pace.

It appeared that after six months the effects of the jackscrew and quad helix were similar in extent of final nasal floor involvement.

One of the problem that was encountered with the use of the quad helix appliance, particularly used with excessive expansion, was that of tipping of the teeth outward. This could be guarded to some extent by torquing the roots buccally.

A fault with the use of the quad helix clinically is that the movements are often not excessive enough and are not retained long enough. A relapse in palatal expansion is often seen in the absence of improved nasal function, particularly when the tongue remains low in the oral cavity. Another hazard with this type of appliance was that it restricts space needed for the tongue. Care should be taken to adapt the wire at the time of cementation and the original activation and adaptation should be within 2 or 3 mm of the palatal tissues.

Practical application-

The following procedure was employed by Dr Ricketts for application of Quad Helix:

- a. Bands were placed on the upper second deciduous molars for the very young case or the first permanent molars. Particular care was taken to adapt the lingual surfaces of the bands because this was strong purchase area for this appliance.
- b. The most appropriate preformed band was selected. These sizes after research were designed in .038 Elgiloy. The objective was to develop 500 grams of force for orthopedic movement when desired. Also the .038 Elgiloy facilitates intraoral adjustment. The original cast was used and the wire is formed with the fingers together with the three prong pliers to adapt the wire to the needs of the patients.
- c. A white wax marking pencil was used to mark the soldering spots on the wire immediately in front of the posterior loops, depending upon the adaptation of the arms of the appliance.

- d. A solder stick was used to flow the solder on the wire. The band was picked up in the tongs and approximated as the low fusing solder was flowed in to the position.
- e. The amount of activation desired was placed on the wire.
- f. The appliance was cemented, making sure the bands were well seated. There is reciprocal action, so the appliance must be activated during the cementing procedure.
- g. A wide three prong pliers was used for final adaptation and activation.

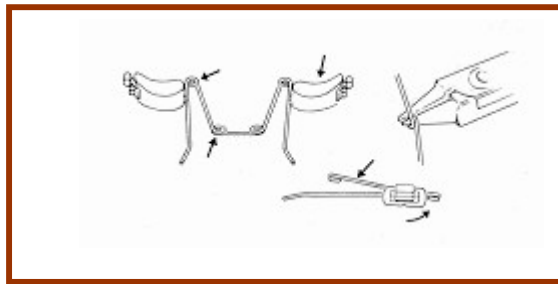


Fig. 3 *Initial activation of quad-helix appliance for insertion.*

Clinical Management-

A six week interval was usually observed before any further activation is needed. At the second visit, intraoral adjustments were made following which another six week period was observed. Activation was made by placing the pliers directly anterior to the posterior loop. The anterior arms can be adjusted independently of the molar activation by placing the pliers anterior to the molar.

Widening, contraction or uprighting the molars could be activated by pinching between the anterior loops. Usually only a little activation was made of the anterior arms and the wire is left out of contact with the anterior teeth until molar rotation was achieved. This was one of the outstanding features of this appliance because molar rotation is most often a problem.

Upper molar rotation could be gained immediately. Space was also gained very soon for the erupting side teeth, particularly the crowded upper lateral incisors.

Indications-

Several particular conditions thus seemed appropriate for this appliance by Dr Ricketts

1. All cross bites in which the upper arch needs to be widened.
2. Cases needing mild expansion in the mixed or permanent dentition, which frequently exhibit lack of space for the upper laterals and in which the long range growth forecast is favorable.
3. Cases of class II in which the upper arch needs to be widened effectively and the upper molar rotated distally.
4. Class III conditions in which the upper arch needs to be widened and advanced with class II elastics.
5. Thumb sucking or tongue thrusting cases with its various modifications.
6. Cleft palate conditions either unilateral or bilateral.

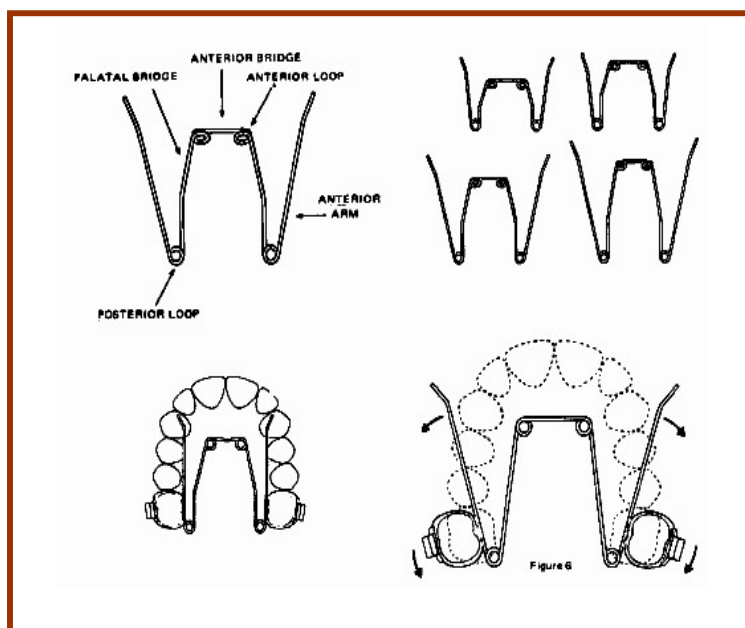


Fig 4 *Quad helix Appliance*

EARLY TREATMENT

Stages of Early Treatment

For teaching and organizational purposes, Ricketts divided the subject into four phases. The first phase of treatment is called “**Preventive**”. The first approach to “early treatment” is in the deciduous or primary dentition, or even earlier.

The second phase is in the mixed dentition, and called as “**Interceptive**”. The interceptive label applies because the clinician is intercepting the development or eruption of the teeth during the transition from the mixed to the permanent dentition.

The last two categories are not “**Early**”. The third phase is “**Corrective**” in terms of having available the permanent teeth to manipulate. This is a popular course to follow for those using multibanded or tooth-bearing appliances. Ricketts mentioned that some orthodontists like to wait until the 12-year molars are erupted to start treatment. When this is the situation, the initiation of the corrective phase may be detained up to 15 or 16 years of age because patients often experience delayed eruption of the upper second molars and very late development of the upper thirds.

The last stage is called “**Rehabilitative**” because it applies to the adult. Rehabilitating a case with no growth or little potential of physiologic change falls in this category therefore, under adult orthodontics. Adults take a much different approach.

Interceptive Orthodontics

It is approached, particularly in the mixed dentition as space is made for eruption of the permanent teeth or orthopaedic alteration of jaw bases is attempted.

The youngest patient that Ricketts has ever treated was one week of age. In some cleft palate patients a restraining device is used against the premaxilla within the first week of life. There is a question about the wisdom of doing this routinely, and he did not recommended it except in very extreme cases in which inadequate lip tissue is present or want to wait for growth to give the surgeon a better opportunity with a larger bulk of tissue.

Patient in the Deciduous Dentition

Ricketts did not try to work with any teeth until the second deciduous molars have erupted. This tooth usually erupts at about age two and one-half, and the roots are fully formed at about age three. But there is another factor which influences the clinician to delay starting patients until age four or five years, and it involves the practical control and clinical management of the very young patient who is quite sensitive.

Records at Start of Treatment on Such Young Patients

Frontal and lateral headfilm, laminagraphs on sides, a panoral film, and photographs. Failure to diagnose and prognose at this age is one of the big mistakes.

The Nasal Airway Problems and Lack of Function

Most orthodontists and researchers in growth simply haven't looked at the nasal cavity as a vital vegetative part of the face and talk about the oral

cavity as if it is independent of the development of the first branchial arch and independent from respiration. Biologically, the functions of mastication and respiration have been connected with the same set of muscles and the same set of nerve paths.

In frontal headfilms, a small nasal cavity on one side and a larger one on the other side is seen. It may be that the patient had a unilateral obstruction and see the whole maxilla sucked inward and upward on that side. The best place to start is by taking routine frontal headfilms and look for symmetry of the nasal cavity. This is one of the primary uses of the frontal headfilm. Figure 1 demonstrates the effects of removal of adenoids, palatal expansion, and orthopedic headgear.

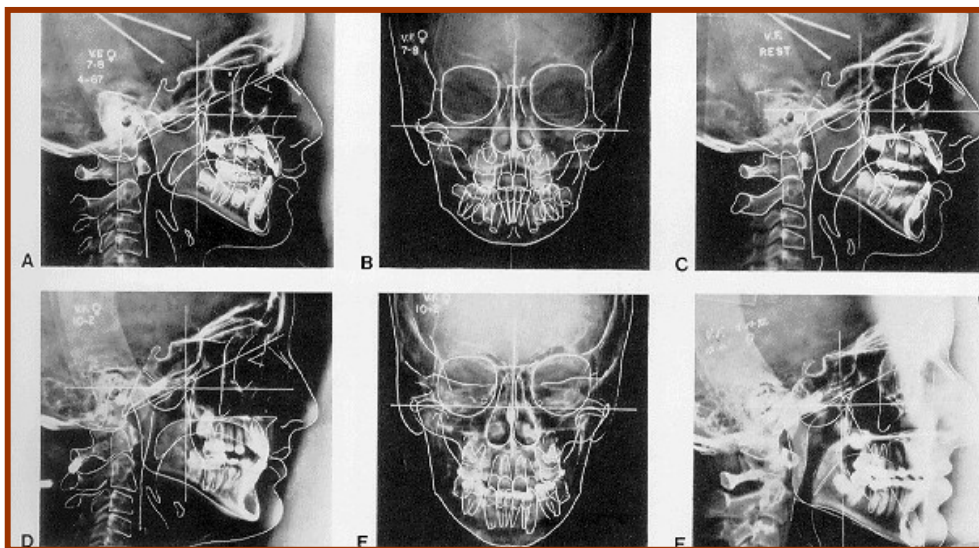


Fig.1

Fig.1. A. Female, age 7.8 years, adenoid patient with bilateral lingual crossbite. Note adenoid, low tongue, and upward cant of palate. B. Note narrow nasal cavity and narrow molars and position of unerupted canines. C. Rest position, showing habitual wide space and parted lips for oral breathing. D. Same patient at age 10.2 after adenoidectomy, palatal widening, and cervical traction. Note level of palate, closed lips, and elevated tongue. E. at age 10.2, note 6 mm increase in width of nasal cavity (from 25 to 31mm) in just over 2 years. F. Patient at finishing stage of nonextraction treatment, almost 13 years. Note normal airway.

Microrhino Dysplasia

Dr Ricketts mentioned that if the nasal cavity isn't developing properly, the tilt of the palate will frequently be elevated in front, as if it has been stopped in its vertical growth in the anterior part.

The lack of function in the nose seems to hold the front of the palate upward or prevent its downward descent. In these children clinically, you look right in their nose holes and the whole nose appears to be higher relative to the orbits.

A microrhino case (microrhino meaning small nose or small nasal cavity) will develop on its own from lack of function of the nose. Also the palatal growth inhibition as a result of certain kinds of vigorous thumbsucking in which a patient gets the whole shank of the thumb up into a markedly open bite and actually inhibits the downward dropping of the palate anteriorly.

The microrhino's patient who has a thumbsucking habit is a very good prospect for us to manage orthodontically with extraoral traction, particularly with the Kloehn headgear. Palate can be brought down and tip backward to correct the malocclusion. It can also be done with a skeletal change rather than doing it by movement of the-teeth. It could come from allergies and asthma or even potential adenoidal obstruction.

An imbalanced facial height results in the untreated child. Nose is short, the nose tip is upward, the nostrils show, the upper facial height is short, and the denture height is extremely long. These cases are very difficult to treat later without surgery in the maxilla because of the extreme distance

from the anterior nasal spine to the chin, requiring a stretching of the lips and creating unbalanced strain over that dentition. Later, with large denture height, teeth often are extracted or held backward; and still the patient ends up with mentalis action to compensate for the high denture height. Even with extraction, these patients still possess gummy smiles, the denture height and lip line do not match.

Importance of Tonsils and Adenoids

Ricketts theorized in the 50's: adenoids could lead to an opening growth rotation of the mandible, and dealing with not only an inhibition of maxillary growth but also an alteration of mandibular growth in a patient who is effectively obstructed in the nasal cavity. With this kind of information, a very strong recommendation, particularly when patient's x-rays confirm the diagnosis can be done.

Recommendation in thumbsucking patient with a Class II, Division 1 protrusive malocclusion in a mixed dentition, an open bite, a tongue thrust.

Dr Ricketts advised first to get adequate full records and study the case in terms of arch length and in terms of an assessment of the nature of the problem. For the history, inquire into the type of thumbsucking the patient is doing, perhaps even talk to the parents in private with regard to their attitude and what the child's home environment is. Then the records are processed and after the prognosis is made, using the long-range forecast get a frontal and lateral assessment with printouts to get a forecast of the patient's probable growth and a visualization of what the corrected face should look like. This then provides something to use as a feedback to make the decisions.

Start that patient with the quad helix appliance to which some spurs may be added if necessary. He started the rotation of the molars, the widening of the arch, and the Class II correction with that appliance, all at the same time. Then, as a second objective, he would suggest that this patient be treated skeletally so that the patient will have the opportunity to express normal development through the mixed dentition.

Application of Headgear to Deciduous Molars

Ricketts used it on both deciduous and permanent molars. He used a headgear on the upper second deciduous molars. If the upper second deciduous molars are fully formed at the age of three and last until the age of ten, we can put headgear on them just the same as we can put it on the first permanent molars and the same orthopedic effect is achieved as later with the first permanent molars, because the facial bones of the juvenile are more responsive and there is a mandibular growth spurt at that level.

Headgear at about the age of four or five in a Class II malocclusion treats the malocclusion rather rapidly.

Pressure Factors

Ricketts stated that fifty (50) grams is light, one-hundred fifty (150) grams is considered intermediate force and five hundred (500) grams is for orthopedic treatment. The force applied is 500 grams a side, which means that you have 1000 grams total on the back of the neck.

Early Intervention and Early Treatment

Ricketts made a clear distinction between the goals and objectives of early treatment versus later treatment. A distinct objective of the late treatment in the permanent dentition is occlusal perfection. We can have the

opportunities in the mixed and in the deciduous dentition ages to make skeletal changes and to utilize growth and to intercept habit patterns and functional patterns that we will not have at a later stage.

Dr Ricketts made a clear distinction between the concept of setting up the jaws at the young level rather than setting up teeth at the late level. The permanent stage is left for refinement and finishing, rather than for the gross treatment of malocclusion. The tissues will show the difference between the two concepts and the stability will also be more than gratifying when comparisons are made.

In conclusion, he believed that early treatment can save the teeth and at the same time produce esthetics of the jaws as well as the teeth, accomplish optimal function before its too late and achieve remarkable stability.

HEADGEAR

Headgear traction is often a primary appliance or a starting device even at the permanent dentition level. Although a simple face bow appliance seems simple, it is a much more complicated tool than often considered. Great inconsistencies, differences in design and application have resulted from the lack of knowledge of the possibilities and advantages of these procedures.

EVOLUTION OF EXTRA-ORAL TRACTION:

The use of extraoral force is about 100 years old. The head cap” was described by Kingsley in 1866 and Farrar in 1870’s. However its objective was limited to retraction of upper anterior teeth as an outer brace was attached to labial arch bow engaged in crude bands or other forms of attachment to the anterior. The ‘caps” were formed from leather strips or cloth.

Angle in 1888 recommended that it be worn during the sleeping hours. Intramaxillary elastic rubber bands were used for traction by day. The use of this appliance was limited to maxillary dental protrusion in patients following upper first bicuspid extraction.

By 1888 Goddard formed forerunner of head gears attached to rubber positioners currently used sometimes.

In 1898 Guilford talked about directional pull by activating rubber strands of the “skull cap” above or below the ear and his cap designs of 1 inch strips were grossly similar to many now in use.

Thus, up through the turn of the century extra-oral force was the main source of retraction of protrusive incisors.

By 1921, Case had extended the application of extra-oral therapy. Angle at the same time was looking more toward intra-oral or intermaxillary traction (Bake anchorage) and preserving the upper bicuspid. Case went on to describe three different extra-oral applications, all of which employed “sliding buckles for least possible discomfort”. First, was the usual directional pulls up the long axis of the maxillary anterior following maxillary extraction. Second, was an attachment to the lower anterior, to be used in open bites or protrusive conditions, also after lower extraction. Third and here is the first solid mention of upper molars to be moved distally the labial bar was extended, to the bicuspid area on the dental arch wire and forced the molars and entire arch backward (Much like Fisher mentioned later.) However, in the meantime, Angle had apparently won. For the next 15 years, great emphasis was placed on intermaxillary traction and full banding of teeth was initiated by Oppenheim from Vienna, also in 1936. Although Oppenheim presented his findings in 1936. the first cephalometric analysis of treated cases was presented by Brodie and the Illinois staff in 1938. It was determined that orthodontic treatment used at this time had little effect on structures other than alveolus and successes could be usually explained by holding of the maxillary dentition while growth of the mandible occurred.

Despite the theoretical opposition work started to be exhibited to show the effectiveness of the “head cap”. Kloehn reported at an Angle meeting in 1947 and made certain speculations from models and facial photograph records. Nelson in 1950, and both Nelson and Jerabak in a 1952 Tweed

meeting showed changes with cephalometrics. However by now several different types of usage were emerging and became confusing to clinician;

1. Recognizing the need for downward pull at the ends of the outer bow, Ricketts working with Downs applied only the neck strap portion of the Kloehn head cap. This was followed by Downs designing a full elastic neck strap or the cervical anchorage still popular today. Kloehn in the meantime also used only the neck strap.

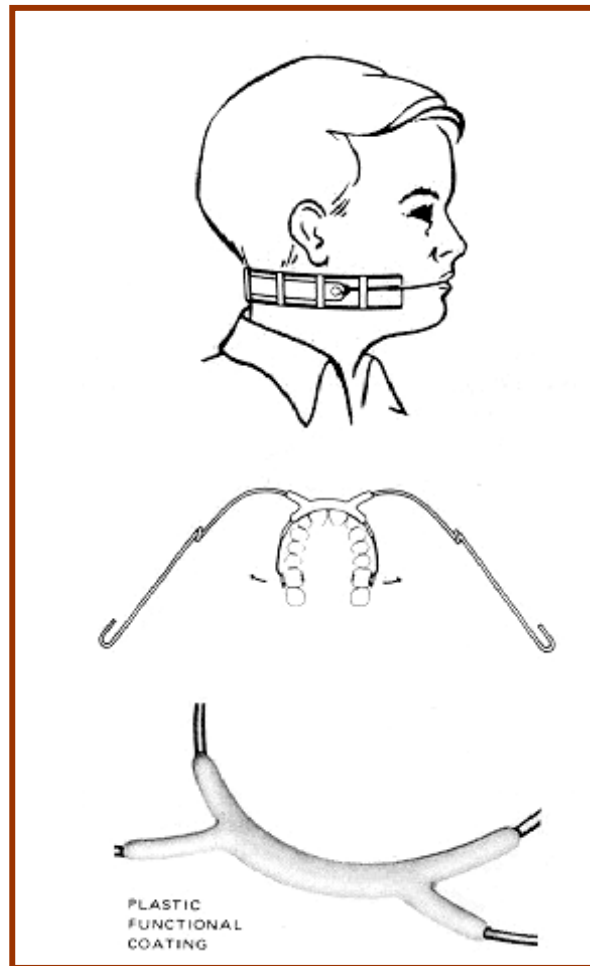


Fig. 1

2. Others came to attaching extra-oral traction to hooks on the arch wires with anterior teeth banded, some were attached to a neck strap which elongated the anterior teeth and closed the bite more severely. Others attempted a straight pull off the arch wire from the head cap, but still

used no face bow (Jarabak 1951) .Still others chose to attach a smaller dental bow to the edgewise arch wire in the bicuspid area and used the neck or head for anchorage , as many now use it with the full banded appliance.

3. Finally, the full arch was banded and “high pull” was reintroduced to intrude the upper incisors.

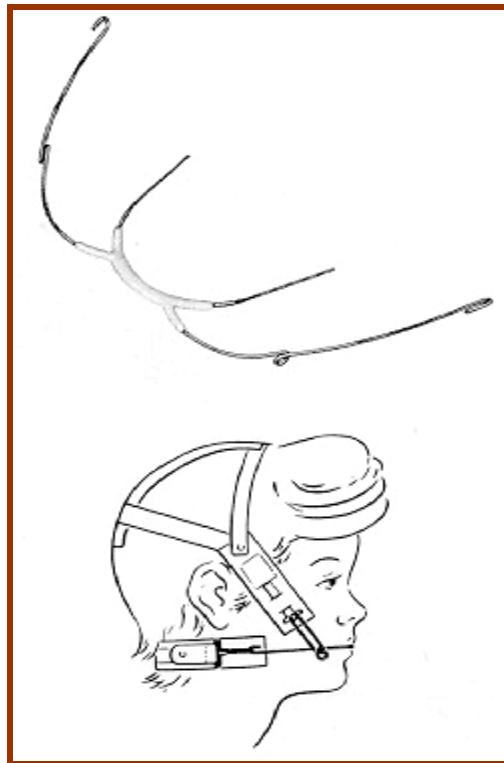


Fig. 2

Among all these methods, the Kloehn approach, with the neck strap he later adopted, became the method of choice, With cervical traction only arch length benefits even an the lower arch were appearing, Debates occurred as to the benefits of bite plates being used in conjunction with the headgear. Facial changes were often spectacular, but remained controversial.

All through these years the headgear appliances were being hand made. Brass wire was wrapped around the dental and face bow contacts to

act as a soldering assembly, the ends remained flexible and force applied at the apex of the arch moved the molars sideways and contributed to arch expansion. Beads of solder were employed as stops against the molar tubes.

In order to prevent distal tipping the outer bow was extended upward, to the level of the tragus of the ear, This also caused molar extrusion which aided in bite opening. A change was made from this tube set-up. However recognizing the problem of molar extrusion, 045 tubes were switched to a gingival location and bent bayonet stops were made with three-prong pliers.

By 1955 the face bows were being made commercially. In order to add stability and prevent breakage, two errors were introduced. One, the dental bow came to be made much too inflexible or rigid. Two, the dental arch was bent on a radius too small for a normal arch. Obviously, they were designed by men disciplined in extraction therapy and arch contraction.

Clinical research led to contraction and expansion type head gears for specific purposes. Arch changes were observed which could not be accounted for properly, such as spacing of the upper anteriors and width increases in bicuspid. However, other biologic factors now entered the picture. By 1955, Ricketts recognized maxillary change beyond the alveolar process and started building it into the objectives and treatment plan projection. Working with Klein, a series of cases clearly demonstrated alterations of growth behavior of the nasal floor. These were accumulated until 1960 when Ricketts compared 100 non-treated cases to 100 head gear cases over a period of 30 months, and in which strong forces were employed. The findings of Dr Ricketts study regarding behavior of the palate and point A with head gear treatment were eleven times greater than necessary to be statistically significant; It was no longer an argument.

Careful study of the frontal and lateral headplates showed sutures widening and in some patients an opening of the frontonasal suture was noted with plain Kloe hn face bow use. Finally, the nasal cavity was observed to widen under the influence of cervical anchorage when the molars were given the chance to widen and a continuous arch was not present to inhibit maxillary separation. In addition, the palatal tipping downward anteriorly rotated the nasal floor backward. The anterior area and nasal spine took the soft tissue nose with it.

In order to gain space for this action in the maxilla, the lower incisors came to be deliberately overintruded in many deep bite cases. All this time Ricketts recommended only 14 hours of wear during non-school hours, and no bite plates were employed.

At about the time of the foregoing observations, Schudy and others recognized undesirable rotation of the mandible and an anti-Kloe hn Moye took place. In order to encourage forward chin behavior, the neck strap was replaced by an oblique upward pull above the ear. This helped intrude the molar. Ricketts had tried this approach in a few patients in 1956, but he observed the Class II correction to be not as rapid and perhaps the patients were not good examples, may be the force was not great enough or continuous enough. At any rate, his results were not impressive in prevention of severely long facial pattern growth (over a long period of time).

Several factors, therefore, needed to be taken into account in the design of a new Ricketts' headgear, The features and uses are listed.

1. Observations over a period of two decades have led to the conclusion that a neck strap force of 500 grams will produce orthopedic effects

This meant a strong bow, unannealed, to prevent bending or breakage and laser welding was introduced to control the wire properties.

2. The closer to the centroid of the root the force is applied, the less the extrusion forces will be needed.
3. Banding the anterior teeth and placing a continuous arch tends to bind the two halves of the maxilla together and prevents convenient permanent expansion, If these teeth were banded, the continuous arch wire was not to be used, as the dental bow can rest under the incisal bracket wing. The dental bow is progressively expanded as it is light enough to flare under tension.
4. An extra anterior elastic is not employed except on a very limited basis because of the needless throwing of them into overbite. The dental bow is engaged directly against the anterior teeth at the gingival 1/3. This helps move the total maxillary complex.

In order to prevent shock on the anteriors a plastic covering of the laser weld was designed. Esthetics was also a problem and a reason for the plastic covering.

5. The inner bow was constructed “for center ground .05 tapered to a .045. This insured stability of weld and provided delicacy and flexibility and less discomfort to the molar teeth.
6. Progressive rotation of molars was needed. The dental bow material was made ductile and capable of numerous bends without breaking.
7. The inner bow also may serve as a ‘Lateral bumper’. This meant a larger radius for the anterior curve and also required bayonets to be bent inward thereby keeping the dental bow outward and freeing the buccal teeth of cheek or lip contact to permit natural development.
8. Wide variation in arch width is experienced. Two designs were made

one for either deciduous or small permanent extracted arches and the other for normal and large arches.

9. The headgear is to be worn 14 hours each day in the non-school hours, but some day wear is permissible. This will permit physiologic rebound during the day hours and promote less damage to anchor teeth.
10. The outer bow needs to clear the angle of the mouth. This meant a gentle labial step to the outer bow.
11. Some patients need prevention of upper molar extrusion. These often are patients with vertical patterns, low pain threshold. Poor mandibular physiology or damaged condyles. A loop was placed slightly mesial to the molars to receive a second highpull headgear with variable pull to prevent molar elongation. While the main pull came off the neckstrap.
12. Cleanliness of the neck strap holds down neck infections. The elastic strap with pad is discarded when it is worn out or dirty. It is made adjustable to the tolerance of the patient by a buckle and fixed loop.
13. The hooks are bent outward to engage the neck strap. The right hook is shortened to lock on the strap which is permanently fixed on the right side for ease of application and remembering by the patient.
14. The appliance may be needed later as part time retainer. The materials are durable, capable of sterilizations and capable of long term service.

With the foregoing factors in mind, the use of extra-oral traction can be quite versatile.

In summary, several features characterize its possible application.

1. It can be used as a tooth moving appliance when applied with light

forces (200 - 300 grams).

2. Tooth movement alone is slower in Class II correction and much more time is needed for treatment for the mandible to grow enough to make the correction. (This is where the computer growth set-up comes in, or at least a good manual objective forecast.).
3. It can be truly an orthopedic appliance used with heavy forces (500 grams or over). Almost two-thirds of the actual correction is made by skeletal change in the typical case with facial convexity. (Intermaxillary traction is used in non-orthopedic cases for reciprocal movements.)
4. Upon initial application the dental bow is advanced only 1 to 2mm from the incisors. As the molars start backward the incisor crowns are engaged at the cervical 1/3 and continue to upright almost ideally with further wearing without banding. This permits natural favorable adjustments to occur in both arches.
5. The younger the patient the better the chance of orthopedic correction. The young child sleeps longer and seems to adapt and cooperate better. It is used on the deciduous second molars at preschool ages.
6. It can be overused and produce undesirable concavity to the profile.
7. It can be misused or disastrously employed in patients where molar corrections are inadvisable from the beginning, even resorption of the disto-buccal root. (Hence, the need for diagnosis and objective planning.
8. Extraoral traction is best used as a biologic appliance as growth, physiologic and eruption factors are combined with the orthopedic qualities in the under-standing of its behavior. These constitute great advantages in current bioprogressive therapy.

9. Above all it must be recognized that changes with its use are three dimensional and are usually permanent and stable when retention consists of progressive release.

MANAGEMENT UMBRELLA AND VTO

Dr Ricketts states that management is a unique skill; it is the ability to get other people to work with you and for you, to accomplish common objectives. In an orthodontic practice, getting the subordinates to work with you and for you is to treat the patient to happy ending, and to manage the patient so that he gives full cooperation in his treatment.

Management System for Orthodontics

As per Dr Ricketts management system for orthodontists should include the following three things;

1. Quality: This includes quality of treatment result.
2. Quantity: This includes the number of patients treated.
3. Effectiveness – This includes the effectiveness treatment design and office management.

According to Ricketts good management system should allow the increase of all these factors at the same time. Naturally, a system proceeds from some basic premises, which underlie the approach selected.

The basic premises as per Dr Ricketts are as follows:

1. Primary goal in orthodontics is satisfactory outcome. Diagnosis and treatment management is really the means to the end. Results come first. The question is how to do we get our results.
2. The practice of orthodontics in the future may be different from what it is today or has been in the past. Practice efficiency has always been important but it is of the utmost importance today because of the increasing difficulty in attracting patients, due to an increase in

orthodontists and decreases in the birth rate; the control of third party programs; and the rapid acceleration of the cost of operation.

3. Orthodontics being the oldest specialty in dentistry should be the leader in initiating true preventive procedures for the future.
4. Early treatment has to be a part of futuristic orthodontic planning since it is essential to preventive procedures for the future.
5. The orthodontist should be an authority on occlusion, including temporomandibular joint function.
6. Quantity is not necessarily an enemy of quality, if quality comes first.
7. The orthodontists needs better communication with patient's parents, dentists and the public.
8. Time is one of our most valuable asses. It is reason in itself to become involved in a total management process.

The system which Ricketts used is the Lewis A. Allen Management System, which is based on a simple formula to plan organize, lead and control

1. Planning: The work performed predetermines a course of action to be followed.
2. Organizing: The work performed to arrange and relate the tasks to be accomplished.
3. Leading: The work performed to insure that people act in such a way as to complete our objectives.
4. Controlling: The work performed assesses and regulate results.

The management Umbrella Concept by Dr Ricketts

The management of the total practice according to Ricketts ultimately determines the degree of efficiency and effectiveness with which the orthodontist solves individual patient problems.

Knowledge of theory and skilled application of technique provide the basis for orthodontic practice, yet success depends on the achievement of the additional objectives of administrative efficiency, procedural control, and quality assurance. The methods of systems engineering, operations research and management science when applied to Orthodontics produce innovative practice designs and procedures that increase both the effectiveness of service and professional satisfaction.

Diagnosis and Treatment Design

According to Ricketts the more systematized is the diagnosis and treatment design less are the complications. In developing diagnostic and treatment design system, the simplest things that are done every day are thought about.

Three major objectives of orthodontic treatment:

1. Ideal functional occlusion.
2. The physiological stability of our results.

Total facial balance (cosmetics of the face and teeth)

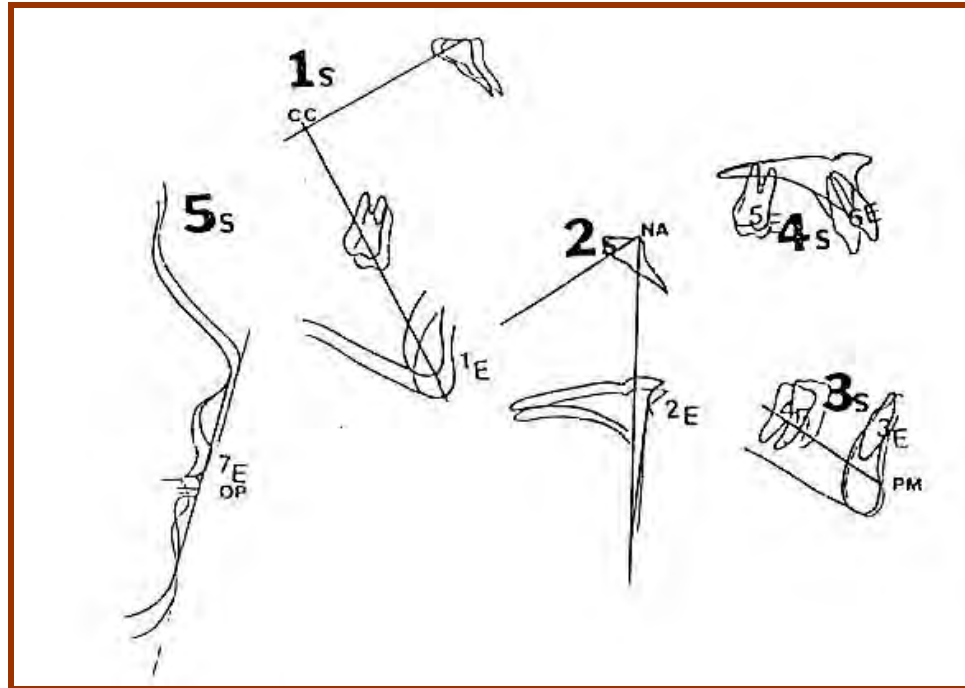
Dr Ricketts listed following basic premise of Orthodontic treatment

1. Occlusion
 - a. Tooth to bone health
 - b. Intermaxillary efficiency
 - c. Health of TMJ
2. Functional Equilibrium
 - a. Tonsil and adenoid evaluation
 - b. Habits
 - c. Musculature
3. Aesthetic Equilibrium (Soft Tissue Analysis)
4. Growth and Development

Therefore the five functions of planning apply as follows

1. Forecasting the growth of the individual patient.
2. Setting the objectives through the use of V.T.O. which is like a blueprint in building a home.
3. Program a sequence of mechanics to get the objective from visual treatment objective.
4. Schedule an average time for these mechanics to function.
5. Budget to develop individually the cost for treating this case.

Ricketts felt that systems are necessary to develop the policies and procedures to make this happen routinely. He briefly outlined the steps of the diagnostic and treatment design system for Bio-Progressive Therapy, which he referred to as diagnostic programming.



In superimposition Area 1 (Basion-Nasion CC), Evaluation 1 is chin change. In this case, the objective is to allow 2^0 of opening of the facial axis, to except the amount of chin growth shown, and to except that the upper molar will grow down the facial axis.

In superimposition Area 2 (Basion –Nasion at Nasion), Evaluation 2 is maxillary change, one of the objectives is to reduce point A only 2mm in this case.

In superimposition Area 3 (Corpus Axis at PM), Evaluation 3 is the lower incisors. In this case, just tipping of the lower incisors slightly is done. In Superimposition Area 3 also have Evaluation 4, the lower molars. In this case advancing the lower molars approximately 4mm.

In Superimposition Area 4 (Palate at ANS), Evaluation 5, the upper molars. In this case, upper molars are held even though this is Class II

division 1 malocclusion. Superimposition Area 4 also includes Evaluation 6, the upper incisor, and it is seen that the upper incisors have to be distalised.

In superimposition Area 5 (Esthetic Plane), Evaluation 7, the soft tissue and it is observed that there is a great amount soft tissue reduction in this case.

Dr Ricketts mentioned VTO as a blue print used in building house visual to forecast normal growth of patient and the anticipated influences of the treatment, to establish the individual objectives in treatment for growing patient must be planned and directed to the face and structure that the patient presents initially. The treatment plan should take advantage of the beneficial aspects of growth and minimize any undesirable effects of growth possible.

The visual treatment objective permits the development of alternative treatment plans. After setting up the teeth ideally within the anticipated or growth facial pattern, the orthodontist must decide how far he must go with mechanics and orthodontics to achieve them and what the alternatives.

In 1950-60 Ricketts attempted to predict treatment results and studied the possibility of growth forecasting. This was an outgrowth of cephalometric laminography of the temporomandibular joint. Long term growth forecasting had not proven trustworthy with the methods of projection used during the years of 1950 to 1965. However short term forecasting did prove adequate for the period of actual treatment when combined with the likely effects of the treatment. Treatment designs incorporating growth effects had proven to be quite appropriate and indeed could be recommended at a clinical level for the establishment of objectives and the planning of anchorage.

This idea was pricked up by Holdaway and termed a Visualized Treatment objective “, which was descriptive of the application, existing morphology and expected growth in modular increments provided a reference base. Superimposed on this behavior were the requirements of the individual patient, in terms of objectives and the required tooth movement. Desired changes in anterior teeth could be followed by the set up of the molars, depending on the needs and estimates of anchorage and arch form change.

Thus VTO as described by Dr Ricketts was very important for treatment planning and one of t

Ricketts Cephalometric Analysis

Clinical Application of Cephalometrics

In 1960 Ricketts published two clinical papers, first was a report on the morphologic findings in 1000 cases consecutively seen in clinical practice.

He dealt with description of morphology and dental relationship on one hand and on the other hand he discussed classification, categorizing conditions in terms of their clinical requirements and difficulty. The third was the study of change, comparing the morphology of a single patient at different stages of development or treatment. the fourth was its application in communication of the first three among clinicians and researchers, and between clinician and patient.

The fourth application made the clinician using cephalometrics stand above the rest. With the ability to describe and compare came the ability to explain things and to find out new information never before available. Above all was the ability to communicate with -the rest of the profession in a sophisticated and meaningful language.

The second publication of 1960 by Ricketts was on analysis of treated cases. The possibilities and the effects of treatment using multibanded orthodontic technique and extraoral traction, the main sources of correction of that day, were explored in depth with cephalometrics.

Changes were measured in five different areas in a logical sequence. First were the changes in the cranial base. The second area was changes in the lower jaw complex, the third in the upper jaw complex and the fourth in

the upper and lower dentures. The fifth area was soft tissue changes in the nose and lips.

Ricketts analysis

All Cephalometric analysis involve the identification of various craniofacial landmarks many such landmarks are traditional. Others however may be unique to a specific analysis. The less traditional points, planes, and axis used in Rickett's analysis are as follows.

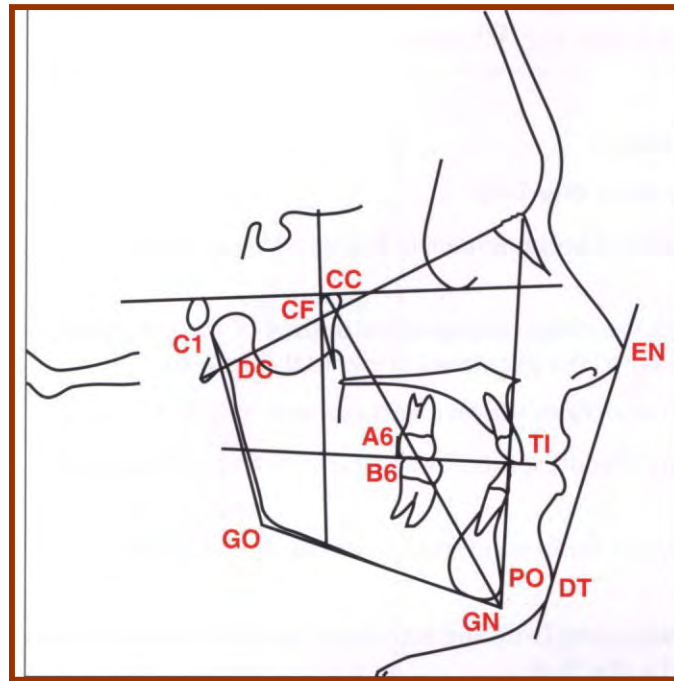


Fig 1

A6	Upper molar	A point on the occlusal plane located perpendicular to the distal surface of the crown of the upper first molar.
B6	Lower molar	A point on the occlusal plane located perpendicular to the distal surface of the crown of the lower first molar.

C1	Condyle	A point on the anterior curve of the soft tissue chin tangent to the esthetic plane or E-Line.
DT	Soft tissue	the point on the anterior curve of the soft tissue chin tangent to the esthetic plane or E-line
CC	Center of cranium	The point of intersection of the basion nasion plane and the facial axis
CF	Center of cranium	The point of intersection of the pterygoid root vertical to the Frankfort horizontal plane.
PT	PT point	The junction of the pterygomaxillary fissure and the foramen rotundum: the outline of the foramen rotundum can be located by using the template designed for that purpose (Jacobson-Sadowsky lip counter template, Unitek Corp) or it can be approximated at the 10:30 (face of a clock) position on the circular outline of the superior border of the pterygomaxillary fissure.
DC	Condyle	The point in the center of condyle neck along the Ba-N plane
En	Nose	A point on the soft tissue nose tangent to the esthetic plane or e-line
Gn	Gnathion	A point at the intersection of the facial and the mandibular planes (cephalometric Gn as opposed to anatomic Go)
PM	Suprapogonion	The point at which the shape of the symphysis mentalis changes from convex to concave also know as protuberance menti.

Pog	Pogonion	The point on the bony symphysis tangent to the facial plane.
PO	Cephalometric	The intersection of the facial plane and the corpus axis
TI	TI point	The point of intersection of the occlusal and the facial planes
Xi	Xi point	The location of the Xi point given below .

Definition and location of Xi point

The location of the X points is keyed geometrically to the Franfort horizontal and the pterygoid root vertical planes (PtV). The procedure follows:

1. Locate FH and draw PtV plane perpendicular to the FH plane.
2. Construct four planes tangent to points R-1, R-2, R-3 and R-4 on the borders of the ramus
 - a. R-1: Deepest point on the anterior border of the ramus, located halfway between the superior and the inferior curves.
 - b. Located on the posterior border of the ramus opposite R-1
 - c. Deepest point of the sigmoid notch, halfway between the anterior and the posterior curves.
 - d. Opposite R-3 on the inferior border of the mandible.
3. The constructed planes form a rectangle enclosing the ramus.
4. Xi point is located in the center of the rectangle at the intersection of the diagonals.

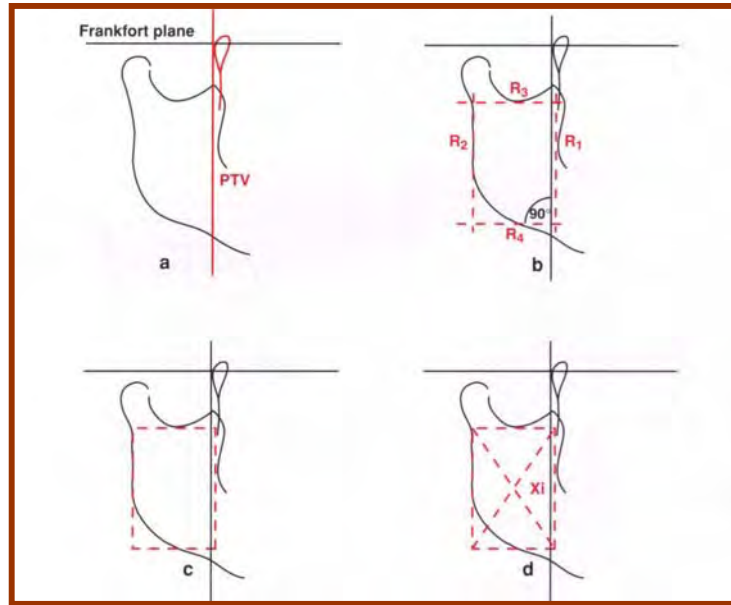


Fig 2

Definition and location of planes

1. Frankfort horizontal : Extends from porion to orbitale
2. Facial plane: Extends nasion to pogonion
3. Mandibular plane :Extends from gonion to gnathion (cephalometric landmarks previously defined)
4. PtV (Pterygoid vertical): A vertical line drawn through the distal radiographic outline of the pterygomaxillary fissure and perpendicular to the Frankfort horizontal.
5. Basion-nasion plane: Extends from basion to nasion; divides the face and cranium
6. Occlusal plane : The functional occlusal plane is represented by a line extending through the first molars and premolars.
7. A –Pog line: A line from point A to Pogonion is often to as the dental plane.

The esthetic line or plane extending from the soft tissue tip of the nose

(En) to the soft tissue chinpoint (DT).

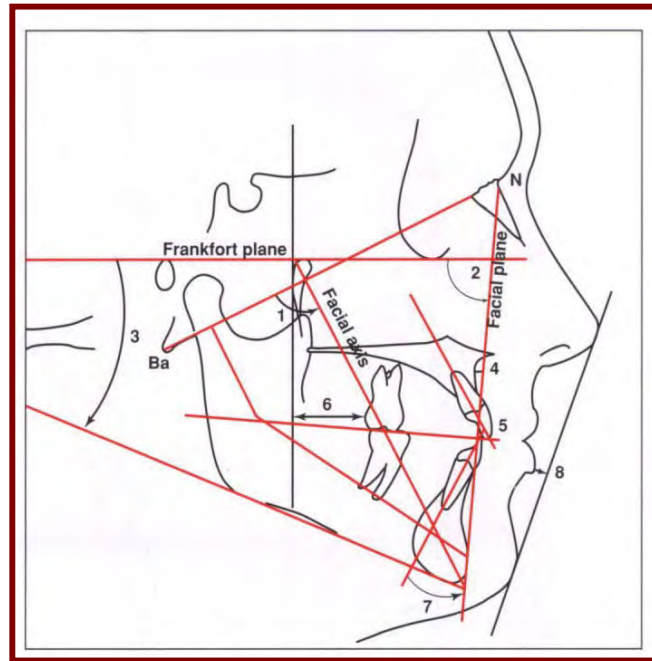

Fig 3

Definition of location of axis:

Facial axis: A line extending from the foramen Rotundum (PT to Gn)

Condylar axis: Extends from DC to Xi point used to describe the morphologic features of the mandible.

Corpus axis: Extends from X to PM used to describe the morphology of the mandible and to evaluate dentition changes.

Interpretation chart

Chin in Space	Mean values for 9 yrs old	Age Adjustments
Facial axis	$90^{\circ} \pm 3.5^{\circ}$	No adjustment
Facial (angle) depth	$87^{\circ} \pm 3^{\circ}$	Adjust + 1° every 3 years
Mandibular plane	$26^{\circ} \pm 4.5^{\circ}$	Adjust - 1° every 3 years

Convexity of point A	$2\text{mm} \pm 2\text{mm}$	Adjust -1mm every 3 years
Lower incisor to A-Pog	$+1\text{mm} \pm 2\text{mm}$	No adjustment
Upper molar to PtV	Age + 3mm	Add 1mm per year
Lower incisor to A-Pog Profile	$22^0 \pm 4^0$	No adjustments
Lower lip to E-plane	$-2\text{mm} + 2\text{mm}$	Less protrusive with growth

Interpretation

Chin in Space	
Facial axis	The angle formed between the basion nasion plane and the plane from foramen rotundum (PT) to gnathion. On the average this angle is 90degrees. A lesser angle suggest a repositioned chin, whereas an angle greater than a right angle suggests a protrusive or forward growing chin.
Facial (depth) angle	The angle between the facial plane (N-Pog) and the Frankfort horizontal. This angle provides some indication of the horizontal position of the chin. It also suggest whether a skeletal class-II or III pattern is due to the position of the mandible.
Mandibular plane	Measure an angle to FH. On the average, this angle is 26 degrees at 9 years of age and decreases approximately 1 degree every 3 years. A high or steep mandibular plane angle implies that an open bite may due to the skeletal

	morphologic characteristics of the mandible. A low mandibular plane suggests the opposite (e. a deep bite)
Convexity	
Convexity at a point	The convexity of the middle of the face is measured from point A to the facial plane (N-Pog). The clinical norm at 9 years of age is 2.0 mm and decreases 1 degree every 5 years. High convexity implies a class-II skeletal pattern. Negative convexity suggests a class III skeletal pattern.
Teeth	
Lower incisor to A-Pog	The A Pog line or plane is referred to as the denture plane and is useful reference line from which to measure the position of the anterior teth. Ideally the lower icisor should be located 1.0mm ahead of the A-Pog line. This measurement is used to define the protrusion of the lower arch.
Upper molar to PtV	This molar measurement is the distance from the pterygoid vertical (back of the maxilla) to the distal of the upper molar. On average this measurement should equal the age of the patient +3.0 mm (e.g. a patient 11 years of age has a norm of $11 + 2 = 14\text{mm}$. this measurement assists in determining whether the malocclusion is due to the position of the upper or lower molar. It is also useful in deciding whether extractions are necessary.
Lower incisor	The angle between the long axis of the lower incisor and

inclinations	the A-PO plane (1 to A-PO) is measured. On the average this angle should be 28 degrees. This measurement provides some idea of lower incisor procumbency.
Profile	
Lower lip to E-Plane	The distance between the lower lip and the esthetic (nose -chin) plane is an indication of the soft tissue balance between the lips and the profile. The average norm for this measurement is 2.0 mm at 9 years of the age. The positive values are those ahead of the E-line.

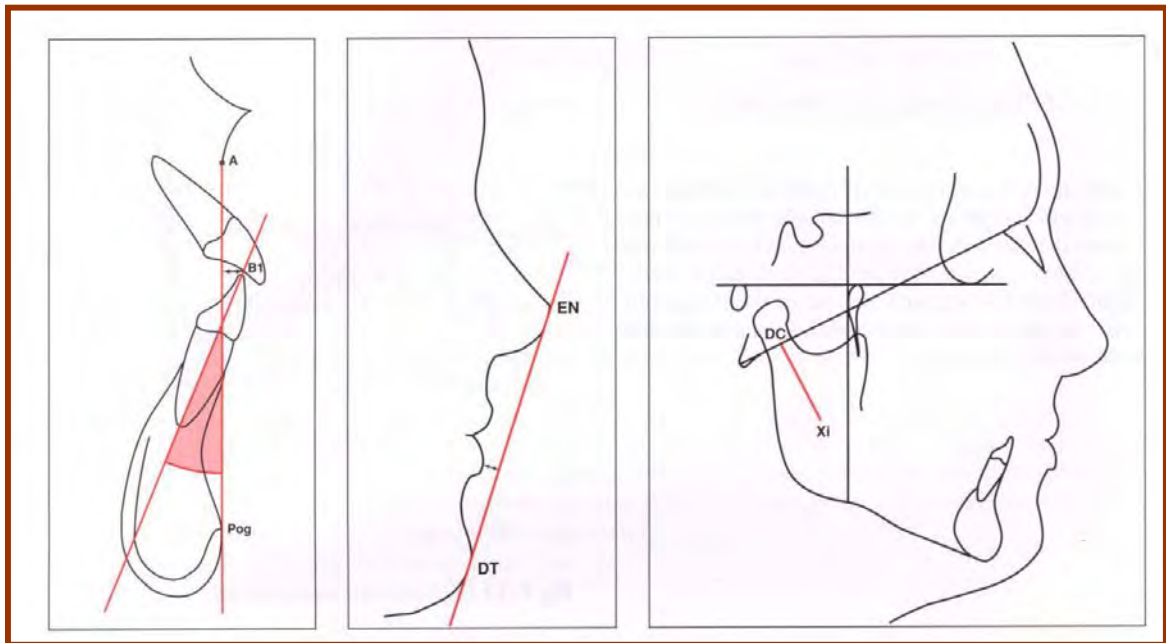


Fig 4

THE GOLDEN DIVIDER

The golden divider may be used for morphologic analysis of the teeth, the skeleton and the soft tissues of the face




Fig. 1 *The Golden Divider*

Fig. 1. It is based on the "Golden Section" also called the "Divine Proportion". Upon widening the divider, it will be noted that a short side and a longer side will be measured off proportionally as the divider is extended




Fig. 2 *Widening the divider produces two measurements in a ratio of 1:1.618.*

Fig. 2. The longer side is 1.618 times the shorter side and the shorter side is 0.618 the length of the longer. In turn, the longer side is 0.618 the length of the total outer measurement. The golden relation (1:1.618) is called Phi and

given the Greek symbol ϕ . This relation is based on underlying laws of mathematics, geometry, and physics.

The use of this instrument applies to esthetic values, because so many relations found to be beautiful to the human eye or comforting and pleasing to the human psyche follow these proportions. But, of greater significance are the biologic implications, as many things in nature follow the principle in proportionality of the golden section, the golden triangle, and the golden rectangle. The proportion is linked to growth and it relates to optimal function. Hence, it can be used for analysis of structural harmony and balance, and can be applied for treatment planning of the tooth, bone, and soft tissue relationships for all forms of dentistry, maxillofacial and plastic surgery.

Tooth Relationships

Useful parameters for the teeth start with the lower central incisors (Fig. 3).

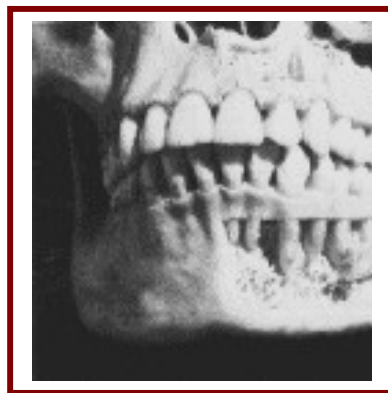

Fig. 3 *Occlusion to demonstrate values*

Thus, the total of both lower centrals (10.8mm) is golden to both upper centrals (17.5mm), which starts a series of harmonic units in the occlusion. The next golden relation (across the arch, not in direct width of

teeth) is the measurement between the distals of the two upper lateral incisors (28.3mm) as related to the upper centrals (17.5mm). The next progression is the-width to the buccal surfaces of the upper first bicuspid (45.7mm), which is golden to the width through the lateral incisors in the normal beautiful arch. This is generally lacking in patients with malocclusion in all three types.

Another series is observed in from the width of the lower four incisors (on the arch) at 22.1 mm. The upper intercanine width measured at the cusp tips at 35.75mm is found in a golden relation to the lower incisors. Finally, the width at the mesial of the upper second molars (57.8mm) will be found to be in the golden relation to the intercanine width in beautiful arches, which helps in assessing arch form.. The distance between the distals of the lower canines (31.5mm) is golden to the distance between the lower first molars (50.2mm) at the buccal grooves.

Soft Tissue Relationships

For the face, a connection is apparent in the smile, as the intercanine width is observed to be the same as the width of the nose at the alar rim as seen in a glamorous model.

For the width dimensions in the soft tissue, the nose, mouth, eyes and face are related .If the lateral rim of the nose (LN) width is taken as a unit of 1.0, progressively the mouth (CH), lateral canthus of the two eyes (LC), and the width of the head at the level of the eyebrow (TS) is a progressive golden series.

For vertical relations, it is best to start with the underlying skeleton as seen in the lateral cephalometric head plate. Eight golden relations were

identified from composites of 30 beautiful normal male subjects with ideal normal occlusions. For the vertical location of the lower incisor, the Point A (at subspinale in the maxilla) and the Point Pm (at the mental protuberance of the mandible) is used. In centric occlusion, if the distance from Point A to lower incisor tip is taken as 1.0, the height of the lower incisor to Pm is 1.618.

For relation of A to Pm itself, a golden proportion is seen to the Frankfort plane (porion to orbitale). If the level of orbitale (lower rim of the orbit) to Point A is taken as 1.0, the vertical height of the denture is 1.618, suggesting normal denture height.

Other values for surgical or orthopedic corrections are seen as the corpus axis (Pm to Xi point) is golden to the condyle axis (Xi to Condylion) or posterior superior aspect of the condyle head. The Xi point is the geographic center of the ramus. Also, maxillary depth is golden to pharyngeal depth. The cranial structures are seen to be golden in the anterior and posterior base S-N (1.618) + SBa (1.0). Nasion to cranial center (CC), at 1.618, is golden to cranial center to articulare on the Basion-Nasion plane.

For vertical facial relation in the soft tissue, another progressive series is seen as confirmed from composites of normal beautiful faces . Here, starting with the larger value, the face height is taken from Trichion (at the top of the wrinkled forehead or near the hair line in the young) to the bottom of the chin (soft tissue menton). If the lateral canthus level to Trichion is taken as a unit of 1.0, the height of eye to chin is in the golden proportion, if the face is beautiful. Inversely, from chin upward, the distance of the chin to the curve of the ala of the nose is taken as a 1.0 value and 1.6 is seen from

the nose to Trichion. This makes nose length (lateral canthus height to alar height) a congruent or reciprocal area or the "center" of the face.

From the eyes downward, a golden relation is seen from the nose (1.0) to the chin (1.618). Inversely, the bottom of the chin to the mouth at 1.0 leaves a 1.6 proportion from the mouth to the eye. Like nose length, the upper lip length is a reciprocal or an overlapping congruent area between the eye-nose-mouth-chin proportions.

If the alar rim to the upper lip (to stomion or lip embrasure) is taken as 1.0, the distance to the chin is 1.6 and the same distance to the eye is 1.6. This finally shows that three equal areas of the face are very nearly the same in beautiful faces. These are forehead to eye, eye to mouth and nose to chin.

For locating golden proportions in the profile aspect, the same limits of vertical proportions were found useful. It appeared that the base of the ear lobe was the posterior limit to the face. To nose tip these formed three golden rectangles like the foregoing equal areas, i.e. Trichion-eye, eye-mouth and nose-chin. As the horizontal nose-tragus base is studied, a golden section falls at the lateral canthus of the eye. Taking the eye-mouth vertical as 1.6, the canthus to nose rim is 1.0.

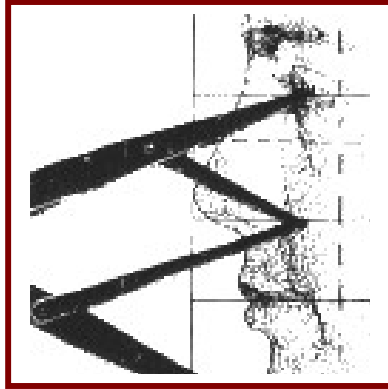


Fig. 4 *Golden proportion from eye-nose-chin*

Figure 4 shows the golden divider applied to the eye-nose-chin for facial height.

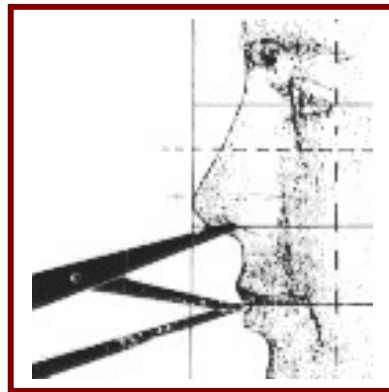
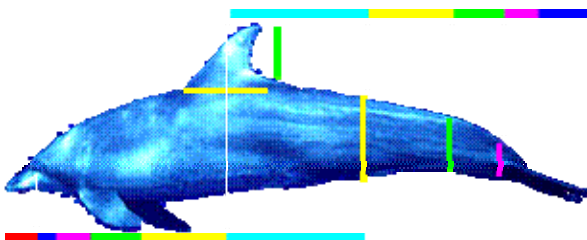
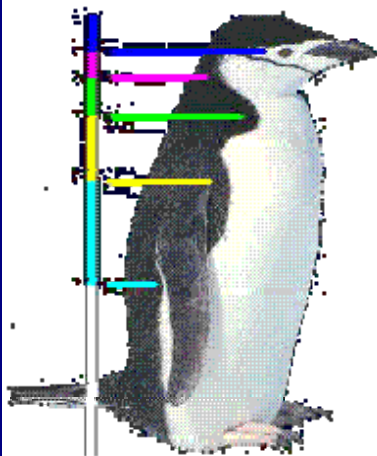




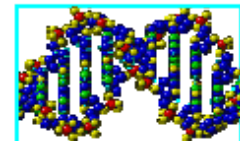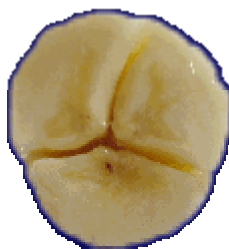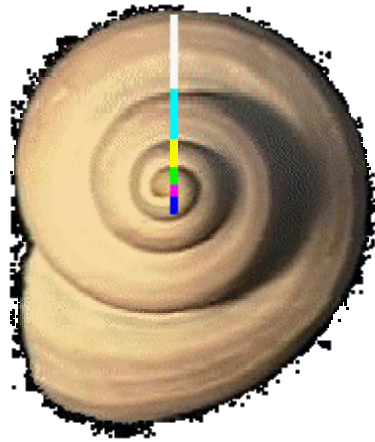



Fig. 5 *Golden proportion from nose-mouth-chin*

Figure 5 shows the divider on the ala of the nose, lip embrasure and chin to determine denture height and lip position.



ANIMALS AND GOLDEN PROPORTION



PLANTS AND FRUITS IN GOLDEN PROPORTION



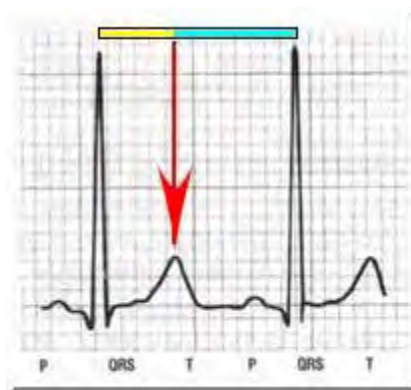

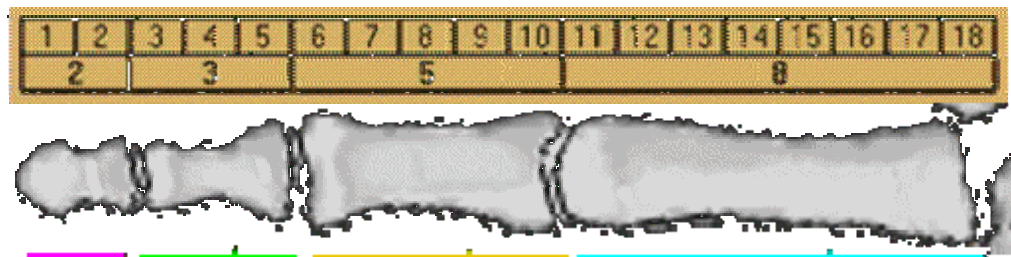
MONUMENTS IN GOLDEN PROPORTION



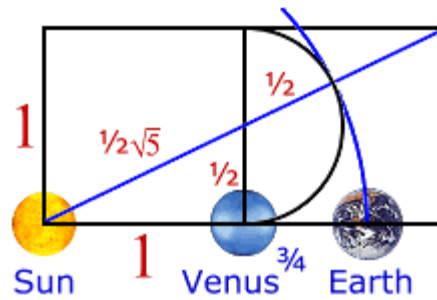
FACES IN GOLDEN PROPORTION



HAND AND HEART BEAT IN GOLDEN PROPORTION



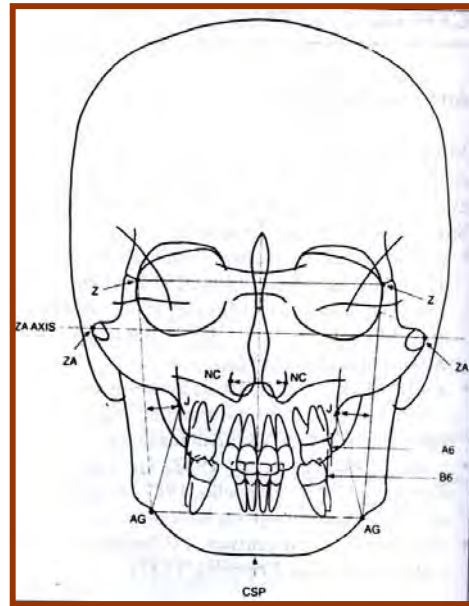
SOLAR SYSTEM IN GOLDEN PROPORTION



RADIOGRAPHIC EVALUATION OF TRANSVERSE SKELETAL DISCREPANCIES

The posterior-anterior (PA) cephalogram is the most readily available and reliable radiograph for identification and evaluation of transverse skeletal discrepancy. A standardised PA cephalometric radiographic technique that will allow superimposition of radiographs, comparison of linear measurements and evaluation of radiographs over time should be employed. Ricketts developed the Rocky Mountain Analysis and he suggested norms and choose specific radiographic landmarks. They were

JR – Jugale right;
JL – Jugale left;
AG – Antegonion right;
GA –Antegonion left;
ZR – Zygomatic light;
ZL –Zygomatic left



Using these landmarks, the effective maxillary width, effective mandibular width, and the frontolateral facial lines can be constructed.

The effective maxillary width defines the width of the maxilla and is the linear measurement between the points JL and JR (bilateral points on the jugale process at the intersection of the outline of the maxillary tuberosity and the zygomatic buttress). The effective mandibular width defines the

width of the mandible and is the linear measurement between the points AG and GA (bilateral points at the lateral inferior margin of the antegonial protuberance). The frontolateral facial lines are two lateral lines constructed from ZR, ZL (bilateral points on the medial margins of the zygomaticofrontal suture, at the intersection of the orbit) to points AG and GA.

By using these landmarks, two separate differential measurements were utilized to evaluate transverse maxillary deficiency radiographically by Ricketts:

1. The maxillomandibular width differential
2. The maxillomandibular transverse differential index.

The maxillomandibular width differential is a measurement from the frontolateral facial line to JL and JR respectively, along the effective maxillary width line. This measurement is calculated independently for each side and compared with a normal value of 10 ± 1.5 mm. If this radiographic measurement is greater than 10mm, a transverse discrepancy between the maxilla and mandible is present. The difference between the measured distance and 10 mm summed from each of the two sides is the total transverse deficiency. This method is useful for determining the total discrepancy and demonstrating if there is a greater deficiency on one side or the other. However, it is not useful for determining in which arch the discrepancy is located.

The maxillomandibular transverse differential index is the expected maxillomandibular difference (an established norm for different ages) minus the actual measured maxillomandibular difference. The expected

maxillomandibular difference is defined as the age-appropriate expected J Point – J point distance, the actual maxillomandibular difference is defined as the actual AG-GA measurement minus the actual J point –J point measurement.

If in a skeletally mature patient (15.5 years or older) the maxillomandibular transverse differential index is greater than 5mm, surgically assisted expansion may be indicated. If the differential index is less than or equal to 5mm orthodontic or orthodpaedic expansion may effectively correct or camouflage the transverse skeletal problem. This method allows easier identification of which arch is deficient or excessive because actual values can be compared to normal value. These normal values were suggested for the Caucasian race and should not be considered normal values for all races and ethnic groups.

TRUTH IN ORTHODONTIC BELIEFS

Ricketts addressed the following statements in the editorial of truth in orthodontic belief.

1 “Molars do not intrude”

It was denied that the muscles of mastication can exert an intruding effect on molars through function. In other words, Ricketts believed that closing jaw muscles are not strong enough to exert an intruding pressure.

As the growth turgor of the mandible is expressed, and as facial development occurs, greater intermaxillary distance is created.

Teeth erupt into the space developed as the jaws grow apart (Fig. 1).

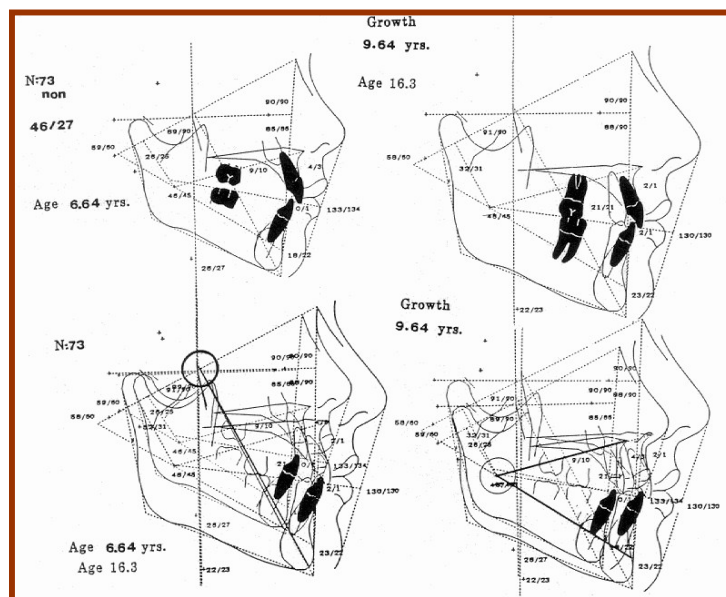


Fig. 1

Fig. 1 Composite growth superimpositions of 73 untreated children.

Consequently, the molars continue to erupt until growth is completed (unless impeded by the tongue, as observed in posterior open bite).

Recent findings indicate that the lower first molar erupts from the corpus axis a mean of nearly 0.5mm per year. The upper first molar erupts a mean of 0.7mm per year from the palatal plane (Fig. 2).

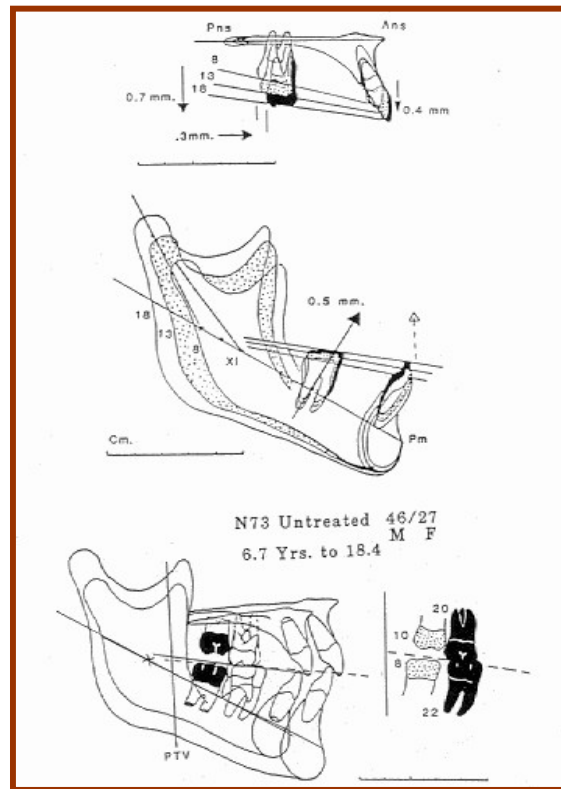


Fig. 2

Fig. 2 *Additional superimpositions of 73 untreated children, showing eruption patterns of upper and lower first molars.*

On the mandibular growth arc, however, the whole arch moves upward and forward. As viewed biologically, the first molar erupts about 1.2mm per year in a vertical direction (Figs. 3, 4).

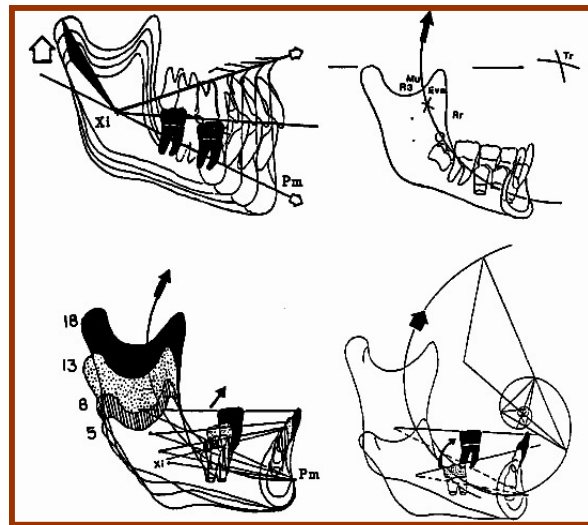


Fig. 3

Fig. 3 Typical pattern of mandibular arcial growth

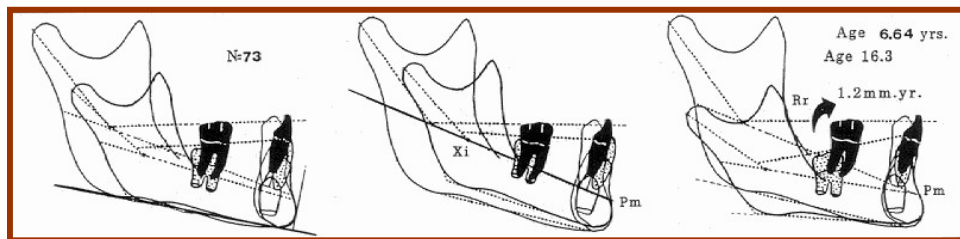


Fig. 4

Fig. 4 Eruption of lower first molar along mandibular growth arc in sample of 73 untreated children.

Furthermore, it is clear that in longer faces, as greater-than-average vertical development occurs, the teeth compensate by filling in the additional space until they encounter muscle resistance to their eruptive force (Fig. 5).

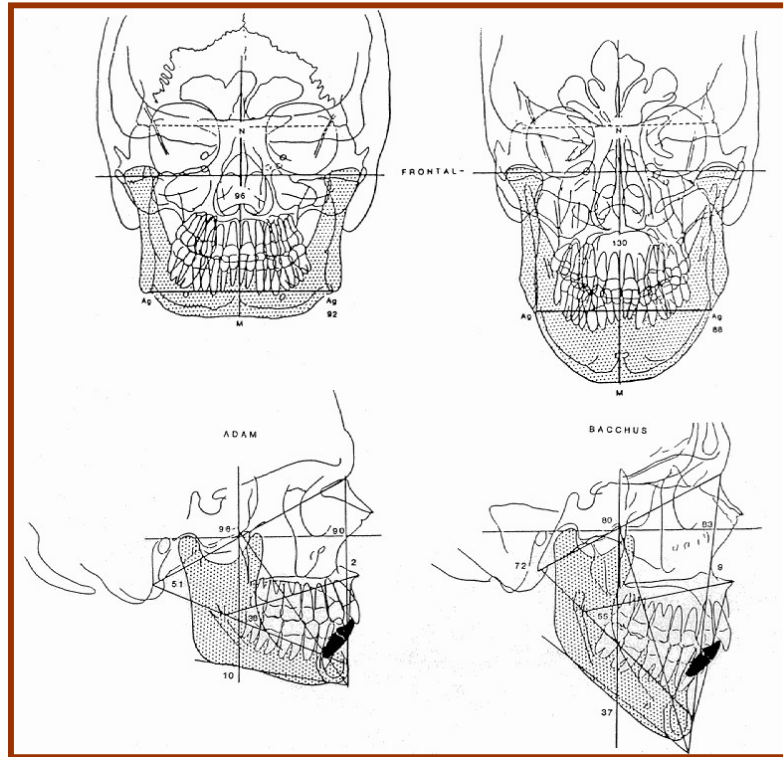


Fig. 5

Fig. 5 *Morphology of long-faced patient (Bacchus) compared to short-faced patient (Adam).*

One can estimate, on the basis of animal studies and clinical findings, that the pressure of eruption is 0.2 grams per square millimeter of enface root surface. This would place the eruptive capacity of each of the first molars, upper and lower in the range of 20-25g.

Theoretically, any continuous magnitude of force in this range would essentially inhibit molar eruption. Any greater continuous pressure would produce an intrusion, as estimated from a starting force of not more than 80g for clinical practice. Such forces are easily within the limits of the muscles of mastication, which is measured in kilograms.

Of great importance to this issue is the behaviour of the lower molars during cervical traction of the upper molar in the correction of Class II

malocclusion. There is of course, a vertical component to cervical traction that prevents molar tipping. If heavy, continuous forces are exerted on a 20 or more hour a day basis with cervical traction, the muscles of mastication will often overcome. This behavior has been described as the "**Wedge effect**".

However, if forces do not exceed 500g in the mixed dentition (or 350g in the deciduous dentition) and bite plates are not used, and pain has not been overwhelming to the patient, with extrusion of the upper molar, the lower molar has been seen to intrude in hundreds of patients. This is not merely an anecdotal finding.

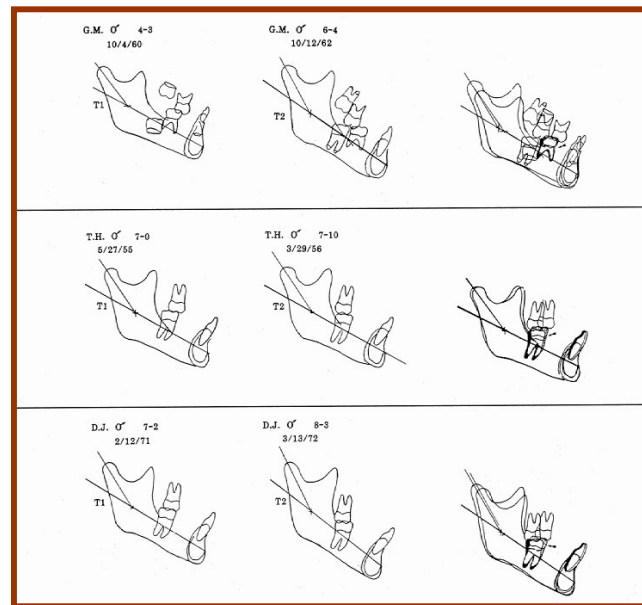


Fig. 6

Fig. 6 *Three cases in which intrusion of lower molars accompanied extrusion of upper molars from cervical traction.*

In these patients, the occlusal plane, which originally was located above Xi point, moves downward during treatment to the level of Xi point (or preferably, below it). Measurements from the corpus axis during the period

of cervical traction show the lower molar to be decidedly intruded by 2mm or more, when it should have been erupting 0.5mm per year. This occurs with no appliance on the lower arch. When a utility arch is placed for management of the lower arch, buccal torquing of the roots of the lower molar will produce even further gains in lower molar intrusion or lower molar crown height reduction during cervical traction.

The pull of the elastics, which exert a vertical force of about 50g, would normally cause the lower molar to be extruded and the upper molar to be intruded, as measured from the palatal plane. Upper molar intrusion from Class II elastics would, of course, occur primarily in patients who do not yield by lowering of the mandible. Therefore, in these patients the forces of mastication intruded the upper molars.

In conclusion, to build an orthodontic philosophy upon the belief that a molar cannot be intruded by the forces of mastication would be a miscalculation.

2. "Management of the vertical growth of the alveolar processes as the primary function of the orthodontist."

Ricketts have shown some evidence that in the short term (meaning the one-year period of treatment), the vertical growth of the condyle at the ramus can also be affected with cervical traction. This can be seen in a greater increase in ramus height during treatment than would have been expected without treatment (Fig. 6). Even more important, high-pull traction to the upper arch can intrude the upper molar, with a resultant loss of vertical support or even compression of the mandible, which would inhibit some condylar and mandibular growth.

All of these influences with the possible exception of treatment-induced condylar compression and damage seem to have a transitory effect. Within three to five years after treatment, mandibular growth is usually but not always restored to its predicted size and general form.

The next statement is, "Vertical growth of the posterior portion of the maxilla cannot be stimulated or inhibited." It is true that it is difficult to get a handle on the body of the maxilla from a purchase on the teeth, which are held in the alveolar process.

Movement of the entire upper jaw complex, including the intermediate bones, has been demonstrated beyond any shadow of a doubt by Dr Ricketts.

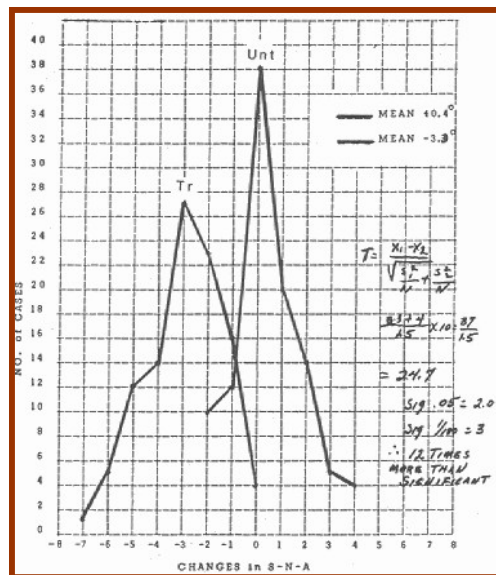


Fig. 7

Fig. 7 Comparison of changes in maxillary base, measured by SNA angle, between 100 treated Class II cases, 10 years after treatment, and 100 untreated cases.

In conclusion, the assumption that control of the alveolar processes is the sole possibility for vertical orthodontic management of the growing child is consistent with an ideology that will eventually become a relic of the past.

3. "Lower incisors should not be intruded to level the arch in growing patients."

Dr Ricketts mentioned that when composites are compared to controls of normals (corrected for age, size, and sex), it is easily observed that in most deep bites, the lower incisor is in supraversion. In deep-bite Class II conditions with high convexity, the lower molar is near normal and all the other teeth are in abnormal positions.

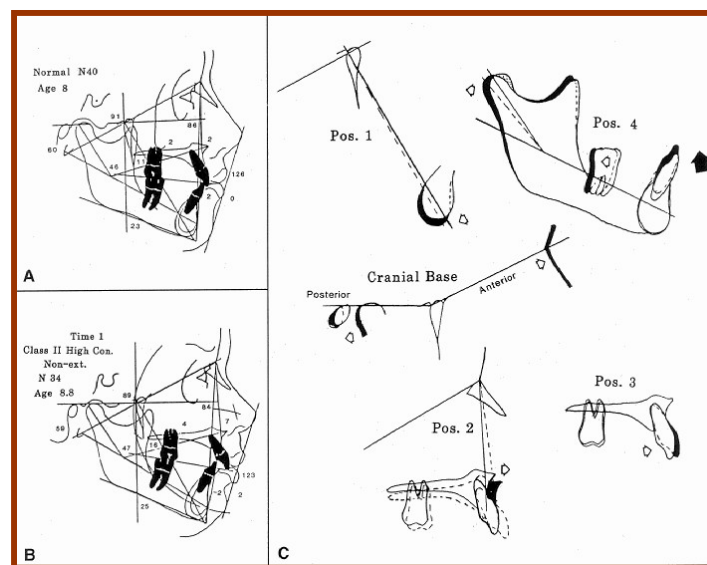


Fig. 8.

Fig. 8. A. Normal sample at age 8. B. Class II, deep-bite, high-convexity sample at age 8. C. Components of the Class II condition.

He believed that the lower incisor can be successfully intruded, when proper upper incisor position and interincisal angles are restored and when normal function is established, the relationship will hold. Cases with lower incisor intrusion were demonstrated to be stable 30 years ago. The utility

arch was developed in 1960, and many other modalities are currently used for management of the lower incisor.

According to Ricketts the lower incisor may be difficult to manage properly with round wires. For best long-term stability, best control of the mandible, and best utilization of growth during treatment must be achieved and in deep-bite cases treat to the level of the lower first premolar rather than extruding. This provides the least disturbance to the facial pattern, and ensures the least likelihood of post-treatment adjustment by preventing any increase in lower face height, which increases lip tension.

In fact, it is obvious that the lower incisor, when intruded into a wider portion of the mandibular symphysis, can be brought forward satisfactorily and safely. Such a practice will avoid the flat mouth and the flat face. Quite frequently, this is the method of choice when all the alternatives are considered. Another factor not often understood is that intrusion of the lower molar (or inhibition of eruption) is a significant factor in holding the lower incisor upright as it is finished with the ideal arch

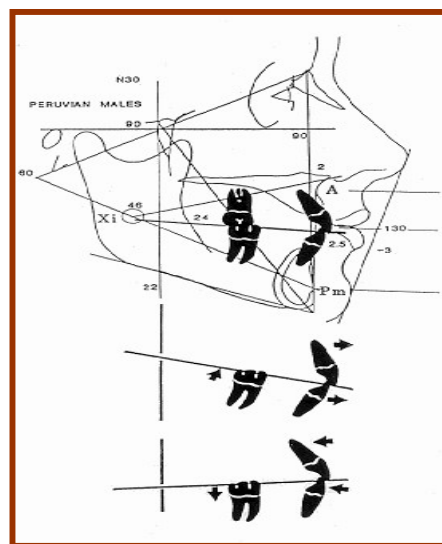


Fig. 9 Possible effects of lower molar height on final occlusion.

In Class II, division 2 cases, both the upper and lower incisors are at fault. In these deep bites, intrusion of both the upper and lower anterior segments is required to prevent excessive mandibular rotation.

The level of the upper incisor is an esthetic consideration related to lip length. The divine proportion is a standard in the relationship of the upper incisor to the lower. It should be brought in mind that the whole palate can be tipped, taking the lip and nose with it. The smile line, or the margin of the upper lip in the passive smile, should be approximately at the level of the gingival crest of the upper incisor segment. Complimentary nasolabial angles should also be a goal. All these factors must be taken into account in establishing techniques for the management of the lower incisor.

4. "There are good reasons for extracting second bicuspids rather than first bicuspids."

Ricketts commented that form and strength of the first premolar is a factor, but there are other reasons for upper second premolar extraction, such as sustaining space closure distal to the canine and management of the upper canines, which fit in the bifurcation of the roots of the upper first premolars. In 1993, many orthodontists consider a patient who once would have been a four-second-premolar extraction candidate now to be a nonextraction candidate. Slippage of anchorage is often required for second premolar extraction. Additionally, a choice can be made between premolar extraction and early removal of the third molars.

Extraction of the lower second premolar makes it necessary to contact the lower first premolar with the lower first molar, and the contact at the distal of the first premolar is rather narrow. The form of the first premolar is such that it frequently does not make good lingual

contact with the upper premolar. Therefore, the best choice he suggested was to extract upper second and lower first premolars and modify the mesiobuccal angle of the second toward the anatomy of the first premolar.

5. "Differential anchorage is nature's way of harmonizing the temporomandibular joint and the teeth."

The statement was made that in natural growth, the lower molars seldom move forward appreciably in relation to the symphysis. Such an interpretation of growth and eruption of the lower molar, as mentioned above, is entirely dependent upon the method of superpositioning. If the lower border of the mandible is used for reference, the impression is gained that the lower arch does sometimes move distally. As observed with implants, however in normal development the lower border of the mandible is resorbed as the angle drifts on an arc upward and backward. This shows that when the lower border of the mandible is employed as a reference, an erroneous impression might be gained with regard to mandibular development as well as to the eruption of the teeth. Two other references are much better for the display of lower arch development, the corpus axis and the arc method.

The beauty of the corpus axis is that it is based on Xi point and Pm and thus shows a remarkable tendency to stay level with the occlusal plane, which tends to move with Xi point. It is the best method found by Ricketts for accurately predicting occlusal plane behavior. Studies have shown that the lower molar tends to move at a right angle to the original corpus axis, upward and forward at about 0.5mm per year.

In truth, however, as shown with the discovery of the mandibular arc, the entire lower arch continues to move upward and forward as space is made posteriorly for the second and third molars by the forward drift and eruption of the lower arch. The lower molars offer more limited resistance to forward movement unless the roots are torqued buccally and the arch is slightly expanded in an attempt to lock them underneath the buccal cortical plate. The upper molars move forward more easily, particularly because the main resistance is toward the palatal root.

6, "The most important part of orthodontic treatment is the management of the six upper anterior teeth."

Ricketts mentioned that proper angulations and torquing are difficult to achieve without numerous archwire changes. He had prescribed three different bracket formulas, called a "trimorphic formulation", that account for the original malocclusion, the facial type, and the growth pattern.

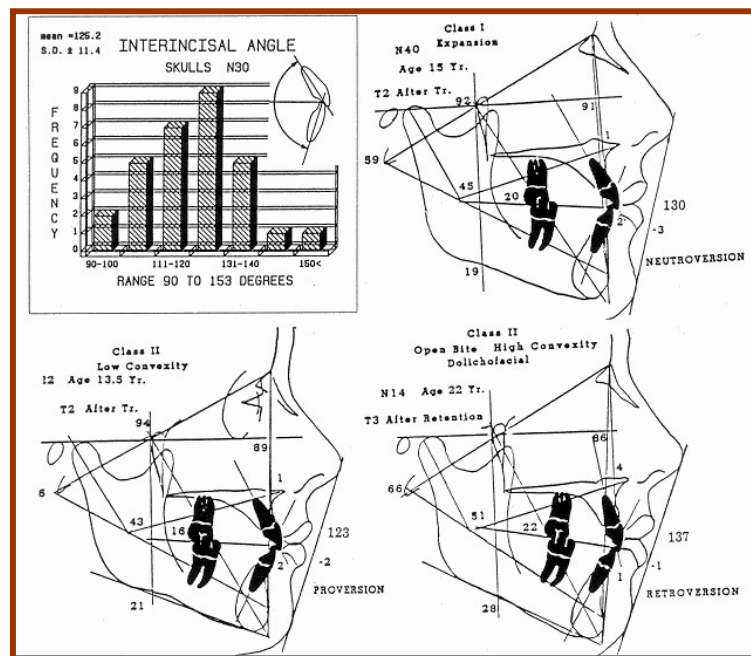


Fig. 10. *Distribution of interincisal angles as related to "trimorphic" bracket formulation.*

Patients with interincisal angles of 120° - 125° , with a tendency for uprighting, are treated as the "proversion" type. Those with interincisal angles of around 130° use the "neutroversion" formula. The "retroversion" formula is for long faces and Class III conditions, with interincisal angles in the range of 135° .

With these formulations, frequently only two or three archwires are needed. In a Class II, division 2 case with retruded upper incisors, an upside-down loop is placed mesial to the canine so that in retraction, the action will be dispersed among the roots rather than expressed in lingual tipping of the crowns.

VIEWS OF DR. ROBERT M. RICKETT'S ON BIOPROGRESSIVE CONCEPTS

In JIOS interview of Dr. Robert M. Ricketts in August 1993 and Interviewed by Dr M.K. Prakash, Dr V. P. Jayade, Dr Sumukh Deodhar and Dr K .M. Mistry.

- Views on Edgewise bracket designed to control teeth.

Any bracket should have five functions:

1. The first is that through a wire it will control the height. This is the reason for accuracy in bracket placement.
2. Control of angulation (mesiodistally). The Edgewise, winning over the Ribbon bracket was due to vertical slot's weakness. The vertical and angulation control was difficult and often needed an auxiliary spring.
3. The third function of the bracket is "Torque". This is buccolingual or labiolingual long axis control.
4. The fourth function is first order movement or lateral control. Due to tooth width differences, the arch wire was stepped outward for the canines, premolars and molars. By raising the base of the bracket step bends were eliminated.
5. The fifth need for performance in a bracket is "rotation" this was an original Edgewise weakness. Satisfaction of this weakness was done by designing two brackets, or a "Siamese" bracket with two brackets connected. The present edgewise bracket satisfies all these requirements and with its use with a 0.018" x 0.030" slot for lighter pressure and horizontal entry for a wire.

- Bypass wire or utility wire:

The utility wire was a result of attempting to sustain molar anchorage in extraction cases. He tried to use the lower incisors to prevent forward movements of the lower molars during sectional mechanics while retracting lower canines. It was in 1960 he started using it in day to day orthodontics regularly.

The name utility was given by assistance in his office Marty Lewis, in 1962 that derived the name from the baseball game.

He stated about design modification of utility arch wire and used the standard state utility and custom utility with loops or accessories. He further stated that when it is spanned from the molar to the incisor in the lower arch, the wire is subjected to food during chewing. In order to avoid distortion from function, the wire was offset to the gingival area or to the vestibular area. But, another advantage was that it provided more wire, made the force lighter and also formed an open loop. If a 'Z' or 'S' bend was made in standard utility it could be straightened out for arch length increase and can also be employed for closing spaces. In very crowded conditions, it is formed by loops between the incisors with rest against the lower lip and acts as a bumper, to move molars distally.

The vestibular section of utility arch acts as a shield against the pursing of the lips during swallowing. Hence, the lateral movement of three molars occurs without direct force on that. Also, the premolar drifts distally. They tend to flow into the area of least resistance.

- Flexibility of utility arch wire:

He stated that flexibility together with three plane control and lighter forces were needed. The bands could be activated directly in the mouth easily with the new plier (i360) designed in 1992. Excellent control in three dimensions is provided with the light square wire if it is understood and mastered.

- Torque in the lower anterior segment of utility wire:

Straight wire and a straight bracket will place the lower incisor 16° forward, which is about ideal so there is no need for incorporating torque. One factor more critical was the height of molar control of the occlusal plane. He preferred the occlusal plane to remain below Xi point. This holds the incisors upright. The more canted the plane, the more protrusive the incisor. This is another reason for cervical traction on upper molars to hold the plane forward posteriorly.

If the lower incisor were inclined forward to much, the straight bracket will upright it and vice versa. Ironically while intrusion occurs the lower incisors with the utility wire are often uprighted too much and we must keep opening up buccal space. The molars distalize and tend to take the incisors lingually while intrusion occurs.

- Metapositioning:

Ricketts mentioned that a favourable change in the position of the teeth following treatment is metapositioning. This 'Settling in' process is now metapositioning, it is not relapse.

AWARDS RECEIVED BY DR RICKETTS

1. William Gogswell Distinguished Service Award in Oral Surgery,
1974
2. Recipient of Albert H. Ketcham Award for American Association of
Orthodontist, 1975
3. John Mershon Lecture, 1976
4. Associated Journals of Europe Award, 1983 - Hinman Award

HONORS RECEIVED BY DR RICKETTS

1. Chairman of Orthodontic Section, American Dental Association, 1952
2. President of Western District Dental Society, 1956
3. Associate Editor of California Society State Dental Association, 1958-62
4. Chairman Research & Education for Pacific Coast Society of Orthodontists and Southern California State Dental Association, 1963-66
5. Consultant to the Cleft Palate Program at St. Johns Hospital, Veteran's Administration Hospital,
6. Chairman, Foundation for Orthodontic research 1967
7. Professor of Occlusion, University of Southern California School of Dentistry
8. Professor of Orthodontics, Loma Linda University School of Dentistry, 1971-present.
9. Visiting Clinical Professor, University of Texas, Houston, 1976

Dr. Robert Ricketts has devoted his professional life to lecturing, teaching and practicing orthodontics for over 45 years. He is the cofounder of Bioprogressive therapy and has been a major force in the development of computer aided diagnosis. He has developed a variety of orthodontic products that are used throughout the world. He has published many articles as well as Provocations and Perceptions in Cranio-Facial Orthopedics. He is an active part of the Orthodontic Education process at University of California at Los Angeles, Loma Linda University, University of Texas, University of Oklahoma and University of Southern California. The

University of Illinois and Loma Linda University [ias set aside research Libraries in recognition of Dr. Ricketts. He is the founder of the American Institute of Bioprogressive Education and was instrumental in establishing the Foundation for Orthodontic Research.

LECTURE, COURSES CONDUCTED BY DR RICKETTS

1. Practice Management, Introduction to bioprogressive therapy and Mechanics
2. Anatomy, Bones, Vertebrae, Cranium Introduction to Cephalometrics
3. Anatomy Mandibular Complex, Analysis Frontal/Lateral Tracing
4. Anatomy Maxillary Complex, Growth & Forecast Analysis
5. Physiology, Divine Proportion, Physiology Functional Environment
6. Mechanics Activation Mechanism, Fixed Ricketts Formula
7. Mechanics, Headgear & Quad Helix, Utility arch, Sectional Mechanics
8. Occlusion and Finishing Straight Wire - Retention, TMJ in Orthodontics
9. Cephalometric analysis including treatment planning forecast (short and long term)
10. Growth prediction - Diagnosis and treatment planning with emphasis on early treatment and interceptive orthodontics
11. Bioprogressive philosophy and differences between various straight wire appliances
12. Bioprogressive mechanics with the five principals
 1. Extraoral therapy the utilization of headgear as orthodontic/orthopedic appliances
 2. Quad helix mechanics
 3. Utility arch technique
 4. Segmented mechanics
 5. Ricketts straight wire appliance

BIBLIOGRAPHY

1. Ricketts, R. M. Various Conditions of the Temporomandibular Joint as Revealed by Cephalometric Laminagraphy. Angle Orthodont. 22:98-115, 1952.
2. Ricketts, R. M. The Functional Diagnosis Of Malocclusion. Trans. Europ. Orthodont. Soc. Pp. 1-21, 1958a.
3. Ricketts R.M: A Foundation for Cephalometric Communication, Amj. J. Orthodontics - 46: 330- 357, 1960.
4. Ricketts, R. M. Clinical Research in Orthodontics. In.: Vistas In Orthodontics, B. S. Kraus And R. A. Riedel (Eds.), Lea And Febiger, Philadelphia, 1962.
5. Sloan, R., R. Bench, J. Mulick, R. Ricketts, S. Brummet and J. Westover. The Application of Cephalometrics to Cinefluorography: Comparative Analysis of Hyoid Movement Patterns during Deglutition in Class I and Class II Orthodontic Patients. Angle Orthodont. 37:26-34. 1967.
6. Ricketts R. M. Respiratory Obstruction Syndrome. Amj. Orthodontics. 54:485-514, 1968.
7. Ricketts, R. M. Esthetics, Environment and The Law of Lip Relation. Amj. Orthodontics. 54:272-289, 1968.
8. Ricketts, R. M. Introducing Computerized Cephalometrics. Rocky Mt. Corp. Denver, 1969

9. Ricketts R.M: The Discovery of Racial Growth of Mandible, Proc. Found. Orthodontics. Res. 1971, Pp 31-52.
10. Ricketts, R. M, M. R. Bench, Hilgers and R. Schulhof. An Overview of Computerized Cephalometrics. Amj. Orthodont. 61:1-28, 1972.
11. Ricketts R.M: The Value of Cephalometrics and Computerized Technology, Angle Orthodontics, 42: 179-199, 1972.
12. Ricketts R.M: An Overview of Computerized Cephalometrics Amj. Orthodontics, 61: 1-28, 1972.
13. Ricketts, R. M. New Perspectives on Orientation and their Benefits to Clinical Orthodontics - Part I. Angle Orthodont. 45:4, 1975.
14. Ricketts R.M: A Four Step Method to Distinguish Orthodontic Changes from Natural Growth, Jco, 9: 208- 228, 1975.
15. Ricketts R.M: Jco Interview Of Dr Robert Ricketts on Growth Prediction Jco 9: 420, 1975.
16. Ricketts, R. M. New Perspectives on Orientation and Their Benefits to Clinical Orthodontics -- Part II. Angle Orthodont. 46:1, 1976.
17. Ricketts R.M: Bioprogressive Therapy as an Answer to Orthodontic Needs, Amj Orthodontics, 70: 241-268, 359-397, and 1976.
18. Bioprogressive Therapy: R .M. Ricketts, Ruel W. Bench, Carl F Gugino, James Hilgers, Robert Schulhof Rocky Mountain Orthodontics 1979.

19. Rickets R.M: Perspectives in Clinical Application of Cephalometrics, Angle Orthodontics. 51: 115- 150, 1981.
20. Rickets R.M Et Al: Orthodontic Diagnosis and Planning. Rocky Mountain Orthodontics Denver, 1982.
21. Rickets R.M: The Biologic Significance of Devine Proportion and Fabonacci Series, Amj Orthodontics 81: 351-370, 1982.
22. Editorial Response " Truth In Orthodontic Belief " Robert Ricketts JcoNov 1993
23. Robert Ricketts on Bioprogressive Therapy, JIOS Aug 1993.